

## CLINICAL PRACTICE GUIDELINE DOCUMENT

# Editor's Choice – European Society for Vascular Surgery (ESVS) 2022 Clinical Practice Guidelines on the Management of Chronic Venous Disease of the Lower Limbs<sup>☆</sup>

Marianne G. De Maeseneer<sup>\*,a</sup>, Stavros K. Kakkos<sup>a</sup>, Thomas Aherne<sup>a</sup>, Niels Baekgaard<sup>a</sup>, Stephen Black<sup>a</sup>, Lena Blomgren<sup>a</sup>, Athanasios Giannoukas<sup>a</sup>, Manjit Gohel<sup>a</sup>, Rick de Graaf<sup>a</sup>, Claudine Hamel-Desnos<sup>a</sup>, Arkadiusz Jawien<sup>a</sup>, Aleksandra Jaworucka-Kaczorowska<sup>a</sup>, Christopher R. Lattimer<sup>a</sup>, Giovanni Mosti<sup>a</sup>, Thomas Noppeney<sup>a</sup>, Marie Josee van Rijn<sup>a</sup>, Gerry Stansby<sup>a</sup>

ESVS Guidelines Committee<sup>b</sup>, Philippe Kolh, Frederico Bastos Goncalves, Nabil Chakfé, Raphael Coscas, Gert J. de Borst, Nuno V. Dias, Robert J. Hinchliffe, Igor B. Koncar, Jes S. Lindholt, Santi Trimarchi, Riikka Tulamo, Christopher P. Twine, Frank Vermassen, Anders Wanhainen

Document Reviewers<sup>c</sup>, Martin Björck, Nicos Labropoulos, Fedor Lurie, Armando Mansilha, Isaac K. Nyamekye, Marta Ramirez Ortega, Jorge H. Ulloa, Tomasz Urbanek, Andre M. van Rij, Marc E. Vuylsteke

## TABLE OF CONTENTS

Abbreviations and acronyms	187
What is new in the 2022 guidelines, compared with the 2015 guidelines	188
Introduction	189
<i>Purpose of these guidelines</i>	189
<i>Methodology</i>	189
Guideline Writing Committee	189
Workflow for producing the guidelines	189
Literature search	189
Evidence and Recommendations criteria	190
Tables of Evidence	191
The revision process and update of guidelines	191
The patient perspective	191
<i>Areas not covered by these guidelines</i>	192
1. General considerations	192
1.1. Epidemiology	193
1.2. Anatomy	194
1.2.1. The superficial and perforating veins of the lower limb	194
1.2.2. The deep veins of the lower limb	195
1.2.3. Small veins and the microvenous circulation	195
1.3. Pathophysiology	195
1.4. Clinical presentation	195
1.4.1. Symptoms	195
1.4.2. Signs	196
1.4.3. Acute complications	196
1.5. Scoring systems	196
1.5.1. Clinical scoring systems	196
1.5.2. Patient reported outcome measures	197
2. Investigations	197

<sup>☆</sup> For a full list of the authors' affiliations, please refer to [Appendix B](#).

<sup>a</sup> **Writing Committee:** Marianne G. De Maeseneer (Chair)\* (Rotterdam, The Netherlands), Stavros K. Kakkos (Co-Chair) (Patras, Greece), Thomas Aherne (Galway, Ireland), Niels Baekgaard (Copenhagen, Denmark), Stephen Black (London, United Kingdom), Lena Blomgren (Örebro, Sweden), Athanasios Giannoukas (Larissa, Greece), Manjit Gohel (London, United Kingdom), Rick de Graaf (Friedrichshafen, Germany), Claudine Hamel-Desnos (Caen, France), Arkadiusz Jawien (Torun, Poland), Aleksandra Jaworucka-Kaczorowska (Gorzów, Poland), Christopher R. Lattimer (London, United Kingdom), Giovanni Mosti (Lucca, Italy), Thomas Noppeney (Regensburg, Germany), Marie Josee van Rijn (Rotterdam, The Netherlands), Gerry Stansby (Newcastle upon Tyne, United Kingdom)

<sup>b</sup> **ESVS Guidelines Committee:** Philippe Kolh (Chair, Review Coordinator) (Liège, Belgium), Frederico Bastos Goncalves (Lisboa, Portugal), Nabil Chakfé (Strasbourg, France), Raphael Coscas (Boulogne-Billancourt, France), Gert J. de Borst (Utrecht, The Netherlands), Nuno V. Dias (Malmö, Sweden), Robert J. Hinchliffe (Bristol, United Kingdom), Igor B. Koncar (Belgrade, Serbia), Jes S. Lindholt (Odense, Denmark), Santi Trimarchi (Milan, Italy), Riikka Tulamo (Helsinki, Finland), Christopher P. Twine (Bristol, United Kingdom), Frank Vermassen (Ghent, Belgium), Anders Wanhainen (Uppsala and Umeå, Sweden).

<sup>c</sup> **Document Reviewers:** Martin Björck (Uppsala, Sweden and Tartu, Estonia), Nicos Labropoulos (Stony Brook, NY, USA), Fedor Lurie (Toledo, OH, USA), Armando Mansilha (Porto, Portugal), Isaac K. Nyamekye (Worcester, United Kingdom), Marta Ramirez Ortega (Madrid, Spain), Jorge Ulloa (Bogota, Colombia), Tomasz Urbanek (Katowice, Poland), Andre van Rij (Dunedin, New Zealand), Marc Vuylsteke (Tiel, Belgium).

\* Corresponding author.

E-mail address: [mdmaesen@gmail.com](mailto:mdmaesen@gmail.com) (Marianne G. De Maeseneer).

1078-5884/© 2021 The Author(s). Published by Elsevier B.V. on behalf of European Society for Vascular Surgery. This is an open access article under the CC BY license (<http://creativecommons.org/licenses/by/4.0/>).

<https://doi.org/10.1016/j.ejvs.2021.12.024>

2.1.	<i>Clinical examination</i>	197
2.2.	<i>Handheld continuous wave Doppler</i>	198
2.3.	<i>Duplex ultrasound</i>	198
2.3.1.	Duplex ultrasound of the lower limbs	198
2.3.1.1.	<i>Varicose veins (first presentation)</i>	198
2.3.1.2.	<i>Recurrent varicose veins</i>	198
2.3.2.	Abdominal ultrasound	198
2.4.	<i>Cross sectional imaging</i>	198
2.4.1.	Magnetic resonance venography	199
2.4.2.	Computed tomography venography	199
2.5.	<i>Endovenous imaging</i>	199
2.5.1.	Venography	199
2.5.2.	Intravascular ultrasound	199
2.6.	<i>Plethysmography</i>	199
2.7.	<i>Diagnostic strategy</i>	200
<b>3.</b>	<b>Conservative management</b>	200
3.1.	<i>Physical methods</i>	200
3.2.	<i>Compression</i>	201
3.2.1.	Elastic compression stockings, adjustable compression garments, and inelastic bandages	202
3.2.1.1.	<i>Evidence</i>	202
3.2.1.2.	<i>Compliance</i>	202
3.2.1.3.	<i>Contraindications to compression treatment</i>	202
3.2.2.	Other compression methods	203
3.2.2.1.	<i>Intermittent pneumatic compression</i>	203
3.2.2.2.	<i>Neuromuscular electrical stimulation</i>	203
3.2.2.3.	<i>Tension free compression</i>	203
3.3.	<i>Pharmacological treatment</i>	204
3.3.1.	Ruscus extracts	204
3.3.2.	Micronised purified flavonoid fraction	204
3.3.3.	Calcium dobesilate	204
3.3.4.	Horse chestnut extract	204
3.3.5.	Hydroxyethylrutosides	204
3.3.6.	Red vine leaf extract	204
3.3.7.	Sulodexide	204
3.3.8.	Clinical applicability	205
3.4.	<i>Conservative treatment strategy</i>	205
<b>4.</b>	<b>Interventions for superficial venous incompetence</b>	205
4.1.	<i>General principles</i>	205
4.1.1.	Indications for treatment	205
4.1.2.	Setting	207
4.1.3.	Anaesthesia	207
4.1.4.	Cannulation and other technical considerations	208
4.1.5.	Compression after treatment	208
4.1.6.	Thromboprophylaxis	209
4.1.7.	Surveillance	209
4.1.8.	Safety and environmental sustainability issues	209
4.2.	<i>Techniques for saphenous ablation</i>	210
4.2.1.	Thermal ablation	210
4.2.1.1.	<i>General considerations</i>	210
4.2.1.2.	<i>Endovenous laser ablation</i>	210
4.2.1.3.	<i>Radiofrequency ablation</i>	210
4.2.1.4.	<i>Other thermal ablation techniques</i>	211
4.2.1.5.	<i>Complications of endovenous thermal ablation</i>	211
4.2.1.6.	<i>Duplex ultrasound and clinical long term follow up</i>	211
4.2.1.7.	<i>Quality of life</i>	212
4.2.1.8.	<i>Choosing a thermal ablation device</i>	212
4.2.2.	Non-thermal ablation	212
4.2.2.1.	<i>Cyanoacrylate glue ablation</i>	212
4.2.2.2.	<i>Foam sclerotherapy</i>	212
4.2.2.3.	<i>Mechanochemical ablation</i>	213
4.2.3.	High ligation and stripping	214
4.3.	<i>Techniques for the treatment of tributaries</i>	215
4.3.1.	Phlebectomies	215
4.3.2.	Sclerotherapy of tributaries	215
4.3.3.	Other techniques for varicose tributary treatment	216
4.4.	<i>Techniques for treating perforating veins</i>	216
4.4.1.	Perforating vein ligation	216
4.4.2.	Perforating vein ablation	216
4.4.3.	Other techniques	217
4.5.	<i>Techniques for treatment of reticular veins and telangiectasias</i>	217
4.5.1.	Sclerotherapy	217

4.5.2.	Transcutaneous lasers and intense pulse light sources	218
4.5.3.	Hybrid techniques	219
4.6.	<i>Interventional treatment strategy for superficial venous incompetence</i>	219
4.6.1.	Great saphenous vein incompetence	219
4.6.2.	Small saphenous vein incompetence	220
4.6.3.	Anterior accessory saphenous vein incompetence	221
4.6.4.	Concomitant versus delayed phlebectomies/sclerotherapy	222
4.6.5.	Incompetence of other superficial veins	222
4.6.5.1.	<i>Giacomini vein</i>	223
4.6.5.2.	<i>Posterior accessory saphenous vein</i>	223
4.6.5.3.	<i>Straight tributary vein</i>	223
4.6.6.	Perforating vein incompetence	223
4.6.7.	Preservation of the saphenous trunk	223
4.6.7.1.	<i>CHIVA</i>	223
4.6.7.2.	<i>Isolated ambulatory phlebectomies or ASVAL</i>	224
4.6.8.	Special anatomical considerations	224
4.6.8.1.	<i>Very large saphenous trunks</i>	224
4.6.8.2.	<i>Very superficial saphenous trunks</i>	225
4.6.8.3.	<i>Saphenous trunks with intraluminal changes</i>	225
4.6.8.4.	<i>Saphenous trunk aneurysms</i>	225
4.6.8.5.	<i>Foot and ankle veins</i>	225
4.6.8.6.	<i>Unusual varicose vein locations</i>	225
4.7.	<i>Recurrent varicose veins</i>	225
4.7.1.	Aetiology and risk factors	226
4.7.1.1.	<i>Causes of recurrent varicose veins</i>	226
4.7.1.2.	<i>Risk factors</i>	226
4.7.2.	Prevention	226
4.7.3.	Treatment	227
5.	<b>Interventions for deep venous pathology</b>	227
5.1.	<i>Post-thrombotic syndrome</i>	228
5.2.	<i>General principles</i>	228
5.2.1.	Specialised care	228
5.2.2.	Anaesthesia	228
5.2.3.	Compression after treatment	228
5.3.	<i>Treatment of chronic deep venous obstruction</i>	228
5.3.1.	Indications for treatment	228
5.3.2.	Iliocaval and iliofemoral obstruction	228
5.3.2.1.	<i>Technical considerations of recanalisation and stenting</i>	228
5.3.2.2.	<i>Post-operative surveillance</i>	229
5.3.2.3.	<i>Outcome of recanalisation and stenting</i>	229
5.3.2.4.	<i>Indications for re-intervention after stenting</i>	229
5.3.2.5.	<i>Options for re-intervention after stenting</i>	230
5.3.2.6.	<i>Surgical reconstruction</i>	230
5.3.2.7.	<i>Hybrid procedures</i>	230
5.3.3.	Femoropopliteal obstruction	231
5.3.3.1.	<i>Endovenous recanalisation</i>	231
5.3.3.2.	<i>Surgical reconstruction</i>	231
5.3.4.	Antithrombotic treatment	231
5.3.5.	Safety issues	231
5.3.6.	Multidisciplinary team	231
5.4.	<i>Treatment of deep venous incompetence of the lower limbs</i>	232
5.5.	<i>Combined superficial and deep venous pathology</i>	232
5.6.	<i>Aneurysms of the deep veins</i>	233
5.7.	<i>Popliteal venous entrapment</i>	233
5.8.	<i>Interventional treatment strategy for deep venous pathology</i>	233
6.	<b>Management of venous ulceration</b>	235
6.1.	<i>General principles</i>	235
6.1.1.	Specialist care	235
6.1.2.	Pain control	235
6.1.3.	Antibiotics and antiseptics	235
6.1.4.	Mobilisation and physical therapy	236
6.1.5.	Comorbidities	236
6.2.	<i>Wound care</i>	236
6.2.1.	Debridement	236
6.2.2.	Dressings and topical agents	236
6.2.3.	Other wound therapies	237
6.2.3.1.	<i>Therapeutic ultrasound</i>	237
6.2.3.2.	<i>Electromagnetic therapy</i>	237
6.2.3.3.	<i>Negative pressure wound therapy</i>	237
6.3.	<i>Compression</i>	237
6.3.1.	Compression materials	237

6.3.2.	Haemodynamic and clinical effects in patients with venous leg ulceration	237
6.3.3.	Treatment of mixed venous and arterial ulcers	237
6.3.4.	Prevention of ulcer recurrence	238
6.4.	Treatment of superficial venous incompetence	238
6.4.1.	Rationale for superficial venous interventions in venous ulceration	238
6.4.2.	Timing of interventions	239
6.4.3.	Choice of superficial venous intervention	239
6.4.4.	Treatment of the sub-ulcer venous plexus	239
6.5.	Treatment of deep venous pathology	240
6.6.	Pharmacotherapy	241
6.7.	Management strategy for patients with venous leg ulceration	241
7.	Management of pelvic venous disorders causing varicose veins	241
7.1.	General principles and classification	241
7.1.1.	Primary sources of incompetence	241
7.1.2.	Associated pathologies	242
7.2.	Clinical presentation and investigations	243
7.2.1.	Clinical presentation	243
7.2.2.	Investigations	243
7.2.2.1.	Transvaginal ultrasound	243
7.2.2.2.	Abdominal duplex ultrasound	244
7.2.2.3.	Selective venography and cross sectional imaging	244
7.3.	Treatment	244
7.3.1.	Varicose veins of pelvic origin without pelvic symptoms	244
7.3.2.	Varicose veins of pelvic origin with pelvic symptoms	245
7.3.3.	Other treatment options	245
7.4.	Management strategy for pelvic venous disorders causing varicose veins	245
8.	Special considerations	246
8.1.	Management of acute complications	246
8.1.1.	Superficial vein thrombosis	246
8.1.2.	Haemorrhage	246
8.2.	Special patient characteristics	247
8.2.1.	Obesity	247
8.2.2.	Pregnancy	247
8.2.3.	Patients on anticoagulants	247
8.2.4.	Elderly patients and patients with comorbidities	248
8.2.5.	Children with chronic venous disease	248
9.	Gaps in evidence and future perspectives	248
9.1.	Understanding the natural history of chronic venous disease	248
9.2.	Diagnostic work up in patients with chronic venous disease	248
9.3.	Conservative treatment of chronic venous disease	249
9.4.	Treatment of superficial venous incompetence	249
9.5.	Treatment of deep venous obstruction	249
9.6.	Management of venous leg ulcer	249
9.7.	Treatment of varicose veins related to pelvic vein incompetence	249
9.8.	Improving future clinical practice guidelines on the management of chronic venous disease	249
10.	Information for patients	249
10.1.	What is chronic venous disease of the legs?	250
10.2.	Why does chronic venous disease occur?	250
10.3.	Which veins can be affected by chronic venous disease?	250
10.4.	What are the symptoms and signs of chronic venous disease?	250
10.5.	What are the acute complications of chronic venous disease?	250
10.6.	How is chronic venous disease diagnosed?	251
10.7.	What are the principles of treatment for chronic venous disease?	251
10.8.	Which conservative measures are available if I suffer from chronic venous disease?	251
10.9.	How can I be treated for varicose veins and related superficial venous disease?	251
10.10.	How can I be treated for visible small veins, which make my legs look ugly?	252
10.11.	What is the best treatment if my deep veins do not allow the normal passage of blood from my legs to the heart?	252
10.12.	Are there any useful interventions if I have a venous leg ulcer?	252
10.13.	What are the main areas that need further research?	252
10.14.	How was this information developed and what do I need to know before reading the full document?	252
	Acknowledgements	252
	Supplementary data	253
	References	253

## ABBREVIATIONS AND ACRONYMS

AASV	anterior accessory saphenous vein
ABI	ankle brachial index
ACG	adjustable compression garments
AP	ambulatory phlebectomy

ASVAL	Ambulatory Selective Varicose vein Ablation under Local anaesthesia
AVVQ	Aberdeen Varicose Vein Questionnaire
AVF	arteriovenous fistula
BMI	body mass index
CAC	cyanoacrylate adhesive closure

CEAP	Clinical Etiological Anatomical Pathophysiological (classification)	IVUS	intravascular ultrasound
CDFS	catheter directed foam sclerotherapy	KTP	potassium titanyl phosphate (laser)
CFV	common femoral vein	LMWH	low molecular weight heparin
CHIVA	ambulatory conservative haemodynamic treatment of venous incompetence in outpatients (= French acronym for 'Cure Hémodynamique de l'Insuffisance Veineuse en Ambulatoire')	MOCA	mechanochemical ablation
CI	confidence interval	MPPF	micronised purified flavonoid fraction
CIV	common iliac vein	MR	magnetic resonance
CIVIQ	chronic Venous Insufficiency Questionnaire	MRV	magnetic resonance venography
CLaCS	cryolaser and cryosclerotherapy guided by augmented reality	NIVL	non-thrombotic iliac vein lesion
CPP	chronic pelvic pain	OR	odds ratio
CT	computed tomography	PASV	posterior accessory saphenous vein
CTV	computed tomography venography	PDL	pulsed dye laser
CVD	chronic venous disease	PE	pulmonary embolism
CVI	chronic venous insufficiency	PeVD	pelvic venous disorders
DFV	deep femoral vein	POL	polidocanol
DOAC	direct oral anticoagulant	POPV	popliteal vein
DUS	duplex ultrasound	PREVAIT	PResence of Varices After Interventional Treatment
DVI	deep vein incompetence	PROMs	patient reported outcome measures
DVT	deep vein thrombosis	PTS	post-thrombotic syndrome
eASVAL	endovenous Ambulatory Selective Varicose vein Ablation under Local anaesthesia	PV	perforating vein
ECS	elastic compression stockings	PVI	pelvic vein incompetence
EHIT	endothermal heat induced thrombosis	QoL	quality of life
EIV	external iliac vein	RCT	randomised controlled trial
EMLA	eutectic mixture of local anaesthesia	REVAS	recurrent varicose veins after surgery
EMT	electromagnetic therapy	RFA	radiofrequency ablation
ESC	European Society of Cardiology	RFITT	radiofrequency induced thermal therapy
ESVS	European Society for Vascular Surgery	r-VCSS	revised venous clinical severity score
ESCHAR (trial)	Effect of Surgery and Compression on Healing And Recurrence	SEPS	subfascial endoscopic perforator surgery
EVLA	endovenous laser ablation	SFJ	saphenofemoral junction
EVMA	endovenous microwave ablation	SF-36	Short Form 36
EVRA (trial)	Early Venous Reflux Ablation	SPJ	saphenopopliteal junction
EVSA	endovenous steam ablation	SSI	static stiffness index
EVTA	endovenous thermal ablation	SSV	small saphenous vein
fEVLA	flush endovenous laser ablation	STS	sodium tetradecyl sulphate
FV	femoral vein	SVT	superficial vein thrombosis
GSV	great saphenous vein	TCL	transcutaneous laser
GWC	Guideline Writing Committee	TVUS	transvaginal ultrasound
HLS	high ligation and stripping	UGFS	ultrasound guided foam sclerotherapy
IB	inelastic bandages	UFH	unfractionated heparin
IU	international units	VA	venous aneurysm
IIV	internal iliac vein	VAD	venoactive drug
IPC	intermittent pneumatic compression	VAS	visual analogue scale
IVC	inferior vena cava	VAS	venous clinical severity score
		VCSS	venous clinical severity score
		VEINES-QOL/Sym	VENous INSufficiency Epidemiological and Economic Study Quality of Life/symptoms
		VTE	venous thromboembolism
		VLU	venous leg ulcer
		VV	varicose vein

### WHAT IS NEW IN THE 2022 GUIDELINES, COMPARED WITH THE 2015 GUIDELINES?

Compared with the 2015 version of the guidelines on the management of chronic venous disease (CVD),<sup>1</sup> the global structure of the document has been modified considerably in an attempt to make it more practical and user friendly. Special

subsections on management strategy with accompanying flowcharts have been added to the different chapters.

- An extensive chapter has been entirely dedicated to superficial venous incompetence. A new subsection on evidence supporting endovenous non-thermal ablation has been included. A new subsection on incompetence

of perforating veins has been added, as well as a subsection on practical strategies for special anatomical presentations. The management of recurrent varicose veins is discussed at the end of this chapter.

- Deep venous pathology is discussed in a separate chapter, with an emphasis on the increasing evidence in the field of managing iliofemoral and ilio caval obstruction. In addition, new topics in this chapter are the combination of superficial and deep venous problems, aneurysms of the deep veins and popliteal vein entrapment syndrome.
- An entirely new chapter has been dedicated to the management of patients with venous leg ulcers.
- A new chapter describes the management of patients with varicose veins, related to underlying pelvic venous disorders.
- A new chapter considers special patient characteristics and their potential influence on management strategy.
- Gaps in evidence and future perspectives are briefly discussed in a separate chapter.
- A lay summary of the guidelines provides useful information for patients.

In view of the new chapters and subsections, many new recommendations have been added, briefly summarised in [Fig. 1](#). Compared with the 2015 CVD guidelines, five recommendations have also been upgraded, while another three have been downgraded ([Fig. 2](#)).

## INTRODUCTION

### *Purpose of these guidelines*

The European Society for Vascular Surgery (ESVS) has prepared new guidelines for the treatment of patients with CVD, to update the existing ESVS guidelines on the management of CVD, which were published in 2015.<sup>1</sup> The focus of the present guidelines is on CVD of the lower limbs, related to pathology of the superficial, perforating and deep veins of the lower limbs as well as to abdominal and pelvic venous pathology. The guidelines report several recommendations on diagnosis and treatment of these pathologies in different chapters, with details on health questions and population described in the related text. These guidelines do not include patients with venous pathologies unrelated to CVD of the lower limbs nor patients suffering from venous or arteriovenous malformations. These guidelines provide guidance for vascular and general surgeons, vascular physicians, interventional radiologists, phlebologists, dermatologists, and emergency medicine physicians. The guidelines promote high standards of care (based on evidence, whenever available), established by specialists in the field.

We wish to clarify that these guidelines are intended to support clinical decision making and that the recommendations may not be appropriate in all circumstances. The authors have created a clinical guideline and, as such, this reports only on treatment efficacy and clinical outcomes, not on costs, which may be very different from one country to another. In most healthcare systems, the question of management, whether to opt for conservative management or to intervene,

as well as when and with which technique to intervene in CVD patients, is heavily influenced by cost (and cost effectiveness). The decision to follow a recommendation from the guidelines must be made by the responsible practitioner on an individual patient basis, taking into account the specific condition of the patient as well as local resources, regulations, laws, and clinical practice recommendations. Deviation from the guidance for specific reasons is perfectly permissible and should not in itself be interpreted as negligence.

To further underline the supportive character of the guidelines, both European and non-European reviewers were invited to review the document, so that the document also can serve practitioners treating patients outside Europe. This is also the rationale behind the decision that all ESVS guidelines are free to download from the publisher's website and the ESVS website [www.esvs.org](http://www.esvs.org). In addition, an ESVS clinical guidelines App is available, where the guidelines can be found in easily readable form for use in everyday practice.

### *Methodology*

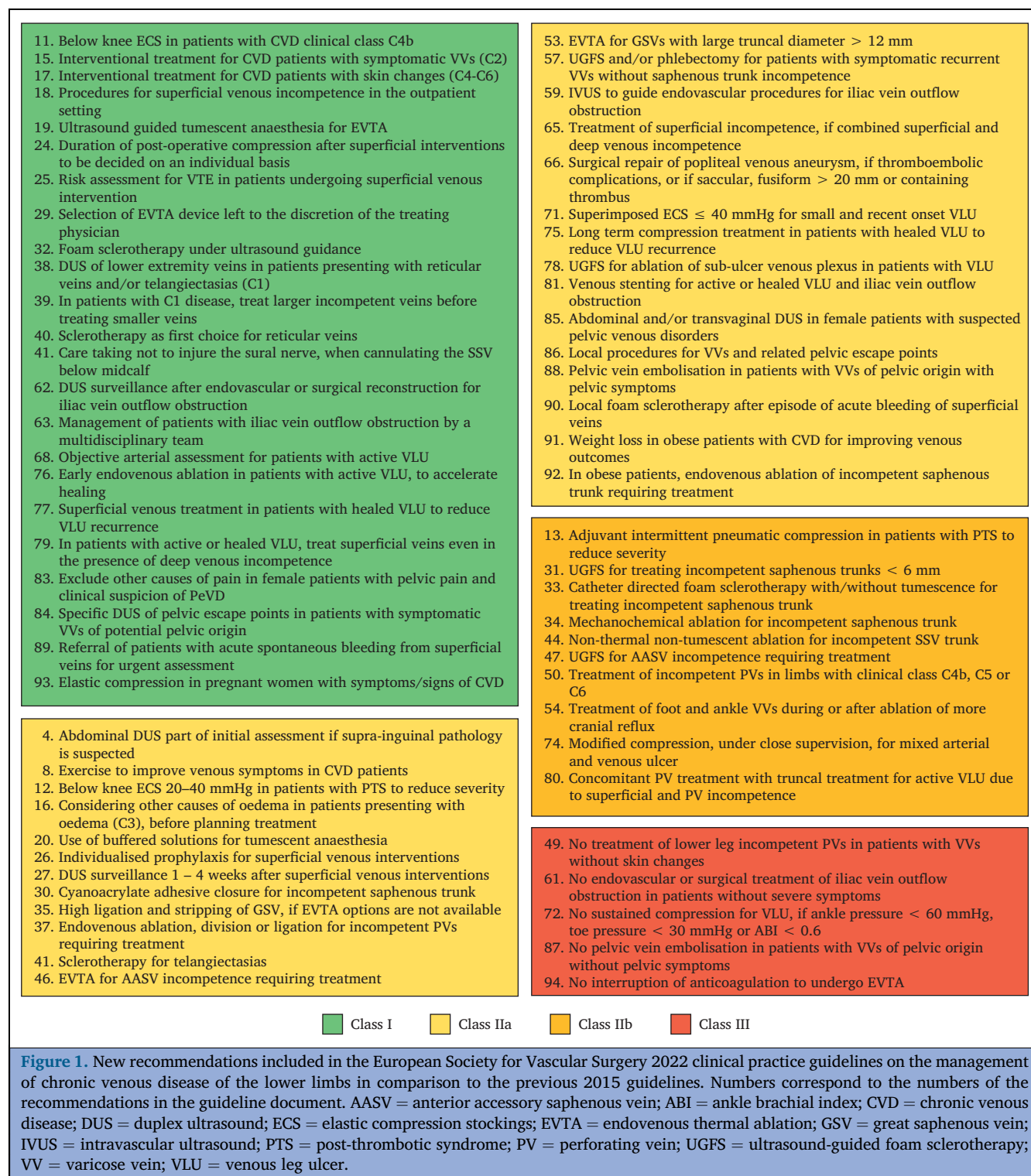**Guideline Writing Committee.** Members of the Guideline Writing Committee (GWC) were selected by the ESVS to represent clinicians involved in the treatment of CVD and included vascular surgeons, vascular physicians, an interventional radiologist, and a gynaecologist - obstetrician. All members of the GWC were involved in selecting and rating the evidence for each of the different chapters and subsections under their responsibility (see [Appendix](#) with Supplementary Table of topics, search terms, and responsible authors), as agreed in the introductory meeting. All GWC members were involved in formulating the final recommendations.

GWC members have provided disclosure statements regarding all relationships that might be perceived as real or potential sources of conflicts of interest. These are filed and available at the ESVS headquarters. GWC members received no financial support from any pharmaceutical, device, or surgical industry to develop these guidelines.

**Workflow for producing the guidelines.** The GWC held an introductory meeting in November 2019 in Amsterdam, Netherlands, at which the list of topics and author tasks were determined. Contributions from GWC members were compiled into a draft of the guidelines by the chair and co-chair. After the first draft was completed and internally reviewed, the GWC met again in September 2020 in Frankfurt, Germany, to review and approve the wording of each recommendation. The guidelines then underwent three rounds of external reviews, and appropriate revisions were implemented.

**Literature search.** GWC members agreed on a common systematic literature search strategy for each of the chapters. A comprehensive literature search of articles published was performed using MEDLINE (through PubMed), Embase, Cardoso Clinical Trials Database, and the Cochrane Library databases between 1 January 2013 and 30 June 2020, for relevant papers published in English. The search terms used for the different chapters and subsections are mentioned in the [Appendix \(Supplementary Table\)](#). Reference checking and





manual search by the GWC members added other relevant literature. Only peer reviewed, published literature and studies presenting pre-defined outcomes were considered. The selection process followed the “pyramid of evidence”, with aggregated evidence at the top of the pyramid (meta-analyses of several randomised controlled trials [RCTs], other meta-analyses, and systematic reviews), followed by RCTs and finally observational studies. Single case reports, abstracts, and *in vitro* studies were excluded, leaving expert opinion at the bottom of the pyramid. Articles published after the search

date or in another language were included only if they were of paramount importance to this guideline. After the first and second external review, the members of the GWC performed a second and third literature search within their area of responsibility to determine if any important publications had been published between July 2020 and February 2021, and further until the end of June 2021, respectively.

**Evidence and Recommendations criteria.** The European Society of Cardiology (ESC) system was used for grading

2015	Upgraded recommendations	2022
	36. Treatment of varicose tributaries by phlebectomies, foam sclerotherapy or both	
	42. Transcutaneous laser for treatment of telangiectasias	
	43. EVTA for treatment of SSV incompetence in preference to surgery and UGFS	
	60. Surgical or hybrid deep venous reconstructions in patients with iliac vein outflow obstruction, suffering from a recalcitrant VLU, severe PTS or disabling venous claudication	
	70. Multilayer or inelastic bandages or adjustable compression garments (≥ 40 mmHg ankle pressure) for patients with active VLU	
2015	Downgraded recommendations	2022
	22. Post-procedural compression after UGFS or EVTA of an incompetent saphenous trunk	
	21. Ultrasound guided tumescent anaesthesia for high ligation and stripping	
	52. Phlebectomies with preservation of the saphenous trunk (ASVAL) for uncomplicated varicose veins (C2)	

■ Class I   
 ■ Class IIa   
 ■ Class IIb   
 ■ Class III

**Figure 2.** Changes in class of recommendations included in the European Society for Vascular Surgery 2022 clinical practice guidelines on the management of chronic venous disease of the lower limbs in comparison to the previous 2015 guidelines. Numbers correspond to the numbers of the recommendations in the guideline document. ASVAL = Ambulatory Selective Varices Ablation under Local Anaesthesia; EVTA = endovenous thermal ablation; PTS = post-thrombotic syndrome; SSV = small saphenous vein; UGFS = ultrasound-guided foam sclerotherapy.

Table 1. Levels of evidence according to ESC (European Society of Cardiology)	
Level of evidence A	Data derived from multiple randomised clinical trials or meta-analyses
Level of evidence B	Data derived from a single randomised clinical trial or large non-randomised studies
Level of evidence C	Consensus of experts opinion and/or small studies, retrospective studies, and registries

Table 2. Classes of recommendations according to ESC (European Society of Cardiology)	
Class of recommendation	Definition
Class I	Evidence and/or general agreement that a given treatment or procedure is beneficial, useful and effective
Class II	Conflicting evidence and/or a divergence of opinion about the usefulness/efficacy of the given treatment or procedure
Class IIa	<i>Weight of evidence/opinion is in favour of usefulness/efficacy</i>
Class IIb	<i>Usefulness/efficacy is less well established by evidence/opinion</i>
Class III	Evidence or general agreement that the given treatment or procedure is not useful/effective, and in some cases may be harmful

evidence and recommendations. A, B, or C reflects the level of current evidence (Table 1) and the strength of each recommendation was then determined to be class I, IIa, IIb, or III (Table 2).

To formulate recommendations, the strengths and limitations of the available evidence were considered, as well as benefit versus harm and applicability to clinical practice context. Details of study methodology limitations, appropriateness of primary and secondary outcomes, and consistency of results across studies were discussed in the main text.

**Tables of Evidence.** The members of the GWC provided summaries of the selected articles, used to support the evidence for the different recommendations, in Tables of Evidence (ToEs). These ToEs are available online, as [Supplementary Material](#).

**The revision process and update of guidelines.** The guidelines document underwent external review for critical evaluation of the content and recommendations by members of the ESVS Guidelines Steering Committee, and by other independent experts in the field. After each review round, the reviewers’ general and detailed comments were compiled into one document. The manuscript was then revised according to the reviewers’ comments and all amendments were discussed and approved by all members of the GWC. In addition, a point to point reply to the reviewers was provided. After three review and subsequent revision rounds, the final document was approved and submitted to the *European Journal of Vascular and Endovascular Surgery* on 10 November 2021. These guidelines will be updated in 2026, according to the ESVS policy to update all guidelines which are part of the core curriculum of the vascular surgeon every four years.

**The patient perspective.** The importance of patient and public involvement in clinical guideline development is widely recognised and accepted. Patient engagement improves validity, increases quality of decisions, and is encouraged by national and international groups.

To improve accessibility and interpretability for patients and the public, a plain English summary has been produced for this guideline and subjected to a lay review process. Information for patients was drafted for each subchapter which was read and amended by a vascular nurse specialist and at least one lay person or patient.

Lay summaries were evaluated by a patient focus group, consisting of eight patients in the United Kingdom National Health Service with a history of CVD (six patients with C2-C5 disease and two patients with C6 disease) and three lay members of the public without CVD. All members of the focus group had been sent the lay summaries prior to the meeting, which was held virtually because of COVID-19 restrictions. At the meeting, the background and rationale for the ESVS CVD guidelines were presented and focus group feedback was obtained for each section of the document, systematically. All members of the focus group welcomed the invitation to contribute to the process and many commented that their personal experiences of care had been very different to the treatments recommended in the guidelines. Specifically,



referral for specialist venous assessment had often been very delayed, although this may be a specific reflection of the United Kingdom National Health Service.

Several patients stated that they had tried compression garments but found them difficult to wear. The group felt it important to express that where compression is recommended to patients, aids to help donning and removal of the stockings should be provided. The section describing superficial venous ablation procedures was found to be complex by the patients and lay members of the focus group and was simplified accordingly. Six of the patients in the focus group had been treated with endovenous ablation procedures. The group emphasised the importance of shared decision making and stated that they would want to discuss potential treatment options even if not locally available. Feedback from the focus group was used to amend the lay summaries.

### Areas not covered by these guidelines

The general rule for ESVS guidelines is to avoid covering groups of patients in multiple guidelines as that may result in redundancy. Therefore, patients with superficial vein thrombosis (SVT) are mentioned only briefly and patients with deep vein thrombosis (DVT) are not covered in these guidelines,

even if both SVT and DVT may occur as acute complications in patients with CVD. As these acute conditions require different management, the reader is referred to the ESVS 2021 Clinical Practice Guidelines on the Management of Venous Thrombosis.<sup>2</sup> It was also decided to leave out congenital venous malformations, which will be part of future ESVS guidelines on vascular malformations, as well as venous tumours.

## 1. GENERAL CONSIDERATIONS

In the VEIN-TERM transatlantic interdisciplinary consensus document, the term chronic venous disease (CVD) has been defined as “(any) morphological and functional abnormalities of the venous system of long duration manifest either by symptoms and/or signs indicating the need for investigation and/or care”.<sup>3</sup> As not all venous abnormalities can be considered a “disease”, the term “chronic venous disorders” has also been introduced, to encompass the full spectrum of morphological and functional abnormalities of the venous system. In the present guideline document the focus is on patients with symptoms and/or signs of CVD, requiring investigation and/or care. To describe CVD in the lower limbs of these patients, the Clinical, Etiological, Anatomical, Pathophysiological (CEAP) classification is used, which is the

**Table 3. The 2020 update of the CEAP (Clinical Etiological Anatomical Pathophysiological) classification<sup>6</sup>**

Class	Description
<i>Clinical (C) class</i>	
C0	No visible or palpable signs of venous disease
C1	Telangiectasia or reticular veins
C2	Varicose veins
C2r	Recurrent varicose veins
C3	Oedema
C4	Changes in skin and subcutaneous tissue secondary to CVD
C4a	Pigmentation or eczema
C4b	Lipodermatosclerosis or atrophie blanche
C4c	Corona phlebectatica
C5	Healed ulcer
C6	Active venous ulcer
C6r	Recurrent venous ulceration
Symptomatic or not: subscript ‘S’ or subscript ‘A’	S: symptomatic, including ache, pain, tightness, skin irritation, heaviness, and muscle cramps, and other complaints attributable to venous dysfunction A: asymptomatic
<i>Etiological (E) class</i>	
Ep	Primary
Es	Secondary
Esi	Secondary – intravenous
Ese	Secondary – extravenous
Ec	Congenital
En	None identified
<i>Anatomical (A) class</i>	
As	Superficial
Ad	Deep
Ap	Perforators
An	No identifiable venous location
<i>Pathophysiological (P) class*</i>	
Pr	Reflux
Po	Obstruction
Pr,o	Reflux and obstruction
Pn	No pathophysiology identified

\* Reporting of pathophysiological class must be accompanied by the relevant anatomical location (see Table 4). CVD = chronic venous disease.

most widely used descriptive tool for chronic venous disorders and disease.<sup>4,5</sup> CEAP allows detailed documentation of disease status at a specific time point, within four domains: clinical, aetiological, anatomical, and pathophysiological (Table 3). A recent update of the CEAP classification was published in 2020, including new categories for corona phlebectatica (C4c), recurrent varicose veins (C2r), and recurrent leg ulceration (C6r), a subdivision of secondary aetiology into intravenous (Esi) and extravenous (Ese) causes, and new abbreviations for anatomical terms, to replace the previously used numerical description (Table 4).<sup>6</sup>

The term “chronic venous insufficiency” (CVI) is reserved for advanced CVD, which is applied to functional abnormalities of the venous system, producing oedema, skin changes, or venous ulcers, corresponding with C3 to C6 of the CEAP classification.<sup>3</sup>

### 1.1. Epidemiology

A recently published comprehensive systematic review on global epidemiology of CVD identified 32 studies from six continents including > 300 000 adults.<sup>7</sup> Nineteen studies were used for unadjusted, pooled prevalence for each C class of the CEAP classification, from C0<sub>s</sub> (symptomatic, no clinical signs) to C6 (venous leg ulcer). Pooled estimates were: C0<sub>s</sub>: 9%, C1: 26%, C2: 19%, C3: 8%, C4: 4%, C5: 1%, C6: 0.4%. The pooled prevalence of C2 disease was highest

in Europe (21%) and lowest in Africa (5.5%). The annual incidence of C2 disease ranged from 0.2% to 2.3%. CVD progression was estimated to affect 31.9% of patients at a mean follow up of 13.4 years. C2 disease had a progression rate of 22% developing a venous leg ulcer (VLU) in six years. Commonly reported risk factors for CVD included female gender, age, obesity, prolonged standing, positive family history and parity. The authors of this review conclude that significant heterogeneity exists in epidemiological studies and future research needs to use diagnostic duplex ultrasound (DUS), to provide more complete data. The high prevalence of C0<sub>s</sub> in the systematic review mentioned above is mainly the result of an important contribution by studies from the Vein Consult Programme, an international survey performed by general practitioners worldwide during 100 000 routine consultations, without DUS, where a prevalence of C0<sub>s</sub> of 19.7% was found.<sup>8</sup> It should be acknowledged that the available evidence on C0<sub>s</sub> remains very limited.

Although progression of CVD is important, few epidemiological studies have investigated its natural history. In the Edinburgh Vein Study, a random sample of 1 566 men and women aged 18 – 64 years had been examined at baseline.<sup>9</sup> Of these, 880 were followed up for 13 years and underwent clinical evaluation and DUS scanning of the deep and superficial venous systems, and 0.9% (CI 0.7 – 1.3%) of

**Table 4. The 2020 update of CEAP (Clinical Etiological Anatomical Pathophysiological): Summary of anatomical classification<sup>6</sup>**

Anatomical classification	Segment number <sup>*</sup>	New anatomical site <sup>†</sup>	Description
As (Superficial)	1	Tel	Telangiectasia
	1	Ret	Reticular veins
	2	GSVa	Great saphenous vein, above knee
	3	GSVb	Great saphenous vein, below knee
	4	SSV	Small saphenous vein
Ad (Deep)	–	AASV	Anterior accessory saphenous vein
	5	NSV	Non-saphenous vein
	6	IVC	Inferior vena cava
	7	CIV	Common iliac vein
	8	IIV	Internal iliac vein
	9	EIV	External iliac vein
	10	PELV	Pelvic vein
	11	CFV	Common femoral vein
	12	DFV	Deep femoral vein
	13	FV	Femoral vein
Ap (Perforator)	14	POPV	Popliteal vein
	15	TIBV	Crural (Tibial) vein
	15	PRV	Peroneal vein
	15	ATV	Anterior tibial vein
	15	PTV	Posterior tibial vein
	16	MUSV	Muscular veins
	16	GAV	Gastrocnemius vein
An (No venous anatomic location identified)	16	SOV	Soleal vein
	17	TPV	Thigh perforator vein
	18	CPV	Calf perforator vein

\* Numbers of anatomical segments used in the 2004 revision<sup>5</sup> of the CEAP classification.

† New specific anatomical location(s) to be reported under each Pathophysiological (P) class to identify anatomical location(s) corresponding to P class.

this adult population developed reflux each year. Progression occurred more often in overweight subjects and in those with a history of DVT, but there was no association with patient sex or age. In two thirds of all cases reflux was limited to the superficial venous system. The presence of venous reflux at baseline was significantly associated with the development of new varicose veins (VVs) at follow up, especially when combined deep and superficial reflux was present.<sup>10</sup> During the 13 years of observation, CVD progression was reported in 57.8%, for an annual rate of 4.3%, and one third of patients with uncomplicated VVs at baseline developed skin changes.<sup>11</sup> The natural history of CVD was also investigated in a large longitudinal study, the Bochum study I-IV, which included initially 740 pupils of 10 – 12 years (Bochum I), 136 of whom underwent follow up to the age of 30 years (Bochum IV). This study revealed that preclinical venous reflux, identified in a young population, represented a 30% risk (95% CI 13 – 53%) of developing truncal VVs within four years.<sup>12</sup>

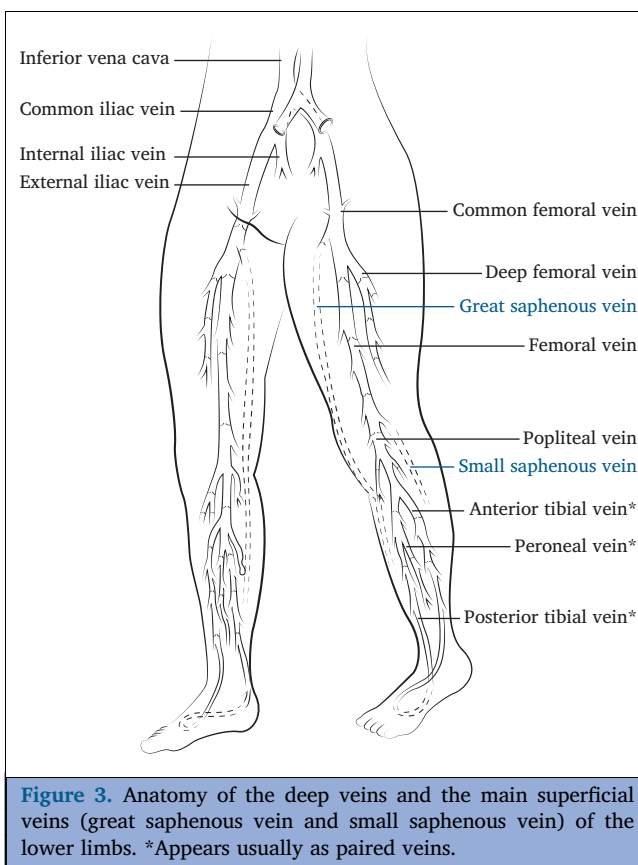
## 1.2. Anatomy

The anatomy of the superficial, perforating, and deep veins of the lower limbs has been described extensively.<sup>13,14</sup> The anatomical terms and their abbreviations used in the present guidelines correspond with the 2020 update of the CEAP classification (Table 4).<sup>6</sup> The main veins of the lower limbs are represented in Fig. 3.

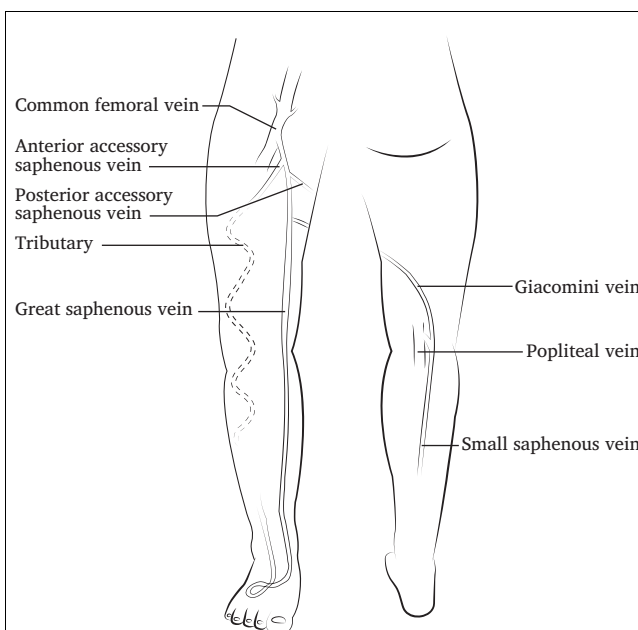
### 1.2.1. The superficial and perforating veins of the lower limb.

The great saphenous vein (GSV) drains into the common femoral vein (CFV) at the level of the saphenofemoral junction (SFJ). The GSV lies in its saphenous compartment, which is easily recognisable on B mode ultrasound scanning. The most important accessory saphenous vein is the anterior accessory saphenous vein (AASV), which runs almost parallel and slightly lateral to the GSV in the thigh, in its own saphenous compartment (Fig. 4). The small saphenous vein (SSV) ascends upwards on the posterior calf to join the popliteal vein (POPV) in the popliteal fossa in the majority of cases, although the level of the junction with the deep venous system may vary. Veins connecting the GSV and SSV are called “intersaphenous veins”. A particular intersaphenous vein is the Giacomini vein (Fig. 4) connecting the SSV in the popliteal fossa with the cephalad GSV. DUS has revealed the large variability of the superficial veins and therefore it is mandatory to rely on the so called “duplex anatomy” to plan any treatment.<sup>15,16</sup>

Tributaries of the saphenous trunks and accessory veins are situated in the subcutaneous tissue with a very variable distribution and present as visible or palpable, usually tortuous VVs. Perforating veins (PVs) are variable in arrangement and distribution, connecting the deep and superficial veins, with unidirectional valves assuring flow from superficial to deep veins, except in the foot. PVs form a complex subfascial network of interconnected veins.



**Figure 3.** Anatomy of the deep veins and the main superficial veins (great saphenous vein and small saphenous vein) of the lower limbs. \*Appears usually as paired veins.



**Figure 4.** Anatomy of the main accessory saphenous veins and Giacomini vein (intersaphenous vein connecting the small saphenous vein with the great saphenous vein). In the presence of a Giacomini vein, the saphenopopliteal junction may be present or absent.

**1.2.2. The deep veins of the lower limb.** The paired posterior tibial veins and the peroneal veins in the calf join to form the tibioperoneal trunk, which joins the anterior tibial veins. Large veins of the soleus and gastrocnemius muscles join these to form the POPV. This ascends in the adductor canal becoming the femoral vein (FV), which joins the deep femoral vein (DFV) to form the CFV in the groin. Above the inguinal ligament, the CFV continues as the external iliac vein (EIV) and, after receiving the internal iliac vein (IIV), continues as the common iliac vein (CIV). On the left side the CIV passes between the right common iliac artery and the vertebral column. From the confluence of the right and left CIV, the inferior vena cava (IVC) ascends alongside the right of the aorta.

**1.2.3. Small veins and the microvenous circulation.** Small veins of the subcutaneous and cutaneous venous network have been studied less extensively than large veins and their valves.<sup>17</sup> Previously, the belief was that venous valves did not exist in veins and venules of < 2 mm. However, detailed studies of small veins in the skin of the lower leg showed that valves do exist even in veins with a diameter from 100 µm – 2 mm, and that these microvenous valves also can be incompetent.<sup>18</sup> A study using retrograde resin venography in amputated lower limbs demonstrated that valvular incompetence can exist in these small veins, independently of valvular competence of the GSV. In the third generation of tributaries from the GSV the so called “boundary” valves can be seen, which are able to prevent reflux to the skin. When GSV reflux is present, incompetence of these microvalves may play a critical role in progression of skin changes.<sup>19</sup>

### 1.3. Pathophysiology

The pathophysiology of CVD is best considered as having two distinct components, namely the events that occur within the larger superficial and deep veins and those that occur subsequently in the microcirculation and surrounding tissues of the skin. In the superficial veins changes occur within the venous wall and valves leading to valve incompetence, changes in vasomotor tone, and reflux. This is followed by vascular remodelling and degenerative loss of elastin and collagen as well as fibrosis with changes in wall thickness and development of VVs. The initial causes of these changes are believed to be inflammatory phenomena.<sup>20,21</sup> Endothelial cells play a key role in this inflammatory cascade, with consequent pathological venous changes and increasing deterioration of CVD.<sup>22</sup> These pathophysiological phenomena may progress in an ascending (first in the tributaries, followed by the saphenous trunks, thereafter at the junction) or descending pattern (first at the junction, followed by the saphenous trunks, thereafter in tributaries).<sup>23</sup> The consequence of reflux and changing wall compliance is faster refilling, less efficient venous emptying, and venous hypertension particularly in the erect position and with walking. Perforator flow, which is normally from superficial to deep veins (re-entry), may also increase leading to remodelling, enlargement, and development of PV incompetence.

In the deep veins, the pathophysiology differs and venous emptying is compromised by either obstruction and/or reflux.

This is most often secondary to DVT and is categorised as “Esi” (secondary aetiology, intravenous) in the updated CEAP classification.<sup>6</sup> If the thrombus lyses or recanalises, the valves may be damaged or destroyed and deep venous reflux occurs. If the thrombus does not lyse or recanalise sufficiently, the vessel lumen remains narrow or occluded and outflow is obstructed. PVs may be similarly affected, lose valvular competence, remodel, and enlarge with outward flow. As a consequence, the deep venous changes may lead to venous hypertension in the superficial veins.<sup>24</sup> This pathway and related symptoms/signs has been called post-thrombotic syndrome (PTS).<sup>3</sup> When both obstruction and reflux are present, the clinical course may be more severe.<sup>25</sup>

Other causes of impaired venous emptying and venous hypertension with similar outcomes (categorised as “Ese” [secondary aetiology, extravenuous] in the updated CEAP classification)<sup>6</sup> include extrinsic vein compression (e.g., intra-abdominal masses or iliac vein compression), raised venous pressure with right heart failure, impaired muscle pump, and obesity.

The pathophysiology of CVD in the skin and subcutaneous tissue of the lower leg is distinct from that seen in the larger veins and is primarily a consequence of venous hypertension on the microcirculation. Small veins and venules also have valves which become incompetent and, along with capillaries, elongate, dilate, and become tortuous. The severity of these morphological changes observed with capillaroscopy correlate well with the severity of skin changes of CVD.<sup>26</sup> As these changes occur, the endothelium of the capillary and post-capillary venules becomes progressively dysfunctional with fluid leakage, complex inflammatory mediators, and cell migration. These result in oedema, fibrin cuff formation, inflammatory reaction, and a chronic deteriorating sequence of inflammation, fibrosis, pigmentation, and calcification within the dermis, with paradoxical hyperaemic hypoxia and loss of normal integrity of the skin with VLU formation.

The clinical significance of venous hypertension has been extensively investigated with direct venous pressure measurements in a dorsal foot vein. When standing the venous pressure is high (80 – 90 mmHg), but with activation of the calf muscle pump as during tip toe exercise or walking, known as ambulatory venous pressure (AVP), it is substantially reduced (20 – 30 mmHg). Failure to adequately lower the standing venous pressure while walking results in a high AVP. A recent large retrospective study including 4 132 limbs with CVD symptoms, confirmed that an increase in AVP is associated with a higher clinical class of CVD, but was mainly associated with reflux and less commonly with proximal obstruction.<sup>27</sup>

### 1.4. Clinical presentation

**1.4.1. Symptoms.** The symptoms of CVD are extremely variable and may cause significant morbidity to patients, negatively affecting quality of life (QoL). Symptoms increase with age and are more commonly reported in women. Patients may present with heaviness, tired legs, feeling of

swelling, itching of the skin, nocturnal cramps, throbbing, burning pain, aching of the legs, which is exacerbated by prolonged standing or sitting, or venous claudication during exercise. It is sometimes difficult to attribute symptoms to a venous aetiology and call them “venous symptoms”. All clinical CEAP classes from C0<sub>s</sub> to C6 can be associated with the same symptoms, which do not necessarily correlate with the presence or severity of venous hypertension.<sup>28</sup> CVD can be asymptomatic, even in limbs with extensive VVs and even C4 and C5 clinical CEAP class, while venous symptoms can be present without any clinical sign of CVD (C0<sub>s</sub>). On the other hand, similar symptoms are frequently present in patients with other diseases of the lower limbs.<sup>29</sup>

Symptoms of heaviness, sensation of swelling, burning, itching, and pain/aching are associated with higher C of the CEAP clinical class both in intensity and number of symptoms. Symptoms such as fatigue, cramps, and restless legs are less specific for CVD.<sup>30,31</sup>

Venous claudication is a symptom presenting as increasing pain on exercise. It is caused by outflow obstruction at the iliofemoral and/or caval level as well as popliteal vein entrapment, leading to limited walking capacity.<sup>28</sup> In a small study in 39 patients, at a median follow up of five years after iliofemoral DVT, a standardised treadmill test (3.5 km/h, slope 10%) elicited venous claudication, necessitating interruption of walking in 15% of patients.<sup>32</sup>

**1.4.2. Signs.** In CVD, clinical signs are described per limb as the “C” component of the CEAP classification, from C1 to C6 (Table 3).<sup>6</sup> Other typical clinical signs, not included in the CEAP classification, are the presence of cross pubic collaterals in case of unilateral iliac vein obstruction, abdominal collaterals in case of IVC obstruction (caused by previous DVT, congenital absence/hypoplasia, or extrinsic compression) (see Chapter 5) and vulvar VVs in women with pelvic venous disorders (PeVD) (see Chapter 7).

**1.4.3. Acute complications.** Acute complications are uncommon in patients with CVD. The most common is SVT, which may be limited to a varicose tributary, or affect a saphenous trunk. This can be complicated by extension into the deep venous system as a concomitant DVT and, exceptionally cause pulmonary embolism (PE). In patients with CVD, DVT or a recurrent DVT may occur. In general, VVs are considered a minor risk factor for developing DVT, as discussed in the ESVS guidelines on the management of venous thrombosis.<sup>2</sup> In a population based study it was concluded that it is unclear whether the association between VVs (without SVT) and DVT is causal or a result of common risk factors.<sup>33</sup>

Another acute complication is haemorrhage, which is commonly associated with a traumatised superficial vein or telangiectasia, but significant bleeding can also arise from an area of ulceration. The resulting blood loss may be extensive and even life threatening.<sup>34</sup>

### 1.5. Scoring systems

When considering scoring systems for CVD, it is important to realise that the CEAP classification gives a descriptive snapshot of a limb with CVD at a point in time, allowing grouping into CVD subgroups. While changes in CEAP class provide useful information and may guide management, the CEAP classification is categorical and therefore not well suited for monitoring treatment success, assessing disease progression, or rationing interventions. Scoring tools, which provide continuous variables, are more suitable for this purpose.

**1.5.1. Clinical scoring systems.** Clinical scoring systems were developed to provide a more dynamic assessment of patient status over time. The revised Venous Clinical Severity Score (r-VCSS) is the most widely used clinical scoring tool and is designed to measure changes in status after venous intervention (Table 5).<sup>35,36</sup> The Villalta scale is an in part

**Table 5. The revised Venous Clinical Severity Score (r-VCSS)<sup>35</sup>**

Variable	Description (score)			
	Absent (0)	Mild (1)	Moderate (2)	Severe (3)
Pain* or ulcer discomfort	None	Occasional	Daily, interfering with, but not preventing regular activities	Daily, limiting most regular activities
Varicose veins	None	Few, scattered or corona phlebectatica	Confined to calf or thigh	Involve calf and thigh
Venous oedema	None	Limited to foot or ankle	Extends above ankle but below knee	Extends to knee or above
Skin pigmentation	None or focal	Limited to perimalleolar area	Diffuse over lower third of calf	Wider distribution (above lower third of calf)
Inflammation	None	Limited to perimalleolar area	Diffuse over lower third of calf	Wider distribution (above lower third of calf)
Induration	None	Limited to perimalleolar area	Involving lower third of calf	Involving more than lower third of calf
Number of active ulcers	None	1	2	> 2
Active ulcer duration	None	< 3 mo	> 3 mo but < 1 y	> 1 y
Active ulcer size	None	Diameter < 2 cm	Diameter 2–6 cm	Diameter > 6 cm
Compression therapy	Not used	Intermittent use of stocking	Stocking use most days	Full compliance with stockings

\* Ache, heaviness, fatigue, soreness, and burning presumptive of a venous origin.



**Table 6. The Villalta scale and its interpretation for post-thrombotic syndrome (PTS)<sup>37</sup>**

Clinical findings <sup>a</sup>	None	Mild	Moderate	Severe
<i>Symptoms</i>				
Pain	0	1	2	3
Cramping	0	1	2	3
Heaviness	0	1	2	3
Pruritis	0	1	2	3
Paraesthesia	0	1	2	3
<i>Signs</i>				
Oedema	0	1	2	3
Induration	0	1	2	3
Hyperpigmentation	0	1	2	3
Venous ectasia	0	1	2	3
Redness	0	1	2	3
Calf tenderness	0	1	2	3
<i>Interpretation of severity of post thrombotic syndrome</i>				
Villalta score	< 5	5–9	10–14	> 14 or the presence of venous ulceration

\* Each variable is given a score of between 0 and 3 indicative of a severity of none, mild, moderate, or severe, respectively, with a maximum score of 33.

patient rated and in part physician rated tool for diagnosing and evaluating the severity of PTS in the lower extremity (Table 6).<sup>37,38</sup> While the Villalta scale is widely used and validated for use in patients with PTS, it should be noted that its specificity has been questioned, as several of the included symptoms and signs are features of CVD in patients without a history of DVT.

**1.5.2. Patient reported outcome measures.** Patient reported outcome measures (PROMs) are often considered the “gold standard” tools for evaluating success after interventions. There is a range of validated disease specific and generic PROMs available. However, they can be complex and time consuming to use and analyse, which is a limit to their applicability in clinical practice. A detailed description of all these tools is beyond the scope of the present guidelines. Commonly used disease specific QoL tools in CVD are the Aberdeen Varicose Veins Questionnaire (AVVQ) (Supplementary Table S1),<sup>39</sup> the Chronic Venous Insufficiency Questionnaire (CIVIQ) (Supplementary Table S2),<sup>40</sup> and the Venous Insufficiency Epidemiological and Economic Study quality of life/symptoms (VEINES-QoL/Sym) (Supplementary Table S3).<sup>41</sup> Despite the potential advantages, use of patient reported QoL tools is uncommon outside clinical trials and health economic studies. Nevertheless, the importance of PROMs is recognised increasingly and mandated in some international venous registries.

Recommendation 1		Unchanged
For patients with chronic venous disease, the use of the Clinical, Etiological, Anatomical, Pathophysiological (CEAP) classification is recommended for clinical audit and research.		
Class	Level	References
I	C	Consensus

Recommendation 2		Unchanged
For patients with chronic venous disease, grading of clinical severity and evaluation of treatment success using the revised Venous Clinical Severity Score (r-VCSS) and the Villalta scale for post-thrombotic syndrome, should be considered for clinical audit and research.		
Class	Level	References
IIa	C	Consensus

**2. INVESTIGATIONS**

This chapter describes the value of the different investigations used in patients with CVD. It describes physical examination and available additional tests. In the diagnostic work up, the nature of the problem and the severity of the disease should be determined.

**2.1. Clinical examination**

After medical history taking, focusing on venous symptoms (see subsection 1.4.1), thromboembolic history, allergies, and medication, the patient is examined in the standing position, whenever possible. Clinical signs of CVD as described in 1.4.2 are carefully sought, including visible scars in case of recurrence after previous VVs surgery and the presence of cross pubic, anterior, and lateral abdominal wall collaterals, which raises the suspicion of supra-inguinal venous pathology. Other possible causes for complaints and lower extremity clinical signs, such as arterial disease, orthopaedic, rheumatological, or neurological pathology are also evaluated. The circumference of both legs at the ankle and calf may be measured for oedema cases. Photographs may be added to the patient’s file for future comparison, in particular for skin changes.

## 2.2. Handheld continuous wave Doppler

Handheld continuous wave Doppler provides no information on venous morphology, has low reliability in detecting obstruction or reflux in deep veins, and research has shown that pre-operative planning on the basis of continuous wave Doppler alone, instead of DUS, results in inadequate treatment in a significant proportion of patients and therefore has no role in the diagnosis of CVD.<sup>42</sup> For these reasons, it has been replaced by DUS.

However, in patients with a suspicion of concomitant lower extremity atherosclerotic disease, handheld Doppler is still used to measure the ankle pressure and the ankle brachial index (ABI) (see subsections 3.2.1.3 and 6.3.3).

## 2.3. Duplex ultrasound

**2.3.1. Duplex ultrasound of the lower limbs.** DUS of the lower extremities is the primary diagnostic test of choice in patients with CVD.<sup>15,43,44</sup> It provides information about venous anatomy, patency, vein wall pathology, and flow. Morphological examination of deep veins and evaluation of normal phasic flow in the CFV may be performed in the supine position. To evaluate the presence or absence of reflux, DUS is preferentially done in the upright position with the knee of the investigated leg slightly bent. Reflux must be provoked, either from above with dependency testing or a Valsalva manoeuvre, or from below, using an automatic pneumatic pressure cuff or manual compression of the thigh, calf, or foot.<sup>15,44</sup> The Valsalva manoeuvre is typically used to assess the SFJ. The clinical significance of measuring reflux duration is questionable other than to establish its presence beyond a cut off duration. It depends on the provocation manoeuvre used and may be difficult to quantify. The cut off values most used are 1 second for reflux in the CFV, FV and POPV and 0.5 seconds in superficial veins and PVs, although 0.35 seconds has been used as a threshold for PVs as well.<sup>16,44,45</sup> Other useful information on ultrasound in CVD includes the course of the reflux, the length of the refluxing trunk, and saphenous trunk diameter, which should be measured in the upright position in a vein segment without focal dilatation (for the GSV at about 15 cm from the SFJ).<sup>46,47</sup> A detailed methodology for performing DUS of the lower extremities has been described previously.<sup>15,16</sup> In addition to a written DUS report, it is important to make an accurate graphical representation of the DUS findings in the superficial and deep veins of the examined limbs, called "venous mapping". This is an essential tool to plan and perform venous interventions.

**2.3.1.1. Varicose veins (first presentation).** The CFV, FV, and POPV are checked for patency, reflux, and any post-thrombotic obstruction. Then, the GSV, AASV, and SSV, including the SFJ and saphenopopliteal junction (SPJ), are examined for reflux, followed by any other relevant incompetent superficial veins. PV incompetence is sought especially in the vicinity of a VLU, severe skin changes,

absence of SFJ or SPJ incompetence as a source of reflux, and/or atypically located VVs.<sup>48</sup> The definition of PV incompetence remains controversial. PV incompetence is characterised by having a net outward flow of > 0.35 seconds duration (or > 0.5 seconds, according to others) on DUS and a vessel diameter > 3.5 mm is usually considered "pathological", in particular in an area with skin changes.<sup>45,49</sup>

**2.3.1.2. Recurrent varicose veins.** Recurrent VVs often display recanalisation of a saphenous trunk, previously treated by endovenous ablation, neovascularisation at the location of previous surgery (in particular at the SFJ), or reflux in other veins such as the AASV, the SSV, or PVs, which may have been healthy previously. The aim of the investigation is to identify the nature and source of the recurrence.<sup>16</sup>

**2.3.2. Abdominal ultrasound.** Whenever there is a suspicion of supra-inguinal pathology, based on clinical examination (extensive unilateral oedema, healed or active VLU, abdominal wall collaterals) or on specific DUS findings while examining the lower limbs (absence of phasic flow in the CFV, or post-thrombotic fibrosis in the deep veins), the next step is to perform an additional abdominal DUS. It should be acknowledged that DUS examination of abdominal and pelvic veins (i.e. gonadal veins and IIVs) requires appropriate expertise. If this is not available, cross sectional imaging may be preferred. In certain patients it may be technically difficult to perform abdominal DUS because of abdominal obesity or the presence of bowel gas. Abdominal DUS is preferably performed after the patient has been fasting overnight.<sup>50</sup> The patient is placed in supine position and the IVC and iliac veins are examined with DUS to detect potential compression or luminal obstruction and to evaluate direction of flow and velocities. The presence of collaterals, absence of phasic flow in the CFV, and flow velocity changes may indicate obstruction.<sup>51,52</sup> When DUS was compared with intravascular ultrasound (IVUS), a velocity ratio (maximum through obstruction velocity/maximum pre-obstruction velocity)  $\geq 2.5$  was found to be the best criterion for detecting significant venous outflow obstructions in iliac veins.<sup>51</sup> When PeVD are suspected, the left renal, gonadal, peri-uterine and para-vaginal veins, and the tributaries of the IIVs are examined.<sup>50</sup> After venous thrombolysis and stenting, DUS is often used for patency surveillance.

## 2.4. Cross sectional imaging

Cross sectional imaging encompasses techniques generating two dimensional images perpendicular to the axis of the body, most commonly magnetic resonance (MR) imaging and computed tomography (CT).<sup>53,54</sup> Cross sectional imaging may offer an alternative tool in the detection of deep venous pathology when DUS is inadequate or not feasible. Whether to perform MR or CT to investigate the deep veins

is mainly dependent on the local expertise in performing and evaluating these images.

**2.4.1. Magnetic resonance venography.** MR venography (MRV) can provide information about the venous system that is enhanced by 3-D reconstruction. Dynamic imaging information can be provided as well with regard to velocity and volume. MRV can visualise deep vein obstruction, fibrotic scarring of the vein wall and in the lumen (post-thrombotic fibrosis), as well as collaterals and VVs.<sup>55</sup>

**2.4.2. Computed tomography venography.** CT venography (CTV) is generally more available than MRV and its imaging protocols receive wider acknowledgement by the medical community.<sup>56</sup> Obviously, CTV necessitates the use of iodinated contrast and ionising radiation, comparing unfavourably with MRV. There are two main techniques for performing lower limb CTV. Indirect CTV is performed as post-intravenous contrast enhanced CT, with imaging results largely dependent on cardiac output, size of the intravenous line, rate of injection, and degree of hydration. Direct CTV generally involves intravenous injection of contrast in the foot or directly into the FV or POPV with ascending acquisition of imaging, providing improved detail. Direct CTV may allow for increased detailed imaging of luminal pathology. However, contrast transit times are hard to predict and therefore adequate imaging of abdominal, pelvic, and peripheral veins may be cumbersome.

**2.5. Endovenous imaging**

Historically, angiography has been established as the “gold standard” to diagnose macroscopic vascular pathology. However, for CVD, venography has not been adequately validated. Ever since endovascular treatment became available for chronic venous obstruction, IVUS has challenged venography for dominance. However, it needs to be emphasised that none of the currently available imaging modalities have been validated for clinically relevant CVD.

**2.5.1. Venography.** Classical ascending venography (also called phlebography) by access and contrast injection from a foot vein has no additional value over DUS to screen for deep venous obstruction and is now considered obsolete. Venography with access gained through the POPV, FV, or CFV, has previously been used to evaluate particular aspects of supra-inguinal venous obstruction. It can indirectly diagnose left CIV obstruction through the identification of a combination of collaterals and a flattened CIV (pancaking).<sup>57</sup> Although multiplanar venographic imaging in at least two perpendicular projections may improve its diagnostic value, it is impractical and increases radiation exposure and iodinated contrast use. Another challenge relates to the immobile, prone, or supine position of the patient, which may over- or underdiagnose CVD. Intravenous imaging of proximal venous outflow obstruction has primarily been substituted by IVUS. However, the method can still be used if other imaging techniques are inadequate or unavailable. Descending venography may also be applicable in rare cases

where deep valve reconstructive surgery is being considered (see subsection 5.4).

**2.5.2. Intravascular ultrasound.** IVUS has become an increasingly useful investigation for deep venous pathology over the last decade. Like CTV and MRV, IVUS accurately determines cross luminal diameter and surface area of the deep veins. However, in addition, IVUS can identify subtle intraluminal changes and vein wall abnormalities that may remain obscure if other imaging techniques are used. It has been shown to be more sensitive than venography in identifying deep venous lesions, as has been shown in the VIDIO trial. In this RCT, 100 patients with C4 to C6 CEAP clinical class and suspected iliofemoral vein obstruction underwent both IVUS and multiplanar venography. IVUS proved to be more sensitive than venography in identification and quantification of iliofemoral vein obstructive lesions. Therefore, IVUS may provide an additional advantage in patient selection for venous stenting.<sup>58</sup> However, IVUS is an invasive modality and can be used only if the lesion of interest can be crossed with a guidewire first.

**2.6. Plethysmography**

Air plethysmography measures the global change in volume in mL/s of the part of the calf enclosed by the cuff, in response to gravitational filling on dependency (venous filling index) and drainage on leg elevation (venous drainage index).<sup>59,60</sup> Rapid filling and slow elevation drainage are indicative of global venous incompetence and obstruction, respectively.<sup>61</sup> This is in contrast to ultrasound flow measurements in selected vein segments induced by a compression/release manoeuvre.

Strain gauge plethysmography is an alternative that extrapolates global calf volume change from the change in impedance from a circumferential band applied around a selected part of the calf.<sup>62</sup> Photoplethysmography reflects volume in the leg indirectly by changes in the skin micro-circulation. These tests may be of clinical value in screening, diagnosis, surveillance, follow up, and outcome assessment.<sup>63–65</sup>

<b>Recommendation 3</b>		<b>Unchanged</b>	
For diagnosis and treatment planning in patients with suspected or clinically evident chronic venous disease, full lower limb venous duplex ultrasound is recommended as the primary imaging modality.			
<b>Class</b>	<b>Level</b>	<b>References</b>	<b>ToE</b>
I	B	Blomgren <i>et al.</i> (2011) <sup>43</sup>	

<b>Recommendation 4</b>		<b>New</b>	
For patients with suspected supra-inguinal venous obstruction, in addition to full leg duplex assessment, ultrasound of the abdominal and pelvic veins should be considered, as part of the initial assessment.			
<b>Class</b>	<b>Level</b>	<b>References</b>	<b>ToE</b>
IIa	C	Metzger <i>et al.</i> (2016) <sup>51</sup>	

Recommendation 5		Unchanged	
When an intervention is contemplated in patients with suspected supra-inguinal venous obstruction, cross sectional imaging by magnetic resonance venography or computed tomography is recommended in addition to duplex ultrasound assessment.			
Class	Level	References	ToE
I	C	Coelho <i>et al.</i> (2019) <sup>56</sup>	

Recommendation 6		Unchanged	
For selected patients with suspected supra-inguinal venous obstruction, where cross sectional diagnostic imaging is inadequate or not available, venography and/or intravascular ultrasound may be considered.			
Class	Level	References	ToE
Iib	B	Gagne <i>et al.</i> (2017), <sup>58</sup> Lau <i>et al.</i> (2019) <sup>57</sup>	

Recommendation 7		Unchanged	
For patients with chronic venous disease, air plethysmography may be considered for quantification of reflux and/or obstruction, in particular when duplex ultrasound results do not reconcile with the clinical findings.			
Class	Level	References	ToE
Iib	C	Lattimer <i>et al.</i> (2016), <sup>59</sup> Lattimer <i>et al.</i> (2017), <sup>61</sup> Raju <i>et al.</i> (2019), <sup>60</sup> Lattimer <i>et al.</i> (2019), <sup>63</sup> Kalodiki <i>et al.</i> (2019) <sup>64</sup>	

## 2.7. Diagnostic strategy

Although in this chapter medical history taking, clinical examination and DUS have been described as separate parts of the investigation, in clinical practice, they may be done either sequentially or simultaneously, depending on the local setting.

DUS can be used to diagnose venous reflux, to plan treatment, for ultrasound guidance during treatment, and is also a useful tool for post-operative assessment and surveillance in CVD. It may be performed by the physician, as an integral part of the examination of the patient, or by a vascular technologist reporting to the physician.

The main diagnostic pathways are summarised in Fig. 5. In all patients presenting with a suspicion of lower limb CVD, based on history and clinical examination, full leg DUS should be performed routinely. If there is any suspicion of supra-inguinal pathology, based on clinical examination or specific DUS findings (see subsection 2.3.2), additional abdominal and pelvic DUS is the next step. Where intervention is contemplated, it may be appropriate to assess the inflow from the DFV into the CFV by DUS.

The anatomical extent of reflux or obstruction in affected veins combined with the patient's general characteristics, symptoms, and clinical signs can help the clinician to plan

and customise treatment.<sup>15,16,44</sup> There is considerable individual variation in the vulnerability to venous hypertension and thus the presence of reflux on DUS is not an indication for treatment *per se* (see subsection 4.1.1). If it is concluded, after DUS, that the symptoms and signs are not related to CVD, referral to the general practitioner or to another specialist is the logical next step. If the patient is not a candidate for intervention, advice about conservative measures should be provided (see Chapter 3) as well as follow up appointments, as necessary.

If the DUS findings only indicate disease below the inguinal ligament, this may be isolated superficial venous reflux or combined superficial and deep venous reflux, for which superficial venous intervention may be planned (see Chapter 4). In rare cases, superficial veins may contribute significantly to venous outflow by bypassing an obstructed femoropopliteal segment. Intervention on these veins is contraindicated (see subsection 5.5).

Finally, in patients with isolated deep venous incompetence, descending venography may be indicated.

Suspected supra-inguinal venous obstruction is further evaluated, by abdominal DUS or directly, by means of cross sectional imaging, most commonly MRV or CTV.<sup>51,53,56</sup> In selected patients, where cross sectional imaging is inadequate or not available, venography and/or IVUS may be planned.

Air plethysmography, if available, may be of diagnostic value in specific clinical scenarios such as unexplained leg oedema, even after previous treatment, and skin changes, including VLU, persisting after treatment of all sources of reflux. The specialised technique of occlusion plethysmography may be of value also in patients with complex PTS.<sup>63</sup>

The diagnostic approach for patients with VVs and suspected underlying PeVD is described in Chapter 7.

## 3. CONSERVATIVE MANAGEMENT

This section mainly focuses on conservative measures in CVD patients without active VLU. The conservative management options for patients with VLU are discussed extensively in Chapter 6.

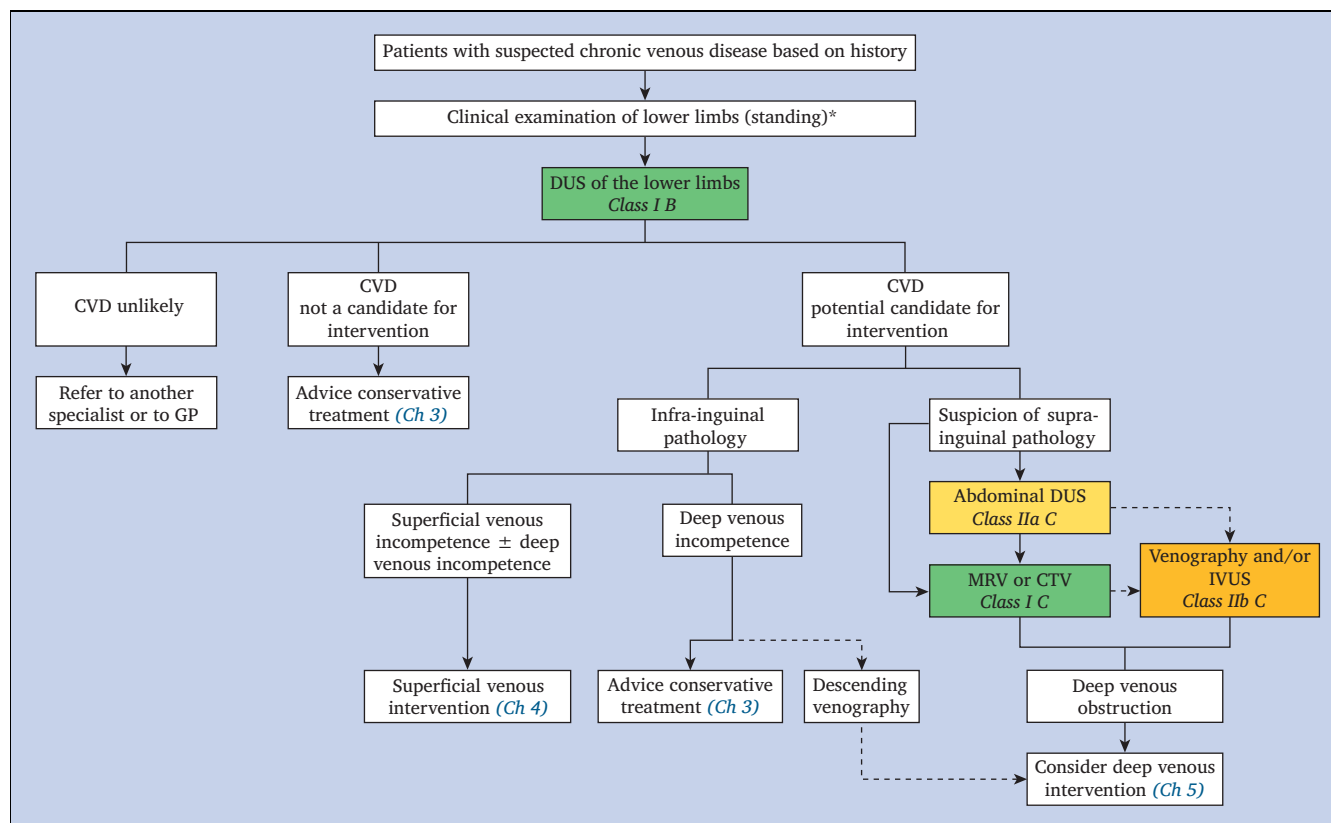
### 3.1. Physical methods

Physical methods for treating CVD are studied increasingly as an adjunct or alternative to interventional treatment. Physical exercise, targeting lower limb muscle strength and ankle mobility, and physiotherapy may improve general mobility, promote weight loss, strengthen the calf muscle pump, and increase the range of ankle movements, all these facilitating venous return.<sup>66–69</sup> Nevertheless larger studies are still needed.

Subsequently this may reduce leg oedema and prevent or ameliorate skin changes caused by CVD. It may also alleviate symptoms and signs of PTS, although available evidence is scarce.<sup>70</sup> Despite the paucity of studies specifically on CVI, the indirect evidence for the benefit of exercise on venous function is considerable and thus it should be promoted.<sup>67</sup>

Leg elevation and the use of insoles to improve the foot muscle pump may be beneficial but most studies are small.





**Figure 5.** Main diagnostic pathways for patients with suspected chronic venous disease (CVD) of the lower limbs and main treatment pathways. Patients with symptomatic varicose veins and clinical suspicion of pelvic venous disorders are not included in this flowchart (see Fig. 15). \*Clinical examination includes inspection of abdomen for potential collaterals, in particular in case of suspected iliac or ilio caval obstruction. DUS = duplex ultrasound; GP = general practitioner; MRV = magnetic resonance venography; CTV = computed tomography venography; IVUS = intravascular ultrasound.

Other methods with less evidence for treatment of CVD, but with improvement of health related QoL, include massage, balneotherapy, and cooling therapy.<sup>66,71,72</sup>

A holistic approach is important, in particular in patients with CVI. Social and psychological factors are associated with delayed healing of VLU, and depression<sup>73</sup> and lower socioeconomic status are over-represented among patients with CVD. Surgical and physical interventions may be less efficient if these factors are not taken into account. Counselling and adequate support are important, including lifestyle modifications (such as frequent walks, using insoles, avoiding prolonged standing, resting with the legs slightly elevated, avoiding heat exposure),<sup>67</sup> and weight loss for obesity, which is increasingly recognised as one of the most important contributors to the development of CVD (see subsection 8.2.1).

### 3.2. Compression

Compression therapy is a widespread treatment modality in CVD. It mainly consists of four different compression modalities: elastic compression stockings (ECS), elastic and inelastic bandages, adjustable compression garments (ACG) and intermittent pneumatic compression (IPC) devices. ACG are made from stiff material with self adhesive straps, usually applied from the ankle to the knee. The straps can be stretched and adjusted around the leg. The more they are stretched, the higher the compression pressure. This section only addresses compression in limbs with clinical class C0<sub>s</sub> - C5 whereas compression in case of active VLU (C6) will be discussed in subsection 6.3. In limbs with clinical class C0<sub>s</sub> - C5 mainly ECS and ACG are used.

ECS, intended for medical use, exert a graduated compression pressure, which means compression pressure is always higher at ankle level than at calf level. ECS, bandages, and IPC can be knee or thigh high. No evidence is available about the preferred ECS length in different clinical situations. In practice, thigh length compression devices are prescribed mainly for oedema involving the whole leg (mainly caused by secondary lymphoedema in patients with PTS after extensive DVT), for SVT of the GSV above the knee and for post-operative use after high ligation and stripping

Recommendation 8 <span style="float: right;">New</span>			
For patients with symptomatic chronic venous disease, exercise should be considered to reduce venous symptoms.			
Class	Level	References	ToE
Ila	B	Kahn <i>et al.</i> (2011), <sup>70</sup> Araujo <i>et al.</i> (2016), <sup>66</sup> Gurdal Karakelle <i>et al.</i> (2021) <sup>68</sup>	



(HLS) or endovenous GSV ablation. In all other cases, knee length compression devices are used routinely.

When prescribing a compression device for CVD management, it is necessary to check for potentially concomitant lower extremity atherosclerotic disease by measuring the absolute pressure value at the ankle and the ABI. In diabetics, additional toe pressure measurement is indicated, as ABI may not be reliable due to medial arterial sclerosis. Compression pressure must be reduced in cases of impaired arterial status or severe neuropathy.<sup>74</sup> This is particularly important in patients with mixed arterial and venous ulcers (see [subsection 6.3.3](#)).

### 3.2.1. Elastic compression stockings, adjustable compression garments, and inelastic bandages

**3.2.1.1. Evidence.** Compression therapy by graduated ECS exerting an ankle pressure ranging from 15 to 32 mmHg has proven effective in relieving symptoms in patients with C1s – C3s CEAP clinical class by decreasing pain, heaviness, cramps, and oedema related to CVD.<sup>75,76</sup>

Compression therapy comprising ECS, inelastic bandages (IB), and ACG is effective in oedema treatment.<sup>77–79</sup>

ECS exerting 23 – 32 mmHg have been compared with IB exerting about 60 mmHg. IB were significantly more effective in reducing oedema after 48 hours but not anymore after seven days, showing that ECS are almost as effective as IB in reducing venous oedema.<sup>77</sup> In two comparable studies by the same group, a combination of two superimposed ECS in one study,<sup>78</sup> and an ACG in another study,<sup>79</sup> both of these compression devices exerting a pressure of about 40 mmHg were again compared with IB, exerting about 60 mmHg immediately after applying the bandages. Superimposed ECS and ACG were, respectively, as effective or more effective in reducing pitting venous oedema, when compared with IB. This equal or greater effectiveness of superimposed ECS or ACG can be explained by both devices being able to maintain their exerted pressure. IB quickly lose their initial high pressure, especially in oedematous legs, thereby becoming less effective.

In addition to the traditional graduated ECS, which exert a higher pressure at ankle than at calf level, progressive ECS, exerting a higher pressure at calf level than at the ankle level, have been reported to be more effective than graduated ECS in reducing venous symptoms, such as pain and heaviness.<sup>80</sup> This higher efficacy could be explained by higher pressure being exerted over the calf, where the muscle and venous reservoir are located, than over the ankle where there are just tendons and bones. Indeed, it has been demonstrated that progressive ECS are more effective than graduated ECS in improving the venous haemodynamics by ameliorating

the muscle pumping function.<sup>81</sup> Occupational oedema was also reduced more effectively by progressive ECS at calf level.<sup>82</sup> These results are partially contradicted by a RCT in which progressive ECS were shown to be effective, but to a lesser extent, when compared with graduated ECS.<sup>83</sup>

Compression therapy by ECS has also been shown to reduce skin induration in patients with lipodermatosclerosis (CEAP clinical class C4b).<sup>84</sup>

In patients with PTS there is limited evidence on the effectiveness of ECS, despite their common use in clinical practice. There are just three small studies on ECS with short duration of follow up.<sup>85–87</sup> Two studies showed no benefit of compression over no compression.<sup>85,86</sup> The other study reported beneficial effects on venous haemodynamics (as evaluated by air plethysmography) and not on clinical outcome.<sup>87</sup>

Finally, wearing compression to slow the progression or prevent the recurrence of VVs is not supported by the current published evidence.<sup>88</sup> There is only one study reporting that compression therapy was effective to reduce or prevent disease progression.<sup>89</sup> Therefore ECS should not be used exclusively for this aim.

**3.2.1.2. Compliance.** Compression therapy is generally well accepted and tolerated by patients with CVD,<sup>90</sup> although compliance remains an issue for a large number of patients, certainly in hot climate, in particular in tropical countries.<sup>91</sup> Innovative methods to investigate true compliance should be further evaluated.<sup>92,93</sup> The main complaints by non-compliant patients are pain, discomfort, sensation of heat, and skin irritation. Difficulties in donning and doffing ECS are also reported, especially by older patients, patients with functional impairments such as hand osteoarthritis, restricted mobility and joint problems in the spine and hip, or morbid obesity, making bending to the feet problematic or even impossible. In these cases, donning and doffing aids are available. In a small RCT, 40 elderly patients, aged > 65 years, suffering from advanced CVD (C4 – C6), tested different donning devices. It was concluded that donning devices improved patient ability to don ECS successfully.<sup>94</sup> A new type of compression stocking, without compression at the foot and heel, also has been shown to make donning and doffing easier.<sup>95</sup> However, the problem of donning is not completely solved for all patients.

**3.2.1.3. Contraindications to compression treatment.** Many clinical conditions that were considered a contraindication for compression in the past (arterial disease, skin infection, vasculitis, cellulitis) are no longer considered as such, provided proper precautions are taken. Only a few contraindications for sustained compression treatment remain, which are listed in [Table 7](#).<sup>74</sup>

**Table 7. Contraindications to compression treatment (modified with permission from Rabe et al., 2020<sup>74</sup>)**

Severe lower extremity atherosclerotic disease with ABI < 0.6 and/or ankle pressure < 60 mmHg
Extra-anatomic or superficially tunnelled arterial bypass at the site of intended compression
Severe heart failure, NYHA Class IV
Heart failure NYHA Class III and routine application of compression devices without clinical and haemodynamic monitoring
Confirmed allergy to compression material
Severe diabetic neuropathy with sensory loss or microangiopathy with the risk of skin necrosis*

ABI = ankle brachial index; NYHA = New York Heart Association; NYHA Class IV: fatigue, palpitations, dyspnoea and/or angina at rest; NYHA Class III: ordinary physical activity causes undue fatigue, palpitations, dyspnoea and/or angina - comfortable at rest. \* May not apply to inelastic compression exerting low levels of sustained compression pressure (modified compression).

**3.2.2. Other compression methods**

**3.2.2.1. Intermittent pneumatic compression.** IPC has a limited role in the conservative treatment of CVD. It can be used for oedema treatment in addition to compression by ECS, bandages, or ACG, or to replace them when sustained compression is not tolerated. There are no consistent data available on the use of IPC in CEAP clinical class C0<sub>s</sub> – C4. In patients with PTS, IPC has been used to alleviate symptoms. However, most studies are small and of short duration, resulting in a low level of evidence for the use of IPC for this indication.<sup>96</sup> The use of IPC in VLU is further discussed in subsection 6.3.2.

A new device combining sustained static pneumatic compression during ambulation and IPC while at rest has been investigated in a pilot study. This device was more effective than ECS, with better acceptance by the patients, resulting in increased compliance with compression therapy and oedema reduction.<sup>93</sup> Further studies will be necessary to confirm these findings.

**3.2.2.2. Neuromuscular electrical stimulation.** Neuromuscular electrical stimulation is an alternative system to increase venous return from the lower limbs. This device stimulates calf muscle contraction through application of an electric current, leading to better emptying of the deep veins. A literature review including 46 studies showed an improvement in venous haemodynamics with stimulation of the calf muscle pump compared with rest.<sup>97</sup> In particular, calf flow, femoral and popliteal peak velocity increased, as well as ejection volume from the lower leg. More recently, neuromuscular electrical stimulation did not demonstrate any effectiveness in reducing lower leg volume<sup>98</sup> and to date, its use in CVD remains very limited.<sup>97</sup>

**3.2.2.3. Tension free compression.** Immersion into water or the application of a pressurised fluid like wrap around

the ankle and calf are forms of tension free compression.<sup>99</sup> The Law of Laplace becomes irrelevant permitting high pressures to be achieved without discomfort or any tension induced skin stress over fulcrum points.<sup>74</sup> Compression by water has been shown to be effective in improving venous haemodynamics,<sup>100,101</sup> and reducing leg volumetry in people with leg oedema.<sup>102,103</sup> Although this type of compression is ideal in theory, current prototypes are experimental and subject of ongoing research.

<b>Recommendation 9</b>		<b>Unchanged</b>	
<b>For patients with symptomatic chronic venous disease, elastic compression stockings, exerting a pressure of at least 15 mmHg at the ankle, are recommended to reduce venous symptoms.</b>			
<b>Class</b>	<b>Level</b>	<b>References</b>	<b>ToE</b>
I	B	Benigni et al. (2003), <sup>75</sup> Kakkos et al. (2018) <sup>76</sup>	

<b>Recommendation 10</b>		<b>Unchanged</b>	
<b>For patients with chronic venous disease and oedema (CEAP clinical class C3), compression treatment, using below knee elastic compression stockings, inelastic bandages or adjustable compression garments, exerting a pressure of 20 – 40 mmHg at the ankle, is recommended to reduce oedema.</b>			
<b>Class</b>	<b>Level</b>	<b>References</b>	<b>ToE</b>
I	B	Mosti et al. (2012), <sup>77</sup> Mosti et al. (2013), <sup>82</sup> Mosti et al. (2015) <sup>79</sup>	

CEAP = Clinical Etiological Anatomical Pathophysiological (classification).

<b>Recommendation 11</b>		<b>New</b>	
<b>For patients with chronic venous disease and lipodermatosclerosis and/or atrophie blanche (CEAP clinical class C4b), using below knee elastic compression stockings, exerting a pressure of 20 – 40 mmHg at the ankle, is recommended to reduce skin induration.</b>			
<b>Class</b>	<b>Level</b>	<b>References</b>	<b>ToE</b>
I	B	Vandongen et al. (2000) <sup>84</sup>	

CEAP = Clinical Etiological Anatomical Pathophysiological (classification).

<b>Recommendation 12</b>		<b>New</b>	
<b>For patients with post-thrombotic syndrome, below knee elastic compression stockings, exerting a pressure of 20 – 40 mmHg at the ankle, should be considered to reduce severity.</b>			
<b>Class</b>	<b>Level</b>	<b>References</b>	<b>ToE</b>
IIa	B	Azizar et al. (2019) <sup>96</sup>	

Recommendation 13				New
For patients with post-thrombotic syndrome, adjuvant intermittent pneumatic compression may be considered to reduce its severity.				
Class	Level	References	ToE	
IIb	B	Azizar <i>et al.</i> (2019) <sup>96</sup>		

### 3.3. Pharmacological treatment

Medical treatment has been used for decades, but there is some controversy over its exact place as a treatment modality for CVD. Venoactive drugs (VADs) are widely prescribed in some countries but are not available in others. They can be classified into two groups: natural and synthetic drugs. The main modes of action of VADs are to decrease capillary permeability, reduce release of inflammatory mediators, or improve venous tone.

A Cochrane review of 53 trials on VADs providing quantifiable data involving 6 013 participants was published in 2016,<sup>104</sup> and updated in 2020.<sup>105</sup> These reviews concluded that, when compared with placebo, VADs may have beneficial effects on objective measures of leg oedema and on some symptoms and signs related to CVD such as pain, cramps, restless legs, sensation of swelling, paraesthesia, and trophic disorders, but can produce more adverse effects and may not affect QoL based on a pooled analysis of the included VADs.<sup>105</sup> Another meta-analysis showed that four VADs reduced the objective clinical sign of oedema in patients with CVD.<sup>106</sup> Table 8 summarises the most important findings on the effect of different VADs on venous symptoms and oedema.

**3.3.1. Ruscus extracts.** A systematic review on Ruscus extracts has identified 10 double blind placebo controlled RCTs involving 719 patients with unilateral or bilateral CVD (CEAP clinical class of affected limbs ranging between C2 and C5).<sup>107</sup> On quantitative analysis, Ruscus extracts significantly improved several leg symptoms, including pain, heaviness, fatigue, feeling of swelling, cramps, paraesthesia, global symptoms, and clinical findings such as ankle circumference and leg/foot volume.

**3.3.2. Micronised purified flavonoid fraction.** A systematic review on micronised purified flavonoid fraction (MPFF) identified seven double blind placebo controlled RCTs involving 1 692 patients.<sup>108</sup> On quantitative analysis, MPFF improved several leg symptoms (Table 8) functional discomfort, QoL, and ankle circumference.

**3.3.3. Calcium dobesilate.** Calcium dobesilate is a synthetic VAD, which had been evaluated in 10 RCTs up to 2004 involving 778 patients included in a meta-analysis.<sup>109</sup> It significantly reduced a number of leg symptoms (Table 8) and discomfort, while lower limb oedema was improved and the investigators' opinions of symptom improvement were positive, albeit with some heterogeneity. Subgroup analysis showed greater improvements in pain, heaviness, paraesthesia, and leg oedema in the group of patients with severe symptoms and signs than in those with milder ones. Four more recent double blind placebo controlled RCTs involving 1 165 patients with CVD also showed improvement of symptoms and objective measures of oedema, again with some heterogeneity.<sup>110–113</sup>

**3.3.4. Horse chestnut extract.** A Cochrane review on horse chestnut extract of 17 RCTs involving 1 593 patients showed that this VAD was effective (Table 8).<sup>114</sup>

**3.3.5. Hydroxyethylrutosides.** A systematic review and meta-analysis of the efficacy of hydroxyethylrutosides for treating symptoms and signs of CVD reported on 15 trials involving 1 643 participants.<sup>115</sup> It showed that hydroxyethylrutosides significantly reduced venous symptoms (Table 8).

**3.3.6. Red vine leaf extract.** The effect of red vine leaf extract has been evaluated in two RCTs involving 260 and 248 patients, respectively.<sup>116,117</sup> Red vine leaf extract reduced CVD related symptoms and lower limb oedema substantially more than placebo, although only pain was reduced in both RCTs (Table 8). A third cross over double blind RCT assessed objective measures of oedema and patient reported global assessment of efficacy, both in favour of red vine leaf extract.<sup>118</sup>

**3.3.7. Sulodexide.** Sulodexide was evaluated by a 2020 meta-analysis, which included 13 studies on 1 901

Table 8. Global summary of the effects of the main venoactive drugs on venous symptoms and oedema							
Symptom or sign	Ruscus extracts <sup>107</sup>	MPFF <sup>108</sup>	Calcium dobesilate <sup>109–113</sup>	Horse chestnut extract <sup>114</sup>	Hydroxyethyl-rutosides <sup>115</sup>	Red vine leaf extract <sup>116–118</sup>	Sulodexide <sup>119</sup>
Pain	+	+	+	+	+	+	+
Heaviness	+	+	+		+		+
Fatigue	+		+				
Feeling of swelling	+	+					+
Cramps	+	+	+		+		+
Paresthesia	+	+	+				
Pruritus			+	+			
Oedema	+	+	+	+		+	

MPFF = micronised purified flavonoid fraction.

participants.<sup>119</sup> Sulodexide decreased the intensity of pain, cramps, heaviness, feeling of swelling (Table 8), and total symptom score, and also reduced inflammatory mediators in patients with CVD.

**3.3.8. Clinical applicability.** Unlike the Cochrane review presented above, which pooled the results of all VADs,<sup>105</sup> the present guidelines used published individual meta-analyses; some of the latter studies used the GRADE approach like Cochrane reviews to quantify the certainty of evidence, a methodology not used by the ESC and the ESVS guidelines, so that some of their findings on certainty of evidence are not applicable herein. Furthermore, based on results of the Cochrane review, it is evident that VADs do help patient symptoms, although MPFF and Ruscus extract VADs were not included there. Given the low cost of VADs and their rare side effects that are usually not severe, VADs at least should be considered for the treatment of symptoms and oedema related to CVD. The GWC has decided to provide a single generic recommendation on VADs, as opposed to individual ones, on the understanding that these agents represent a heterogeneous group. The same class of recommendation as cited in the 2015 edition has been retained, taking into account the latest meta-analyses for MPFF and Ruscus extract.<sup>107,108</sup>

Recommendation 14		Unchanged	
For patients with symptomatic chronic venous disease, who are not undergoing interventional treatment, are awaiting intervention, or have persisting symptoms and/or oedema after intervention, medical treatment with venoactive drugs should be considered to reduce venous symptoms and oedema, based on the available evidence for each individual drug.			
Class	Level	References	ToE
Ila	A	Ciapponi <i>et al.</i> (2004), <sup>109</sup> Kalus <i>et al.</i> (2004), <sup>117</sup> Flota-Cervera <i>et al.</i> (2008), <sup>110</sup> Martinez-Zapata <i>et al.</i> (2008), <sup>111</sup> Rabe <i>et al.</i> (2011), <sup>113</sup> Rabe <i>et al.</i> (2011), <sup>118</sup> Pittler <i>et al.</i> (2012), <sup>114</sup> Aziz <i>et al.</i> (2015), <sup>115</sup> Rabe <i>et al.</i> (2016), <sup>112</sup> Kakkos <i>et al.</i> (2017), <sup>107</sup> Kakkos <i>et al.</i> (2018), <sup>108</sup> Bignamini <i>et al.</i> (2020) <sup>119</sup>	

**3.4. Conservative treatment strategy**

The conservative treatment strategy is summarised in Fig. 6. Patients with symptomatic CVD without active VLU, either not undergoing interventional treatment, awaiting intervention, or with persisting symptoms after intervention may all benefit from conservative treatment. Emerging evidence strengthens the importance of physical exercise and weight reduction in obese patients, to reduce symptoms and prevent progression of CVD.

Compression therapy remains the cornerstone of conservative CVD treatment. It has been proven effective in symptom control and in oedema reduction. It may also be used to reduce skin induration in limbs with

lipodermatosclerosis and/or atrophie blanche (clinical CEAP class C4b). The importance of compression treatment in limbs with healed or active VLU (clinical CEAP class C5 and C6) is discussed further in subsection 6.3. Compression treatment is generally well tolerated even if acceptance by the patients and compliance with treatment may still be an issue.

Compression therapy by inelastic compression devices exerting strong pressure (40 – 60 mmHg) is mainly indicated in the acute clinical stages of oedema, as a result of DVT or VLU. Compression by elastic devices (mainly graduated ECS) exerting low (15 – 20 mmHg) to moderate (20 – 40 mmHg) pressure at the ankle is indicated in chronic stages of CVD, including patients with moderate or severe PTS. The use of below knee ECS to reduce the risk of PTS has been extensively discussed in the ESVS guidelines on venous thrombosis.<sup>2</sup>

An alternative conservative approach consists of the use of VADs, to reduce symptoms and to diminish oedema. When prescribing VADs, the specific therapeutic actions of the different available drugs should be taken into account (Table 8).

In clinical practice, conservative measures may be used alone or in combination, either temporarily or for a longer period of time, as part of a shared decision between practitioner and patient. Such an individualised approach will also depend on local circumstances and available healthcare resources.

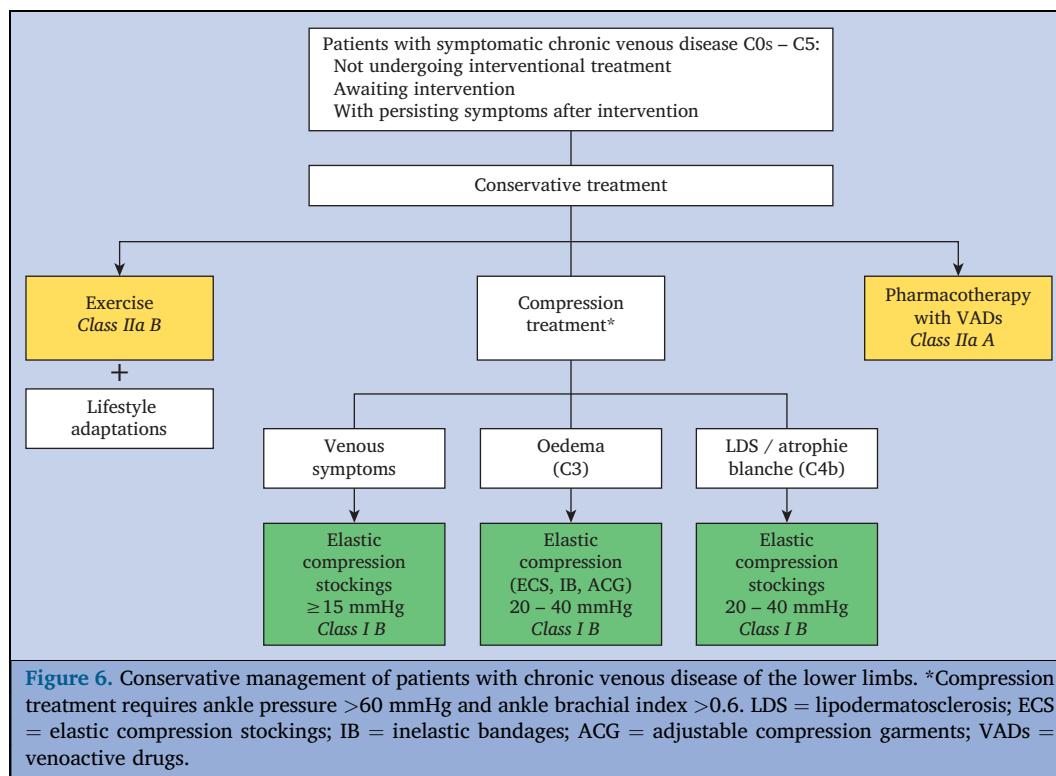
**4. INTERVENTIONS FOR SUPERFICIAL VENOUS INCOMPETENCE**

This chapter deals with the different interventions available for treating CVD patients with incompetent superficial veins (i.e. with reflux lasting > 0.5 seconds on DUS), including saphenous trunks, tributaries, reticular veins, and telangiectasias, and their management strategies. Techniques for treating incompetent PVs and their management are also addressed in this chapter.

**4.1. General principles**

**4.1.1. Indications for treatment.** In CVD patients with superficial venous incompetence, management strategies mainly depend on clinical presentation (history, symptoms, signs) and detailed individual DUS findings, which are all mandatory for proper decision making. In addition, the negative impact of CVD on QoL should be considered. Many studies have shown the beneficial effect of intervention on venous symptoms, as well as on disease specific and generic QoL, not only in CVD patients presenting with skin changes (CEAP clinical class C4 – C6), but also in those with VVs only.<sup>120,121</sup> In the REACTIV trial, a group of 246 patients with symptomatic uncomplicated VVs (CEAP clinical class C2 – C3) were randomised between surgical intervention and conservative treatment, consisting of lifestyle advice and ECS. In the first two years after treatment there was a significant QoL benefit for surgery, based on the EQ-5D score. Significant benefits were also seen in symptomatic





and anatomical measures.<sup>122</sup> Further analysis showed the cost effectiveness of surgery *versus* ECS in these patients with uncomplicated VVs.<sup>123</sup> A more recent investigation into the cost effectiveness of interventional treatment for VVs in the UK National Health Service similarly concluded that interventional treatment for VVs is cost effective, with endovenous thermal ablation (EVTA) being the most cost effective for those patients for whom it is suitable.<sup>124</sup> Another review suggested that surgery and the minimally invasive techniques are similar in terms of efficacy or safety, so the relative cost of the treatments becomes one of the deciding factors.<sup>125</sup> However, the investigators noted that high quality RCT evidence is required. It is therefore obvious that the above findings may not be applicable to all patients worldwide, as cost effectiveness largely depends on the local resources and healthcare situation.

Although the natural history of the disease has not been extensively investigated in CVD patients, long term follow up data of the Edinburgh Vein Study (after 13 years) clearly revealed disease progression, with one third of patients with isolated VVs at baseline developing skin changes (see subsection 1.1).<sup>11</sup> Based on all these findings, interventional treatment for patients with symptomatic uncomplicated VVs resulting from superficial venous incompetence (CEAP clinical class C2<sub>s</sub>) is justified.

For CVD patients presenting with oedema (CEAP clinical class C3), without clinically evident VVs, it is less clear whether they require treatment for superficial venous incompetence, as oedema, certainly if bilateral, may be multifactorial, with several coexisting causes of oedema, not related to venous disease and hence non-responsive to venous intervention. Therefore, other non-venous causes of

oedema should be considered before planning interventional treatment of venous incompetence. On the other hand, patients presenting with symptomatic VVs and oedema (CEAP clinical Class C2,3<sub>s</sub>) may be more likely to benefit from superficial venous intervention, with reduction of oedema after the procedure. In general, unilateral limb swelling is considered a better predictor for a favourable response than bilateral oedema.<sup>126</sup>

For CVD patients presenting with skin changes (CEAP clinical class C4 – C6), there is consensus that treatment of superficial venous incompetence is indicated and constitutes an appropriate use of healthcare resources.<sup>126</sup> Whereas the beneficial effect of reflux ablation on ulcer healing has been clearly proven (see Chapter 6), only limited (empirical) data are available concerning the effect of superficial venous intervention on other skin changes.

For patients with reticular veins and/or telangiectasias (CEAP clinical class C1) and/or VVs with mainly cosmetic concerns, intervention is not mandated. Before intervention is performed, thorough information should be given about the low risk of serious complications of CVD, and the risk profiles and costs of different treatments, as part of a shared decision making process.

Whether treatment is “required” and which management strategy to be preferred will depend on individual patient characteristics as well. For example, patients with a high body mass index (BMI), extensive comorbidities, on anti-coagulant treatment, etc., may need special attention when planning treatment.<sup>127</sup> These special patient characteristics are further addressed in subsection 8.2.

In summary, clinical assessment, DUS findings, and individual patient related factors remain the basis for



individualised treatment. When defining the treatment strategy for patients with CVD, physicians should also take into account patient preference, as well as the expected impact on QoL, the estimated risk of deterioration of CVD and local healthcare resources, which determine the available interventional options.<sup>127</sup> The risks specific to each modality should also be discussed with the patient prior to any intervention.<sup>128</sup>

Recommendation 15			New
For patients with superficial venous incompetence presenting with symptomatic varicose veins (CEAP clinical class C2 <sub>s</sub> ), interventional treatment is recommended.			
Class	Level	References	ToE
I	B	Michaels <i>et al.</i> (2006) <sup>122</sup>	

CEAP = Clinical Etiological Anatomical Pathophysiological (classification).

Recommendation 16			New
For patients with superficial venous incompetence, presenting with oedema (CEAP clinical class C3), other non-venous causes of oedema should be considered before planning interventional treatment.			
Class	Level	References	ToE
IIa	C	Consensus	

CEAP = Clinical Etiological Anatomical Pathophysiological (classification).

Recommendation 17			New
For patients with superficial venous incompetence, presenting with skin changes as a result of chronic venous disease (CEAP clinical class C4 – C6), interventional treatment of venous incompetence is recommended.			
Class	Level	References	ToE
I	C	Consensus	

CEAP = Clinical Etiological Anatomical Pathophysiological (classification).

**4.1.2. Setting.** Historically, superficial venous incompetence has been treated by open surgical repair, typically performed in an operating room, under general or regional anaesthesia. Endovenous intervention, with or without phlebectomies, is now widely acknowledged as the established standard of care and ideally should be performed in the ambulatory setting, in a properly equipped treatment room.<sup>129</sup> Observational data suggest that this practice is safe and effective, offering a reduction in procedural cost.<sup>130,131</sup> Indeed, ambulatory intervention, using tumescent anaesthesia, permits a comprehensive treatment strategy addressing both saphenous trunk and tributary

incompetence. In addition, early ambulation may reduce thromboembolic risk. Therefore, in those with straightforward saphenous anatomy according to DUS, ambulatory endovenous ablation with adjunctive phlebectomies (where applicable), is advocated in the initial management of superficial venous incompetence.

Recommendation 18			New
For patients with superficial venous incompetence, undergoing treatment using endovenous techniques with or without phlebectomies, the procedures should be performed in the outpatient setting where possible.			
Class	Level	References	ToE
I	C	Consensus	

**4.1.3. Anaesthesia.** Tumescent anaesthesia, performed under ultrasound guidance, is the preferred anaesthesia for EVTA and has also been used in recent RCTs, comparing EVTA with open GSV surgery.<sup>132–134</sup> It allows early return to normal function and significant improvements in QoL.<sup>133</sup> Tumescent anaesthesia reduces pain, induces venous compression and spasm leading to greater effectiveness, and acts as a heat sink to protect surrounding structures.

A standardised tumescent composition has been described,<sup>135</sup> consisting of 445 mL crystalloid, 50 mL 1% lidocaine plus 1:100 000 adrenaline and 5 mL 8.4% sodium bicarbonate, with the latter offering a reduction in the burning sensation associated with injection.<sup>136</sup> Lidocaine doses up to 15 mg/kg, as used in tumescent anaesthesia solutions, have been associated with a minimal side effect profile, with toxicity seen in 36% of those dosed at 35 mg/kg.<sup>137</sup> Recent RCT data have identified reduced pain when the pH of acidic lidocaine solutions is neutralised by the addition of sodium bicarbonate, to create buffered solutions.<sup>138</sup> Moreover, the addition of adrenaline prolongs the anaesthetic effect and provides a vasoconstrictive effect. Finally, the practitioner should be aware that a range of formulations might not comply with the local regulations of some countries.<sup>139</sup> In general, additives should be limited to what is useful and relevant for venous treatments.

General and regional anaesthesia are now largely reserved for those undergoing open surgical interventions, those with very extensive tributary or PV disease and those requiring concomitant deep venous intervention. Nonetheless, contemporary open surgery, using tumescent anaesthesia, has been described increasingly.<sup>132–134</sup>

Recommendation 19			New
For patients with superficial venous incompetence treated by endovenous thermal ablation, ultrasound guided tumescent anaesthesia is recommended.			
Class	Level	References	ToE
I	C	Consensus	

Recommendation 20			New
For patients with superficial venous incompetence treated under tumescent anaesthesia, buffered solutions should be considered to reduce peri-procedural pain.			
Class	Level	References	ToE
IIa	B	Nandhra et al. (2018) <sup>138</sup>	

Recommendation 21			Changed
For patients with superficial venous incompetence undergoing high ligation/stripping, ultrasound guided tumescent anaesthesia may be considered, as an alternative to general or regional anaesthesia.			
Class	Level	References	ToE
IIb	C	Consensus	

**4.1.4. Cannulation and other technical considerations.** For EVTA and all non-thermal ablation techniques, cannulation of incompetent saphenous trunks is performed under ultrasound guidance in a standardised way – with the probe in either longitudinal or transverse orientation,<sup>140</sup> using a 4 to 7 Fr introducer kit, depending on the device used. Cannulation prior to the administration of tumescence, can be facilitated using a reverse Trendelenburg position and a small volume of local lidocaine. Special considerations include intraluminal obstacles, such as fibrotic scars of previous SVT or thickened valves, encountered while navigating the laser fibre or catheter in truncal veins. These may be overcome using additional manoeuvres and, if needed, multilevel catheter access and over the wire ablation systems.<sup>141</sup> For thermal ablation procedures, access is usually gained to the most distal incompetent segment, if located above midcalf.<sup>142</sup> The access point can be more distal for non-thermal ablation, as the risk of neurological injury is almost absent with these techniques. Access to the saphenous trunk can sometimes be facilitated by cannulating a superficial tributary.

Sclerotherapy can be performed through a needle, a cannula, a butterfly needle, or a long catheter. Several injection methods can be applied, without any evidence of superiority of one over the other.<sup>143</sup> Details are further discussed in subsection 4.2.2.2.

**4.1.5. Compression after treatment.** Compression therapy following superficial venous intervention remains a controversial issue, particularly with regard to the indications for and benefits of therapy. Nevertheless, it is still used by the vast majority of surgeons.<sup>144</sup>

The rationale for compression following venous treatments is to establish luminal compression of the treated vein or of the area where veins have been removed (by stripping or phlebectomy), to prevent or minimise inflammation, pain, bruising, bleeding, haematoma, and superficial or deep vein thrombosis.<sup>145,146</sup> However, to compress the GSV effectively at thigh level, compression of > 40 mmHg is necessary in the

standing position.<sup>147</sup> This is nearly impossible to achieve with ECS alone, but it is possible when the stocking is applied on top of an eccentric compression pad, placed directly over the ablated or surgically removed vein. In a small RCT, applying a thigh length ECS with 35 mmHg ankle pressure, placed on top of eccentric pads on the treatment area, was more effective in reducing post-procedural side effects than a 23 mmHg ECS.<sup>148</sup>

There is conflicting evidence from several RCTs comparing compression with no compression after both EVTA and ultrasound guided foam sclerotherapy (UGFS) of saphenous trunks.<sup>149–152</sup> Additionally, the interpretation and comparison of trials is difficult because of heterogeneity in modality and the degree of compression applied, variations in the duration of compression, and incomplete reporting of compression therapy compliance. In the largest trial, randomising 400 patients, undergoing endovenous laser ablation (EVLA) of the GSV, between ECS exerting 23–32 mmHg and no compression, early results were beneficial for ECS. In the first week after EVLA, patients in the ECS group experienced less pain ( $p < .001$ ) and oedema ( $p = .010$ ), but by two weeks these variables were similar between the groups.<sup>150</sup>

Concomitant treatment of varicose tributaries may be taken into account when deciding whether or not to offer post-procedure compression. According to the COMETA trial, wearing compression stockings after EVTA was beneficial, with better pain scores during the first week, and especially for those having concurrent phlebectomies,<sup>151</sup> while another study, where radiofrequency ablation (RFA) and concomitant UGFS of tributaries was performed, reported the opposite results.<sup>153</sup> Based on clinical experience, eccentric compression at the sites of tributary treatment may be useful, even if its use has not been specifically investigated.

Duration of post-procedure compression is also controversial and is mainly left to the clinical judgement of the treating physician.<sup>154</sup> Based on a meta-analysis including five RCTs (775 patients) examining compression durations ranging from 24 hours to two weeks, compression for at least one week was recommended by the authors following EVTA.<sup>155</sup> This confirmed the findings of a previous meta-analysis, where compression for 3 – 10 days showed the same benefit as compression for a longer duration.<sup>146</sup>

Recommendation 22			Changed
For patients with superficial venous incompetence undergoing ultrasound guided foam sclerotherapy or endovenous thermal ablation of a saphenous trunk, post-procedural compression treatment should be considered.			
Class	Level	References	ToE
IIa	A	Hamel-Desnos et al. (2010), <sup>149</sup> Cavezzi et al. (2019), <sup>148</sup> Bootun et al. (2021), <sup>151</sup> Chou et al. (2019), <sup>155</sup> Pihlaja et al. (2020), <sup>153</sup> Onwudike et al. (2020) <sup>152</sup>	

Recommendation 23		Unchanged	
For patients with superficial venous incompetence undergoing stripping and/or extensive phlebectomies, immediate post-procedural compression treatment is recommended.			
Class	Level	References	ToE
I	A	Huang <i>et al.</i> (2013), <sup>146</sup> Bootun <i>et al.</i> (2021) <sup>151</sup>	

Recommendation 24		New	
For patients with superficial venous incompetence undergoing intervention, the duration of post-intervention compression, used to minimise post-operative local complications, should be decided on an individual basis.			
Class	Level	References	ToE
I	A	Huang <i>et al.</i> (2013), <sup>146</sup> Chou <i>et al.</i> (2019) <sup>155</sup>	

**4.1.6. Thromboprophylaxis.** Significant variations in thromboprophylaxis practice exist with sparse supportive data. While many clinicians administer a single dose of prophylactic low molecular weight heparin (LMWH) to all patients peri-operatively, this practice is not supported by the evidence to date. One RCT evaluating 2 196 patients undergoing open GSV surgery followed by no prophylaxis, subcutaneous unfractionated heparin (UFH) or LMWH (either 6 000 international units [IU] once a day or 4 000 IU twice daily) for three days post-operatively reported lower rates of ultrasound detected DVT within 30 days of intervention in those receiving prophylaxis.<sup>156</sup> The reported rates of DVT were 5.17% in the no prophylaxis group compared with 0.56% in the UFH group and 0.35% (6 000 IU once daily) or 0.36% (4 000 IU twice daily) in the LMWH cohort. The majority of DVTs described were located in the POPV, with more proximal DVTs identified only in the group receiving no prophylaxis. Notably, haemorrhagic complications were higher (0.75%) in the UFH group alone. The benefit of thromboprophylaxis after HLS was not seen in a smaller RCT assessing moderate-risk patients randomised to compression and early ambulation with or without 10 days of LMWH (bemiparin 2 500 IU or 3 500 IU once a day).<sup>157</sup> High risk patients (e.g., previous DVT, family history of venous thromboembolism [VTE], known thrombophilia, obesity, neoplasia, concomitant interventions, elevated pre-operative inflammatory markers [C reactive protein and D dimer]) benefit from prophylaxis during the 7–10 post-operative days, based on individual risk assessment.<sup>158–160</sup> In contrast there is little evidence to support prophylaxis in the low risk cohort undergoing endovenous ablation. Routine thromboprophylaxis may expose this cohort to potentially unnecessary side effects. In a UK and Ireland survey, vascular surgeons agreed that thromboprophylaxis with LMWH should be given to patients with increased VTE risk for one to two weeks rather than a single dose.<sup>161</sup> In view of the paucity of available data, no specific dose regimens can be recommended for LMWH prophylaxis in

superficial vein treatment. Direct oral anticoagulants (DOACs) are increasingly prescribed for peri-procedural thromboprophylaxis given their convenience compared with LMWH.<sup>162</sup> Early retrospective evidence suggests they are effective and safe.<sup>162,163</sup> However, comparative data with LMWH are yet to be established. For all patients early ambulation and compression hosiery may further reduce thrombotic risk.

Recommendation 25		New	
For patients with superficial venous incompetence undergoing intervention, risk assessment for venous thromboembolism is recommended.			
Class	Level	References	ToE
I	C	Consensus	

Recommendation 26		New	
For patients with superficial venous incompetence undergoing intervention, individualised thromboprophylaxis strategies should be considered.			
Class	Level	References	ToE
Ia	B	San Norberto <i>et al.</i> (2013), <sup>157</sup> Wang <i>et al.</i> (2015) <sup>156</sup>	

**4.1.7. Surveillance.** After initial “one stop” treatment (such as endovenous ablation or surgery) it is common practice to perform DUS surveillance of the treated vein(s) one to four weeks after treatment, to check whether the intervention has achieved the intended immediate goal and to check for absence of post-operative DVT.<sup>16</sup> For patients undergoing sequential treatments, such as staged sclerotherapy, or other combined treatments in different steps, interval DUS is performed before the subsequent treatment stage.<sup>164</sup> For most patients, repeat DUS assessment is required only for suspected clinical recurrence.

Recommendation 27		New	
For patients with superficial venous incompetence undergoing treatment of a saphenous trunk, duplex ultrasound surveillance should be considered one to four weeks after treatment.			
Class	Level	References	ToE
Ia	C	Consensus	

**4.1.8. Safety and environmental sustainability issues.** Venous interventions are well tolerated and undertaken increasingly often in the ambulatory setting. Indeed, endovenous strategies now offer effective treatment even in the frail and elderly.<sup>165</sup> Both ablative and open techniques are largely associated with a limited side effect profile, but are not completely without risk.<sup>128</sup> These risks are further described in subsection 4.2. As such, careful pre-operative risk assessment, to aid stratification, should be

undertaken on an individual basis to determine optimal management strategies.

Transition of care from operating rooms to outpatient based environments has the potential to further reduce the resource demand associated with venous intervention. Furthermore, environmental sustainability could potentially be enhanced by described experimental reprocessed multi-use catheters.<sup>166</sup>

## 4.2. Techniques for saphenous ablation

As a minimally invasive alternative to classical surgery (HLS), endovenous techniques are becoming increasingly popular for treatment of saphenous vein incompetence. In countries where reimbursement is available, the vast majority of patients are treated using endovenous modalities. The two most commonly used EVTA techniques are EVLA and RFA. Non-thermal endovenous techniques are UGFS, mechanochemical ablation (MOCA), and catheter directed injection of cyanoacrylate glue, known as cyanoacrylate adhesive closure (CAC).

As the vast majority of RCTs and observational studies on the different endovenous ablation techniques have been performed in patients with GSV incompetence, this subsection mainly reports the available evidence for the different techniques, when used for GSV ablation.

### 4.2.1. Thermal ablation

**4.2.1.1. General considerations.** The use of EVTA techniques requires injection of tumescent liquid around the target vein (see subsection 4.1.3). The technique is similar for all EVTA methods. The whole procedure is performed with DUS guidance. A laser fibre or RFA catheter is inserted percutaneously, although a bailout venous cutdown rarely may be required. Following successful cannulation, the catheter is advanced through an introducer sheath along the course of the vein to be treated and positioned distal to the SFJ or SPJ. Then tumescent anaesthesia solution is injected around the saphenous vein under ultrasound guidance. It is important to empty the vein as much as possible before starting ablation. While withdrawing the catheter or fibre, energy is emitted intraluminally with the intention of causing irreversible thermal damage to the vein wall.

**4.2.1.2. Endovenous laser ablation.** Initially bare tip laser fibres, emitting laser light with relatively low wavelengths (between 810 nm and 1 064 nm) were used for EVLA. More recently, higher laser wavelengths have been introduced and fibre tips with different configuration (radial emission, jacketed tip, tulip tip) have been developed to increase efficacy and reduce potential side effects and complications of EVLA. In higher wavelength lasers (1 320, 1 470, 1 500, 1 920, 1 940 nm) the absorption coefficient of water in the vessel wall is higher than it is with lower wavelengths, targeting haemoglobin. Therefore, with higher wavelength lasers, absorption of the energy by the venous wall is better,

minimising post-operative inflammatory pain and bruising, and also endothermal heat induced thrombosis (EHIT).<sup>167</sup> Five RCTs comparing 980 nm with 1 470 nm fibre reported that the higher wavelength was associated with comparable occlusion rates, and less post-operative pain and complications including bruising, paresthesia, and induration.<sup>168–172</sup> A recent meta-analysis of 28 RCTs (2 829 GSV ablation procedures) investigated the efficacy of EVLA and potential differences in anatomical success rate in relation to variations in wavelength (short, 810 – 980 nm vs. long, 1470 – 1920 nm), administered energy ( $\leq 50$  J/cm vs.  $> 50$  J/cm), outcome definition (occlusion vs. no reflux), and follow up period ( $\leq 1$  year vs.  $> 1$  year). There were no statistically significant differences for these different parameters. In this analysis, the overall success rate of EVLA was 92%.<sup>173</sup>

Apart from recanalisation, frequent sources of recurrent reflux after EVLA are residual or newly developed reflux in SFJ tributaries and accessory veins, in particular the AASV.<sup>134,174–177</sup> To prevent this, the so called laser cross-ectomy or flush EVLA (fEVLA) has been proposed. In such a procedure the fibre tip is positioned exactly at the SFJ, before starting the ablation. A retrospective study reported that fEVLA using a radial fibre is feasible (94.1% technical success) and safe (procedure derived thrombotic complication rate 1.6%, including EHIT), with occlusion rates of 94.5% at six weeks follow up.<sup>178</sup> For the moment, RCT data looking at feasibility, safety, and long term results of fEVLA are still lacking.

**4.2.1.3. Radiofrequency ablation.** At present, the most commonly used RFA system is the radiofrequency segmental thermal ablation, which sequentially heats target vein segments of 7 cm (or shorter) at a temperature of 120 °C. In a multicentre European cohort study, including 295 limbs, a GSV occlusion rate of 92% and a reflux free rate of 95% at five years, with significant VCSS improvement, was reported.<sup>179</sup> In the Varico 2 Study, comparing segmental RFA with 1 470 nm EVLA using radial tip fibres, the occlusion rate was similar in both groups, 96% and 97%, respectively ( $p = .81$ ).<sup>180</sup> There was no difference in post-operative pain scores and the median time to return to work was one day. In both groups VCSS and AVVQ improved greatly, with a durable result at five years. In most studies, the rate of post-procedural complications after RFA was very low, with rare thrombotic events (0.3% DVT), occurring at a similar rate to those after EVLA.<sup>181</sup>

In addition to segmental thermal ablation, other radiofrequency technologies are available, such as radiofrequency induced thermal therapy (RFITT) and endovenous radiofrequency. In the 3-RF trial, 180 patients were randomised between three RFA techniques. At six months, complete GSV occlusion was better after segmental RFA and RFITT (100% and 98%, respectively) than after endovenous radiofrequency treatment (79%,  $p < .001$ ).<sup>182</sup> Currently,



long term results of RFITT and other RFA devices are not available.

**4.2.1.4. Other thermal ablation techniques.** Endovenous steam ablation (EVSA) and endovenous microwave ablation (EVMA) are two alternative EVTA techniques, with limited data in the literature. In a non-inferiority RCT on 227 legs with GSV incompetence (EVSA  $n = 117$ ; 940 nm EVLA  $n = 110$ ), both EVTA techniques produced comparable results with respect to treatment success (vein occlusion or abolition of reflux) at one year (92% for high dose EVSA and 96% for EVLA).<sup>183</sup> In a small prospective multicentre study, the occlusion rate was 96% at six months after EVSA. The intervention was well tolerated without major complications.<sup>184</sup> More data are needed to understand the mid and long term outcomes after EVSA.

The other alternative technique, EVMA, uses dielectric hysteresis to produce direct volume heating of the vein wall. Two studies, one RCT comparing EVMA plus SFJ ligation with HLS,<sup>185</sup> and a retrospective study comparing EVMA with EVLA,<sup>186</sup> showed slightly higher short and midterm occlusion rates in favour of EVMA, without serious complications.

**4.2.1.5. Complications of endovenous thermal ablation.** The risk of VTE after EVTA is low. Several studies investigated a special form of thrombotic complication, called EHIT. This term describes thrombus at the SFJ or SPJ, after EVTA. EHIT thrombus is the result of thermomechanical damage and coagulation effects and has a particular hyperechoic sonographic appearance.<sup>187</sup> Three earlier classifications of EHIT have been unified in the American Venous Forum EHIT classification (Table 9).<sup>188</sup>

A systematic review and meta-analysis found that GSV EVTA was complicated by EHIT in 1.7% (95% CI 0.9 – 2.7%), including EHIT class II, III, or IV in 1.4% (95% CI 0.8 – 2.3%), by DVT in 0.3% (95% CI 0.2 – 0.5%), and by PE in 0.1% (95% CI 0.1 – 0.2%), with similar results when the RFA and EVLA groups were analysed separately.<sup>181</sup> The clinical significance of EHIT remains unclear, and consequently pharmacological

thromboprophylaxis also remains uncertain. Even though thrombus extension may lead to occlusive DVT, emboli are rare and spontaneous regression is observed after ultrasound observation alone or with a short course of LMWH.<sup>189</sup> When thrombus occludes the CFV (EHIT class IV), treatment by therapeutic anticoagulation is recommended.<sup>190–192</sup>

Other reported complications after EVTA are SVT, hyperpigmentation, paresthesia, haematoma, and, exceptionally, thermal skin injury. All these have become increasingly rare with the use of water targeting lasers with a wavelength of  $\geq 1470$  nm,<sup>193</sup> and most can be avoided using a proper technique and detailed ultrasound guidance.<sup>194</sup> If the saphenous trunk is situated very close to the skin ( $\leq 5$  mm), post-operative inflammation, hyperpigmentation, and induration after EVTA may be more pronounced and an alternative approach may be warranted exceptionally (see subsection 4.6.8.2). Compared with EVTA, surgically treated patients develop certain complications such as wound infection and haematoma more often, have more intra-operative blood loss, and require a longer operation time.<sup>195</sup> Sensory disturbances are also less common after EVLA compared with surgery.<sup>196</sup> Patients treated with EVTA have less pain and swelling than patients treated surgically.<sup>197,198</sup> This results in quicker recovery and faster return to normal activities.<sup>197,199</sup>

**4.2.1.6. Duplex ultrasound and clinical long term follow up.**

For EVTA, several long term result reports of RCTs comparing EVLA and/or RFA with HLS or UGFS, with a follow up of at least five years after GSV treatment, have been published.<sup>200</sup> In a meta-analysis, three RCTs and 10 RCT follow up studies were included and data were pooled to determine anatomical success as primary outcome.<sup>201</sup> The pooled anatomical success rate was 88% (95% CI 82 – 92%) after EVLA versus 83% (95% CI 72 – 90%) after HLS and 34% (95% CI 26 – 44%) after UGFS. Compared with HLS, most studies reported no statistically significant difference in VV recurrence (clinical) or recurrent reflux (according to DUS) after treatment.<sup>134,202,203</sup> However, the anatomical site of the recurrent VVs appeared to be different: after five years clinical “same site” recurrence was more frequent after EVLA, whereas “different site” recurrence occurred more frequently after HLS.<sup>134</sup> A meta-analysis including 11 RCTs, reported a statistically significantly lower recurrence rate after EVLA than after high ligation (3.1% after EVLA vs. 10% after HLS; OR 0.28 [95% CI 0.16 – 0.49]  $p < .001$ ).<sup>195</sup> Comparing EVLA with RFA, a meta-analysis demonstrated that both have the same safety, efficacy, post-operative pain score, and recanalisation rates.<sup>204</sup>

According to two systematic reviews and meta-analyses, recanalisation was the most common cause of recurrence after EVLA, whereas neovascularisation was more frequent after HLS.<sup>177,202</sup>

**Table 9. American Venous Forum endothermal heat induced thrombosis (EHIT) classification<sup>188</sup>**

Class	Definition
I	Thrombus without propagation into the deep vein a. Peripheral to superficial epigastric vein b. Central to superficial epigastric vein, up to and including the deep vein junction
II	Thrombus propagation into the adjacent deep vein but comprising < 50% of the deep vein lumen
III	Thrombus propagation into the adjacent deep vein but comprising > 50% of the deep vein lumen
IV	Occlusive deep vein thrombus contiguous with the treated superficial vein



**4.2.1.7. Quality of life.** Patients treated using endovenous interventions seem to have an equal,<sup>134,199,203</sup> or better,<sup>196</sup> QoL after treatment compared with HLS. In the long term, there was no difference in the relief of venous symptoms, clinical evolution or generic QoL when EVTA was compared with “modern open surgery” performed under local tumescent anaesthesia.<sup>132,134</sup> A meta-analysis demonstrated that EVLA and RFA had the same QoL at one and 12 months follow up.<sup>204</sup> Compared with UGFS, QoL five years after treatment was better with EVLA.<sup>129</sup>

**4.2.1.8. Choosing a thermal ablation device.** A meta-analysis including pooled data of 28 RCTs with EVLA in one or two of the treatment arms, showed that different commonly used EVLA parameters did not influence the efficacy of the treatment.<sup>173</sup> In the absence of large, properly powered RCTs comparing the various ablation device types for differences in the long term anatomical success rate, the GWC cannot make any recommendation regarding the optimum device type. This is left to the discretion of the treating physician and may also depend on local availability and experience.

## 4.2.2. Non-thermal ablation

**4.2.2.1. Cyanoacrylate glue ablation.** Catheter directed CAC is a non-thermal, non-tumescent alternative to EVTA techniques to occlude incompetent superficial veins of the lower limbs. Upon intravenous injection, cyanoacrylate rapidly solidifies via a polymerisation reaction and produces an inflammatory reaction of the vein wall. Currently, at least three types of cyanoacrylate vein adhesive devices are commercially available for superficial vein incompetence treatment. The main difference between these devices relates to the cyanoacrylate formulation and application techniques.

Several studies have shown that CAC is safe and effective to ablate the incompetent GSV, with cumulative occlusion rates comparable with those for EVTA in the early and midterm observations, up to three years follow up.<sup>205–213</sup> The WAVES study further demonstrated the efficacy of CAC for SSV, AASV, and large GSV (maximum diameter up to 20 mm), with an occlusion rate of 98%,<sup>210</sup> although according to another study, a mean GSV diameter > 8 mm appeared to be a statistically significant predictor of recanalisation ( $p < .021$ ).<sup>207</sup> An increased GSV diameter was also associated with a longer stump remnant.<sup>214</sup>

A few RCTs have compared CAC with EVTA.<sup>206,208,211</sup> The VeClose multicentre RCT showed that CAC is non-inferior to RFA. In 222 patients with GSV reflux, the 36 month occlusion rates were 94.4% for CAC and 91.9% for RFA, both with a stable improvement in QoL.<sup>211</sup> The five year extension study of this RCT still showed an occlusion rate of 93.6 % in 47 patients (43.5%) of the CAC group reaching 60 months follow up, without serious adverse events.<sup>215</sup> Another RCT compared CAC with EVLA in 400 patients with GSV

incompetence and at 12 months, complete occlusion was found in 96.6% and 94.1%, respectively.<sup>206</sup> Another RCT compared CAC with EVLA and RFA in 525 patients and demonstrated 24 month occlusion rates of 94.7%, 90.9%, and 91.5% after CAC, RFA, and EVLA, respectively.<sup>208</sup> Several systematic reviews and meta-analyses have shown no statistically significant difference in technical success rates when CAC was compared with EVTA techniques.<sup>209,213</sup>

The r-VCSS and QoL measures improved statistically significantly after CAC in all studies, with no statistical difference between EVTA techniques and CAC in comparative studies, with an exception of one RCT in which r-VCSS scores were statistically significantly lower at six months and two years in the CAC group ( $p < .001$ ).<sup>208</sup> Pain during the CAC intervention was significantly less and CAC treatment time and recovery time were considerably shorter than after EVTA.<sup>206,208,209</sup>

Post-operative complications after CAC are limited.<sup>205–213</sup> The most common adverse event is a local inflammatory reaction of the skin and subcutaneous area overlying the treated vein, in most studies described as “phlebitis” (0.5% – 20%), which potentially can be related to a local hypersensitivity reaction to the cyanoacrylate injection. It is mostly transient, benign, and self limiting. In recent literature a rate of hypersensitivity reaction to cyanoacrylate of 6% – 7 % has been suggested (mild 4.2%, moderate 1.3%, and severe 0.3%),<sup>213,216</sup> and known hypersensitivity to acrylate should be considered a contraindication to CAC treatment.<sup>217</sup> Despite the large number of cases performed worldwide, only a few late granulomatous reactions have been reported, some of them with considerable morbidity. Further registration and adequate follow up of these rare cases are required, as late adverse reactions may occur even up to one year post-operatively.<sup>217</sup> Other complications include DVT (0% – 3.5%), cyanoacrylate protrusion into the SFJ or endovenous glue induced thrombosis (1.4% – 5.8%), hyperpigmentation (1.6% – 3%), access site infection or cellulitis (1.4% – 3%), haematoma (1.4% – 1.6%), and nerve injury or paresthesia (0% – 2%).<sup>212,213,218</sup>

**4.2.2.2. Foam sclerotherapy.** Sclerotherapy is a chemical endovenous ablation technique, consisting of injecting a sclerosing agent into a target vein to damage its wall and obtain a durable vein fibrosis. The most commonly used sclerosing agents are polidocanol (POL) and sodium tetradecyl sulphate (STS), which both can be used in foam or liquid form. Sclerotherapy can be used in truncal veins as well as tributary VVs. Foam has been shown to be at least twice as effective as liquid, with four or five times less sclerosing agent needed.<sup>219</sup> To increase efficacy and safety of sclerotherapy, ultrasound guidance should be used during the whole procedure for non-clinically visible VVs. One of the most important safety issues is to avoid inadvertent intra-arterial sclerosant injection.<sup>220</sup>

In long term follow up of comparative studies, treatment of incompetent saphenous veins by UGFS has shown to be substantially less effective than EVLA, RFA, and surgery in terms of occlusion or absence rates. In one RCT, the rate of anatomical success (GSV occlusion or absence) according to DUS was 64%, 75.9%, and 33.3% after EVLA, surgery, and UGFS, respectively,<sup>129</sup> and in another study, 85%, 77%, and 23%, respectively ( $p < .001$ ).<sup>203</sup> A four arm trial compared UGFS with RFA, EVLA, and surgery  $< .001$  after three years follow up failure was found in 7%, 6.8%, 6.5%, and 26.4% after RFA, EVLA, surgery, and UGFS ( $p < .001$ ), respectively.<sup>175</sup> It should be noted that the UGFS treatment protocol for the GSV, used in these trials, was not always optimal, for example performing a single injection of foam just above the knee instead of staged injections along the length of the vein, from proximal to distal, as recommended in the European guidelines for sclerotherapy.<sup>143</sup>

A lower efficacy has been reported in patients with a GSV  $> 6$  mm than in those with a GSV  $< 6$  mm (measured at mid thigh, in standing position). A *post hoc* analysis of 225 patients treated with UGFS, being part of a RCT comparing HLS with UGFS, showed a two year cumulative probability of recurrent reflux of 62.6% (51.2% – 74.2%) if the mid thigh GSV diameter was  $> 6$  mm *versus* 42% (34.6% – 50.4%) for a diameter  $< 6$  mm.<sup>221</sup> Therefore, UGFS should be preferably used for less dilated GSV or SSV trunks.<sup>164,221,222</sup>

Disease specific QoL scores improved significantly after UGFS with no difference between UGFS and other methods of saphenous trunk treatment up to three years in a four arm RCT,<sup>175</sup> and, in a single centre prospective study, with more than five years follow up.<sup>223</sup> Other trials showed that initial QoL improvement reduced over time and was significantly worse at five years after treatment in patients with initial UGFS compared with patients treated by EVTA ( $p = .013$ ).<sup>129,203</sup>

Foam sclerotherapy is the technique of choice for anatomical configurations that make endovenous cannulation or advancing the ablation device challenging (see subsection 4.6.8.3) and is suitable for treating tortuous recurrent VVs (see subsection 4.7.3).

An alternative to the classical UGFS (by means of direct puncture or a short cannula) and other non-thermal ablation techniques for treatment of incompetent saphenous veins is catheter directed foam sclerotherapy (CDFFS) with or without peri-saphenous tumescence infiltration to reduce the vein calibre. When performing CDFFS, sclerosant foam is injected through a long (30 – 40 cm) intravenous catheter all along the saphenous trunk under ultrasound visualisation.<sup>224,225</sup> A systematic review and meta-analysis of 3 689 patients showed a higher occlusion rate of 82.4% after CDFFS and 62.9% after UGFS ( $p < .001$ ) at three year follow up.<sup>224</sup> The rate of major complications and the frequency of post-procedural pain, hyperpigmentation and SVT was also significantly lower after CDFFS. Long term results, at five years follow up, are not yet available.

The most frequent complications of UGFS are mild: transient hyperpigmentation (10% – 15%), telangiectatic matting ( $< 10\%$ ), SVT (5.9% – 13.7%),<sup>224</sup> and neurological events ( $< 1\%$ ), such as visual disturbance, dysaesthesia, headache, and migraine. Transient ischaemic attacks and strokes are limited to isolated cases, mostly without serious sequelae.<sup>143</sup> A symptomatic right to left shunt is an absolute contraindication to foam sclerotherapy. However, patent foramen ovale, present in 25% – 30% of individuals, should not be systematically searched for.

Thromboembolic events ( $< 0.6\%$ ), mostly asymptomatic distal DVT, appear more often after large volume foam injections ( $> 30$  mL), even when foam is prepared with physiological gases.<sup>226</sup> Therefore, it is prudent to limit the foam volume to 16 mL per session for both STS and POL, to comply with European regulations as cited in the European Medicine Compendium (see “summary of product characteristics”, <https://www.medicines.org.uk/emc/product/1199/smpc#gref>) even if the evidence about foam volumes is weak. DVT should be distinguished from deep vein sclerosis (2.7%) consisting of extension of the sclerosis of the treated varicose vein into a connected deep vein. This is a relatively benign clinical entity, which does not require anticoagulation.<sup>227</sup> Exceptionally, anaphylactic shock may occur in isolated cases.

**4.2.2.3. Mechanochemical ablation.** MOCA is a non-thermal non-tumescent technique to ablate incompetent superficial veins of the lower limb. The technique uses a dual injury mechanism that combines mechanical disruption of the intima with chemical endovenous ablation by injecting a sclerosing agent. Currently, at least two devices are commercially available for the treatment of superficial venous incompetence.

The first MOCA device developed abrades the intima by means of the tip of the catheter’s rotating wire. The liquid forms of the sclerosants STS or POL are used most often, which limits the total dose that can be applied. Different concentrations of liquid POL (2% and 3%) have been compared with 1% POL microfoam in a RCT: 1% foam was less effective than 2% or 3% liquid POL ( $p < .001$ ) for treatment of GSV incompetence.<sup>228</sup>

Several prospective studies and RCTs, comparing MOCA with EVTA, have shown that MOCA is safe and effective for ablating incompetent saphenous trunks.<sup>213,229–232</sup> Currently, only up to three year follow up has been reported with occlusion rates of 86.5% in one study, included in a systematic review of novel non-thermal techniques.<sup>213</sup> One RCT similarly revealed a statistically significantly lower GSV occlusion rate of 80% three years after MOCA *versus* 100% after EVLA and RFA ( $p = .002$ ).<sup>232</sup> A strong association was found between recanalisation at three years and the pre-operative GSV diameter. The occlusion rates for a pre-operative GSV diameter of 6 mm, 7 mm, and 8 mm were 100%, 87.5%, and 75%, respectively.<sup>232</sup> The r-VCSS and QoL

measures improved significantly after MOCA in all mentioned studies.<sup>213,229–231</sup>

Pain during and after MOCA was less than after RFA,<sup>229,231</sup> although there was no difference in pain score after MOCA and EVLA in the LAMA trial.<sup>230</sup> Return to daily activities and work did not differ substantially between procedures.<sup>230–232</sup>

The most common complications after MOCA are induration (12% – 18%), SVT (2% – 13%), haematoma (1% – 11%), DVT (0% – 1%), and hyperpigmentation (5%). Nerve injury, skin injury, or infections have not been reported.<sup>213</sup> Therefore this non-tumescent technique may offer a valuable alternative, in particular if ablation of the more distal part of the below knee GSV or the SSV is considered.

Another type of MOCA device causes vein wall scarification by a specially designed endovenous catheter featuring sharp hooks at the tip, which damage the endothelium, while chemical ablation is performed simultaneously by injecting a foam sclerosant. Up to now, the available evidence is very limited. One study showed an occlusion rate of 92% after 24 months.<sup>233</sup>

Recommendation 28		Unchanged	
For patients with great saphenous vein incompetence requiring treatment, endovenous thermal ablation is recommended as first choice treatment, in preference to high ligation/stripping and ultrasound guided foam sclerotherapy.			
Class	Level	References	ToE
I	A	Siribumrungwong <i>et al.</i> (2012), <sup>198</sup> Rasmussen <i>et al.</i> (2013), <sup>175</sup> Hamann <i>et al.</i> (2017), <sup>201</sup> Kheirelseid <i>et al.</i> (2018), <sup>202</sup> Brittenden <i>et al.</i> (2019), <sup>129</sup> Cao <i>et al.</i> (2019) <sup>195</sup>	

Recommendation 29		New	
For patients with saphenous trunk incompetence undergoing thermal ablation, the selection of the device should be left to the discretion of the treating physician.			
Class	Level	References	ToE
I	B	Malskat <i>et al.</i> (2019) <sup>173</sup>	

Recommendation 30		New	
For patients with great saphenous vein incompetence requiring treatment, cyanoacrylate adhesive closure should be considered when a non-thermal non-tumescent technique is preferred.			
Class	Level	References	ToE
Iia	A	Vos <i>et al.</i> (2017), <sup>213</sup> Çalik <i>et al.</i> (2019), <sup>206</sup> Eroglu <i>et al.</i> (2018), <sup>208</sup> Gibson <i>et al.</i> (2019), <sup>234</sup> Morrison <i>et al.</i> (2020), <sup>215</sup> García-Carpintero <i>et al.</i> (2020) <sup>209</sup>	

Recommendation 31		New	
For patients with saphenous trunk incompetence undergoing treatment, ultrasound guided foam sclerotherapy may be considered for treating saphenous trunks with a diameter less than 6 mm.			
Class	Level	References	ToE
Iib	B	Myers <i>et al.</i> (2007), <sup>164</sup> Shadid <i>et al.</i> (2015), <sup>221</sup> Venermo <i>et al.</i> (2016) <sup>222</sup>	

Recommendation 32		New	
For patients with superficial venous incompetence treated with foam sclerotherapy, the procedure should be performed under ultrasound guidance.			
Class	Level	References	ToE
I	C	Consensus	

Recommendation 33		New	
For patients with great saphenous vein incompetence requiring treatment, catheter directed foam sclerotherapy with or without the use of peri-venous tumescent solution may be considered.			
Class	Level	References	ToE
Iib	B	Lim <i>et al.</i> (2020), <sup>224</sup> Dos Santos <i>et al.</i> (2020) <sup>225</sup>	

Recommendation 34		New	
For patients with great saphenous vein incompetence requiring treatment, mechanochemical ablation may be considered when a non-thermal non-tumescent technique is preferred.			
Class	Level	References	ToE
Iib	A	Vos <i>et al.</i> (2017), <sup>213</sup> Holewijn (2019), <sup>229</sup> Mohamed <i>et al.</i> (2021), <sup>230</sup> Vähäaho <i>et al.</i> (2021) <sup>232</sup>	

**4.2.3. High ligation and stripping.** Venous reflux elimination through HLS of the GSV or SSV with additional phlebectomies has been the standard treatment for VVs for many years and may still be a valuable option. Nowadays, similar to EVTA, HLS can be performed under local or tumescent anaesthesia with ultrasound guidance, a strategy that has been followed in several RCTs comparing EVTA with HLS.<sup>132,134,175,235</sup> This means general anaesthesia is not mandatory for “modern” HLS.

As already discussed in subsection 4.2.1.2, long term (five year) results of EVTA and HLS are not different with respect to clinical VV recurrence or recurrent reflux detected by DUS, although the site of recurrence may be different.<sup>134,177,200,202,203</sup> In addition, a meta-analysis looked at pooled long term outcome data (five years) of

two RCTs and 10 follow up studies of RCTs on treatment of GSV incompetence. Recurrent reflux rates at the SFJ were statistically significantly lower after HLS than after EVLA (12%, 95% CI 7 – 20% vs. 22%, 95% CI 14 – 32%;  $p = .038$ ). The r-VCSS scores were also pooled for HLS and EVLA and showed similar improvements.<sup>201</sup>

When comparing complications after HLS with those after EVLA, bleeding and haematoma (4.8% vs. 1.3%), wound infection (1.9% vs. 0.3%), and paraesthesia (11.3% vs. 6.7%) were more frequent after HLS.<sup>236</sup>

Recommendation 35			New
For patients with great saphenous vein incompetence requiring treatment, high ligation/stripping should be considered, if endovenous thermal ablation options are not available.			
Class	Level	References	ToE
Iia	A	O'Donnell <i>et al.</i> (2016), <sup>177</sup> Hamann <i>et al.</i> (2017), <sup>201</sup> Kheirleisid <i>et al.</i> (2018) <sup>202</sup>	

### 4.3. Techniques for the treatment of tributaries

**4.3.1. Phlebectomies.** The technique for ambulatory phlebectomy (AP) involves multiple small (2 – 3 mm) longitudinal incisions overlying pre-operatively marked VVs. Incisions are performed under local anaesthesia. The targeted VVs are removed with specially designed phlebectomy hooks and fine tipped mosquito clamps. Tributary intervention is typically performed as an adjunct to truncal ablation for associated large incompetent tributaries (> 5 mm diameter) or in isolation where truncal competence is confirmed on DUS. Also, it can be part of specific treatment strategies with preservation of the saphenous trunk (see subsection 4.6.7). In those undergoing saphenous ablation the need for additional AP should always be discussed with the patient to facilitate shared decision making.

With the development of EVTA, most interventions are performed using tumescent anaesthesia. Tumescent anaesthesia also is routinely used for AP, which may be performed during the same endovenous ablation procedure. A small RCT (50 patients), comparing AP with no tributary intervention as an adjunct to EVLA using tumescence, identified no difference in peri-procedural complication rates and pain between cohorts.<sup>237</sup> Whether to perform concomitant or delayed phlebectomies, in the context of EVTA, will be discussed further in subsection 4.6.4.

Complications of APs are generally infrequent and mild: blisters (5.4%), hyperpigmentation (4.6%), matting (3.6%), SVT (2.8%), DVT (0.02%), dysaesthesia (0.4%), lymphocele (0.2%), post-operative haemorrhage (0.1%), large haematoma (0.1%), and infection (0.07%).<sup>238</sup>

**4.3.2. Sclerotherapy of tributaries.** Sclerotherapy offers a minimally invasive alternative to AP. It is used frequently as an adjunct to endovenous truncal ablation or to treat residual varicose tributaries and non-saphenous VVs as it is well

tolerated without the need for anaesthesia and may be performed repeatedly in the ambulatory setting. In the treatment of incompetent tributaries, foam based sclerotherapy is used widely as it is more effective and allows a reduction in the amount of injected sclerosant.<sup>219</sup> Liquid sclerotherapy is reserved largely for treatment of reticular veins and telangiectasias (see subsection 4.5.1).<sup>143</sup> The concentration of the sclerosant used depends on the size of the treated vein. A systematic review found no significant difference in effectiveness and symptom improvement of any commonly used sclerosant.<sup>239</sup> Cannulation of non-clinically visible VVs always should be performed under ultrasound guidance to limit complications. There is no evidence based limit to the maximum volume of foam per session, although current consensus suggests a maximum use of 10 – 20 mL of foam per treatment.<sup>143,240</sup> This corresponds with the previously proposed limit of 16 mL, to comply with European regulations (see subsection 4.2.2.2).

In foam based strategies, larger VVs should be targeted initially to encourage wider foam dispersal with subsequent interventions reserved for residual tributaries, reticular veins, and telangiectasias. Successful ablation of tributary disease often requires a staged approach including a number of UGFS sessions.<sup>241</sup> This treatment strategy is characterised by intermittent ambulatory clinical and DUS review, with subsequent UGFS of residual refluxing veins in a stepwise fashion.

The efficacy of sclerotherapy in treating tributaries and non-saphenous VVs has been described in the literature. One RCT showed statistically significantly higher patient satisfaction after non-saphenous vein sclerotherapy than after placebo ( $p < .001$ ), with 85.9% of patients satisfied or very satisfied with the treatment.<sup>242</sup> Another RCT found that in those with minor below knee VVs, sclerotherapy statistically significantly reduced the proportion of people reporting aching and cosmetic concerns compared with conservative treatment after one year ( $p < .050$ ).<sup>243</sup> Greater symptomatic improvement has been demonstrated after liquid sclerotherapy for isolated tributary disease compared with compression hosiery, without the need for long term compression ( $p < .001$ ).<sup>244</sup>

In a RCT comparing sclerotherapy with AP for below knee VVs, sclerotherapy resulted in a statistically significant improvement in symptoms ( $p < .050$ ), which was comparable with AP.<sup>243</sup> At one year follow up, there were no visible VVs in 76% of patients after surgery and 39% after sclerotherapy ( $p < .050$ ). Despite this, no statistically significant difference in patient satisfaction was observed.<sup>243</sup> Another RCT, which compared liquid sclerotherapy with AP in the management of isolated tributary incompetence ( $n = 98$ ), identified statistically significantly higher rates of recurrent disease in those undergoing sclerotherapy at one (25% vs. 2.1%,  $p < .001$ ) and two years (37.5% vs. 2.1%,  $p < .001$ ). Rates of phlebitis were comparable in each group; however, AP was statistically significantly associated with both blister and scar formation.<sup>245</sup> It should be noted that the treatment protocol for sclerotherapy of tributaries, used in these trials, was not optimal, as liquid sclerosant was used.



In patients with CVD treated with endovenous ablation of an incompetent saphenous trunk, additional UGFS may be useful for treating small varicose tributaries (< 5 mm). However, the timing of such adjunctive treatment, either concomitant or delayed, remains unclear (see subsection 4.6.4).

Whether to opt for AP or UGFS for varicose tributaries depends largely on the physician’s experience and preference in view of the patient’s expectations. According to a worldwide survey about management strategies for patients with VVs, in which 211 physicians from 36 different countries participated, APs were as frequently used as UGFS for refluxing tributaries. However, there was a preference for phlebectomies in cases where tributaries had a large diameter, a superficial course, or where they were visible, and a preference for UGFS in other cases ( $p < .001$ ).<sup>246</sup> In patients presenting with skin changes, in particular lipodermatosclerosis (CEAP clinical class C4b), adjacent phlebectomies may be complicated by delayed wound healing. In these cases, UGFS is a valid alternative option.

Recommendation 36		Changed	
For patients with chronic venous disease requiring treatment of varicose tributaries, ambulatory phlebectomy, ultrasound guided foam sclerotherapy or a combination of both are recommended.			
Class	Level	References	ToE
I	B	de Roos et al. (2003), <sup>245</sup> Michaels et al. (2006), <sup>243</sup> Zhang et al. (2012), <sup>242</sup> Vasquez et al. (2017) <sup>247</sup>	

**4.3.3. Other techniques for varicose tributary treatment.**

Transilluminated powered phlebectomy provides an alternative treatment for varicose tributaries, in particular in those limbs with extensive VVs offering the benefit of fewer incisions and shorter procedural times.<sup>248</sup> However higher rates of ecchymosis (39% vs. 25%,  $p < .001$ ) and pain with inferior early QoL have been reported in a RCT comparing transilluminated powered phlebectomy with AP.<sup>249</sup> A learning curve should certainly be taken into account.<sup>250</sup>

Endovenous laser treatment of incompetent tributaries offers a further therapeutic alternative, mainly applicable for large varicose tributaries.<sup>251</sup> Only limited retrospective data are available so far, suggesting that EVLA of tributaries may be associated with higher rates of tributary re-intervention (21.6%, vs. 4.9%,  $p < .010$ ) when compared with adjunctive UGFS of tributaries.<sup>252</sup>

**4.4. Techniques for treating perforating veins**

The role and management of PV incompetence remains controversial. Incompetent PVs may act as a primary source of reflux or emerge as a consequence of deteriorating global

venous function and DVI. During the initial stages of CVD (C2 – C3), PVs may act as a re-entry point for superficial venous incompetence and present a net inward flow during a compression release manoeuvre. In such cases, treatment of refluxing trunks and tributaries is usually sufficient.

Treatment of PV incompetence has been studied specifically when related to VLU (see subsection 6.4.3), VV recurrence (see subsection 4.7.3), and as an integral part of the CHIVA concept (see subsection 4.6.7.1). A retrospective study suggested improved ulcer healing associated with a combination of truncal and PV EVLA versus truncal ablation alone.<sup>253</sup> In a *post hoc* analysis of 97 patients undergoing surgery for both truncal and PV incompetence, as part of a RCT comparing surgery with conservative treatment, the authors found more recurrent VLUs (C6r) when PV ligation had been incomplete.<sup>254</sup> Treatment strategies for incompetent PVs are further discussed in subsection 4.6.6.

**4.4.1. Perforating vein ligation.** Surgical ligation of incompetent PVs through a short incision has been studied prospectively in 145 limbs where 850 incompetent PVs were identified and ligated. The closure rate was 94.3%. Sclerotherapy was used to complete closure. After three years, 67.8% of the ligated PVs remained obliterated.<sup>255</sup>

In the absence of endovenous options, open PV ligation is feasible in selected patients, particularly in cases with healthy overlying skin, such as recurrent VVs from a popliteal fossa PV.<sup>256</sup> In preparation for open intervention all PV positions should be marked with ultrasound routinely. However, despite pre-operative marking, the anatomy may be challenging with complex subfascial and subcutaneous branching systems, and thus predispose to recurrence.<sup>255</sup> An alternative approach is to perform a phlebectomy of tortuous subcutaneous PV branches through stab incisions. To date exact procedural success rates are unknown given a paucity of data.

**4.4.2. Perforating vein ablation.** PV ablation has been reported widely, including EVLA, RFA, MOCA, CAC, and ultrasound guided injections with sclerosing agents, liquid, or foam.<sup>190,253,257–261</sup> Direct cannulation of PVs is often difficult because of tortuosity of the vein and the condition of the overlying diseased or ulcerated skin. Adjacent VVs may be traversed to gain indirect access from sites of healthy skin. While short introducers provide adequate access for regular endovenous catheters, cannulation may be further facilitated by small diameter catheters and shorter heating elements (e.g., stylet, for RFA). Increasingly, specific catheters dedicated to PV intervention are available, providing a means of direct PV puncture.

The closure rate for thermal techniques such as RFA and EVLA is lower for PVs (60% – 80%) than for truncal veins (> 90% for EVLA),<sup>173</sup> in the available retrospective studies to date.<sup>253,258,262</sup> As a proportion of ablated PVs recanalise with time, routine early DUS surveillance and re-



intervention is advocated, particularly in patients with VLU. Complication rates are generally low, comparable with ablation in other venous segments.

With regard to non-thermal techniques, MOCA for PVs is reported with low morbidity but closure rates are yet to be established definitively.<sup>259</sup> Conversely, CAC with a catheter or direct percutaneous injection, has been reported with almost 100% closure rates at six months, although some thrombotic extensions into the deep system, phlebitis like reactions, and pain were reported in these patients.<sup>260</sup>

In clinical practice, the most commonly used treatment of incompetent PVs is UGFS, as it is cheap, easy to use in an outpatient setting, and requires no local anaesthesia.<sup>263</sup> At approximately 50%, occlusion rates are lower than for RFA or EVLA, but UGFS can be repeated at follow up if needed or, in the event of failure, the PVs can be treated with another endovenous method. Complications are minimal considering its widespread use. Local calf vein DVT has been reported after 3% of 189 injections in a group of 62 patients with active VLU and a history of DVT in one third of these patients.<sup>263</sup> There are some rare cases of inadvertent intra-arterial injection with sclerosing agent reported, causing distal ischaemia, and even requiring subsequent amputation. To avoid this, careful ultrasound guidance is of the utmost importance. Cannulation can be performed through a connecting VV, thereby avoiding the small artery adjacent to the PV.

To date there are no randomised studies comparing the reported endovenous methods for PV ablation. However tortuous PVs of smaller diameter are likely to be more suitable for sclerotherapy than larger, straighter PVs where the sclerosing agent will be washed out rapidly.

**4.4.3. Other techniques.** Subfascial endoscopic perforator surgery (SEPS) is a minimally invasive alternative to open PV ligation. It requires endoscopic equipment, general or regional anaesthesia, and a bloodless field. PVs are divided subfascially with diathermy or clips. The closure rate reported is higher than that of endovenous methods but there is no study providing a direct comparison between SEPS and endovenous ablation.<sup>264</sup> Minor complications such as haematoma, pain, and minor nerve injury are reported in 30% – 40%, but serious adverse events are rare.

Recommendation 37 <span style="float: right;">New</span>			
<b>For patients with chronic venous disease requiring treatment of incompetent perforating veins, endovenous ablation, division or ligation should be considered.</b>			
Class	Level	References	ToE
Iia	C	Abdul-Haqq <i>et al.</i> (2013), <sup>253</sup> Kiguchi <i>et al.</i> (2014), <sup>263</sup> van Gent <i>et al.</i> (2015), <sup>254</sup> Gibson <i>et al.</i> (2020) <sup>216</sup>	

**4.5. Techniques for treatment of reticular veins and telangiectasias**

The first step before the treatment of patients with reticular veins (1 – 3 mm) and telangiectasias ( $\leq 1$  mm) should always be DUS examination, as there is a significant association between the extent of telangiectasias and increasing incompetence in the superficial veins ( $p = .006$ ) and/or deep veins ( $p < .001$ ).<sup>265</sup> Treatment is usually started with larger incompetent superficial trunks and varicose tributaries and ends with reticular veins and telangiectasias.<sup>74</sup>

Recommendation 38 <span style="float: right;">New</span>			
<b>For patients presenting with reticular veins and/or telangiectasias, duplex ultrasound of lower extremity veins should be performed before treatment, to look for associated incompetent veins.</b>			
Class	Level	References	ToE
I	C	Ruckley <i>et al.</i> (2012) <sup>265</sup>	

Recommendation 39 <span style="float: right;">New</span>			
<b>For patients presenting with reticular veins and/or telangiectasias, significant associated incompetent veins should be treated first, before considering treatment of smaller veins.</b>			
Class	Level	References	ToE
I	C	Consensus	

**4.5.1. Sclerotherapy.** Sclerotherapy is the gold standard for treating reticular veins and telangiectasias. There are two major categories of sclerosing agents used to treat patients with C1 disease, with different mechanisms of action on endothelial cells: detergents (POL, STS) or osmotics (hypertonic saline, hypertonic glucose). The effectiveness of sclerotherapy in the treatment of reticular veins and telangiectasias has been amply described in the literature, with a reported treatment success rate of 95% after POL and 91% after STS.<sup>266</sup> Another RCT showed statistically significantly higher patient and investigator satisfaction after sclerotherapy with POL than after placebo ( $p < .001$ ), with the percentage of patients and investigators satisfied or very satisfied ranging between 86% and 90%.<sup>242</sup> Regarding the use of foam or liquid sclerotherapy in the treatment of C1 disease, a systematic review found no evidence for superior efficacy of one form over the other, although visual disturbances seemed to be more common with foam than with liquid.<sup>219</sup>

Analysing the difference between sclerosants, a Cochrane review found no evidence suggesting superior efficacy or increased patient satisfaction with any sclerosant.<sup>267</sup> However, one RCT showed greater patient satisfaction after sclerotherapy of reticular veins and telangiectasias with POL than with STS at week 12 (88% vs. 64%,  $p < .001$ ) and week 26 (84% vs. 63%,  $p < .001$ ).<sup>266</sup> Another RCT has also proven

the greater efficacy of POL than 20% hypertonic saline solution in treatment of reticular veins > 1 mm. Good and very good results were achieved in 86% versus 67% of patients treated with POL versus HS, respectively (RR = 2.70;  $p = .003$ ).<sup>268</sup> Another RCT showed that a combination of 0.2% POL diluted in 70% hypertonic glucose was statistically significantly more effective than 75% hypertonic glucose alone ( $p < .001$ ) in treatment of both reticular veins and telangiectasias, with no statistical difference in complications.<sup>269,270</sup>

Comparing sclerotherapy with transcutaneous laser (TCL), sclerotherapy has been shown to be as effective as 1064 nm Nd:YAG TCL, especially in treatment of reticular veins > 1 mm, but markedly less painful.<sup>271,272</sup> One RCT demonstrated statistically significant lower efficacy of sclerotherapy with POL compared with 1064 nm Nd:YAG in the treatment of telangiectasias < 1 mm (95% vs. 53%;  $p < .001$ ),<sup>268</sup> whereas two other trials did not confirm these results and found no statistically significant difference in disappearance of veins with a diameter of 0.2 – 2.9 mm and no difference in patient satisfaction between sclerotherapy and Nd:YAG.<sup>271,272</sup>

Sclerotherapy related adverse events have been described in detail in subsection 4.2.2.2. The majority of adverse events after sclerotherapy of reticular veins and telangiectasias are mild and the most frequent are transient hyperpigmentation, neovascularisation, and injection site scar.<sup>242,266</sup>

Recommendation 40			New
For patients with reticular veins, where treatment is planned, sclerotherapy is recommended, as the first choice treatment.			
Class	Level	References	ToE
I	A	Hamel-Desnos <i>et al.</i> (2009), <sup>219</sup> Rabe <i>et al.</i> (2010), <sup>266</sup> Munia <i>et al.</i> (2012), <sup>271</sup> Zhang <i>et al.</i> (2012), <sup>242</sup> Parlar <i>et al.</i> (2015), <sup>272</sup> Bertanha <i>et al.</i> (2017), <sup>269</sup> Ianos <i>et al.</i> (2019) <sup>268</sup>	

Recommendation 41			New
For patients with telangiectasias, where treatment is planned, sclerotherapy should be considered.			
Class	Level	References	ToE
Iia	A	Hamel-Desnos <i>et al.</i> (2009), <sup>219</sup> Rabe <i>et al.</i> (2010), <sup>266</sup> Munia <i>et al.</i> (2012), <sup>271</sup> Zhang <i>et al.</i> (2012), <sup>242</sup> Parlar <i>et al.</i> (2015), <sup>272</sup> Ianos <i>et al.</i> (2019), <sup>268</sup> Bertanha <i>et al.</i> (2021) <sup>270</sup>	

**4.5.2. Transcutaneous lasers and intense pulse light sources.** TLC uses selective photothermolysis, to obliterate blood vessels while sparing surrounding tissues. The technique is based on proper energy delivery by selecting the wavelength, the pulse duration and providing sufficient radiant exposure to cause irreversible damage to the target structure.<sup>273</sup>

Laser light is selectively absorbed by oxyhaemoglobin and converted to thermal energy, leading to heating of the telangiectatic or reticular veins, coagulation, and vessel destruction.

Standard vascular lasers include pulsed dye lasers (PDL) (585 and 595 nm), potassium titanyl phosphate (KTP) lasers (532 nm), alexandrite lasers (755 nm), diode lasers (800 – 900 nm), and Nd:YAG lasers (1 064 nm). New developments include the use of non-uniform pulse sequences, dual wavelength modalities, and microsecond Nd: YAG lasers.<sup>274</sup>

When considering laser treatment for reticular veins or telangiectasias, the choice of the appropriate laser primarily depends on the size of the target vessel. Telangiectasias are usually safely and more effectively treated with shorter wavelength (< 600 nm) lasers (KTP and PDL), although the 1064 nm Nd:YAG laser also proved to be effective to treat these veins.<sup>268,274–276</sup> For reticular veins the use of a laser modality operating at a longer wavelength (Nd:YAG) is efficacious.<sup>274,275</sup>

The Nd:YAG laser has been shown to be similarly effective to sclerotherapy in comparative studies, with similar patient satisfaction,<sup>268,271,272</sup> but it is associated with more pain, and therefore it is more suitable for specific indications, such as needle phobia, sclerosant allergy, sclerotherapy failure, and presence of small veins with telangiectatic matting. Topical anaesthetics provide safe and highly effective local anaesthesia for lower limb vein TCL therapy.<sup>277</sup>

An alternative treatment for larger reticular veins may consist of using alexandrite or diode lasers, although their efficacy appeared to be inferior to Nd:YAG.<sup>274</sup>

Intense pulsed light lasers should not be used as first line treatment because there is a relatively high risk of damaging non-vascular structures because of simultaneous delivery of multiple light wavelengths (500 – 1 200 nm).<sup>274</sup>

Cooling has become an integral part of laser treatments to minimise epidermal damage without reducing the effect on the target vessel. Cooling can be achieved by using a cryogen spray, cold sapphire contact handpieces or pre-cooled air, blown on the skin surface.<sup>273,274</sup>

Recommendation 42			Changed
For patients with telangiectasias, where treatment is planned, transcutaneous laser should be considered.			
Class	Level	References	ToE
Iia	B	Munia <i>et al.</i> (2012), <sup>271</sup> Parlar <i>et al.</i> (2015), <sup>272</sup> Ianos <i>et al.</i> (2019) <sup>268</sup>	

**4.5.3. Hybrid techniques.** Recent technical modifications have been reported to improve substantially the effectiveness of TCL.

Indocyanine green injected shortly before the diode laser therapy has been shown to be superior to PDL diode laser therapy alone and 1 064 nm Nd:YAG laser, but the treatment is markedly more painful than Nd:YAG laser. Therefore, a longer observation of the treated patients is needed.<sup>278,279</sup>

The combined treatment of 1 064 nm Nd:YAG long pulse laser after foam sclerotherapy with POL has proven to be more effective than sclerotherapy alone at three months, two and three years after treatment.<sup>280</sup>

Cryolaser and cryosclerotherapy guided by augmented reality (CLaCS) is a new option for treating telangiectasias, reticular and feeder veins with promising results, although more studies are required for its validation.<sup>281</sup>

**4.6. Interventional treatment strategy for superficial venous incompetence**

For patients with CVD, as in other fields of medicine, shared decision making should be the norm when making treatment decisions. It can be defined as a collaborative process through which a clinician supports a patient to reach a decision about their treatment. To be effective, it should bring together a clinician’s expertise, such as knowledge of treatment options, with evidence, risks and benefits, what is available in the relevant healthcare system and costs and cost effectiveness if applicable, as well as the patient’s personal preferences, values, and individual circumstances. Evidence suggests that shared decision making results in individuals who are more likely to adhere to treatment regimens, more likely to have improved outcomes, and less likely to regret the decisions that are made.<sup>282,283</sup>

**4.6.1. Great saphenous vein incompetence.** In those who meet the criteria for intervention (see subsection 4.1.1) strategies for treating GSV incompetence and its tributaries should be amply discussed with the patient, as part of a shared decision making process. For GSV treatment, the

choice of treatment will be guided further by the respective, specific recommendations for use of each interventional modality (see subsections 4.2 and 4.3). Table 10 provides a brief illustrative summary of techniques available for treating incompetent saphenous trunks. While efficacy across several modalities (EVTA, HLS, CAC) for treating GSV incompetence is similar, EVTA has been widely advocated as the first line of care because of its excellent long term results and its cost effectiveness.<sup>124</sup> The decision making process and available options for treating GSV incompetence and its tributaries is further summarised in Fig. 7.

Modern HLS, performed after detailed DUS mapping and under local or tumescent anaesthesia where possible, remains a good option with similar five year results to EVTA. Although endovenous thermal and non-thermal ablation have largely replaced open surgery in many countries, HLS can still be applied whenever equipment for endovenous ablation or expertise is not available.<sup>127,246</sup>

The potential use of non-thermal non-tumescent techniques, such as CAC and MOCA, will depend largely on the patient’s preference, local availability of the equipment, and experience of the treating physician. Non-thermal ablation may offer lower rates of procedural pain and ecchymosis than EVTA.<sup>284</sup> In addition, it may be applicable more easily than EVTA below midcalf, as no tumescence is needed. When a non-thermal technique is preferred, CAC should be the first choice as it has similar efficacy to EVTA, followed by MOCA, CDFS, or UGFS. However, as CAC is more expensive in most countries, this affects its implementation.<sup>285</sup> MOCA is a reasonable alternative for patients preferring non-thermal non-tumescent treatment, even if the occlusion rate at three years was inferior to that of EVTA.<sup>232</sup> Another validated technique is CDFS, often applied with perivenous tumescent solution, to reduce the vein diameter during treatment. Finally, although the occlusion rate is lower, UGFS remains the most frequently performed non-thermal non-tumescent ablation technique worldwide, because it is easily applicable and repeatable. Scheduled follow up with DUS after four to six weeks and additional injections, if needed, are an essential aspect of a UGFS strategy.<sup>164</sup>

**Table 10. Illustrative summary of techniques available for treating saphenous trunk incompetence**

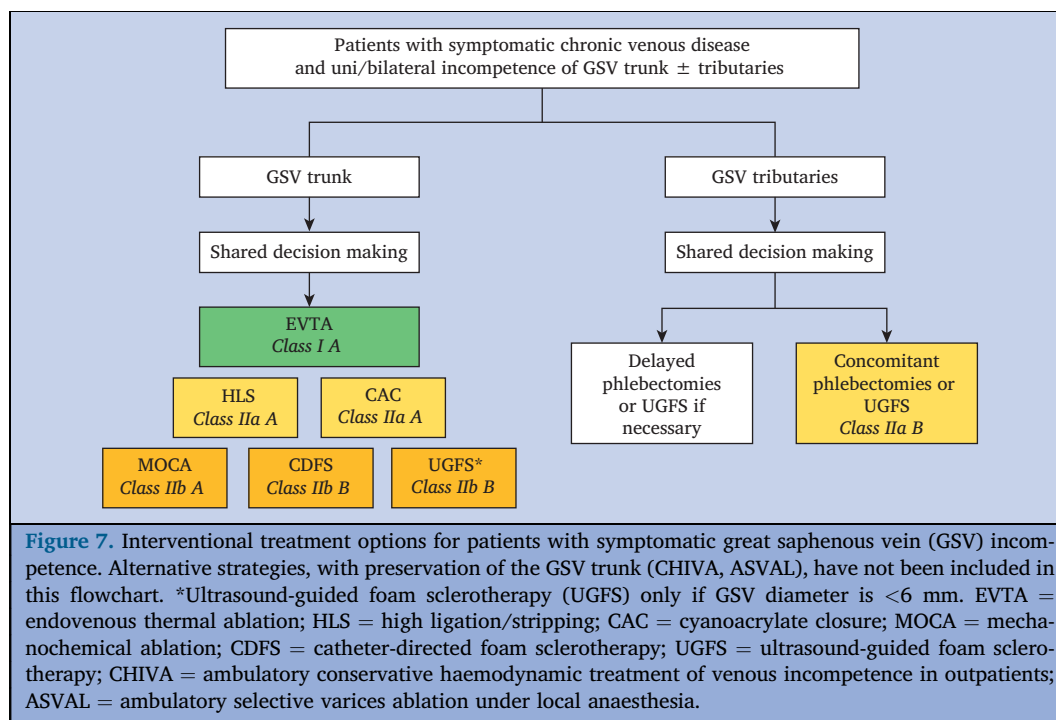
Technique	Published follow up	Reflux abolition	Quality of life improvement	Tumescence needed	Risk of nerve injury below mid-calf <sup>c</sup>
EVTA	≥ 5 y	+++	+++	Yes	Yes
HLS	≥ 5 y	+++	+++	Yes <sup>†</sup>	Yes
CAC	3–5 y	+++	+++	No	No
UGFS	≥ 5 y	+/ <sup>‡</sup> +++ <sup>‡</sup>	+/+++ <sup>‡</sup>	No	No
CDFS	1 y	++	++	Yes/no	No
MOCA	3 y	++	+++	No	No

EVTA = endovenous thermal ablation; HLS = high ligation and stripping; CAC = cyanoacrylate adhesive closure; UGFS = ultrasound guided foam sclerotherapy; CDFS = catheter directed foam sclerotherapy; MOCA = mechanochemical ablation. +++ = very good effect; ++ = good effect; + = some effect (see details in subsection 4.1 – 4.3).

\* For other complications: see details in subsections 4.1 – 4.3.

<sup>†</sup> Or alternative anaesthesia technique.

<sup>‡</sup> Truncal diameter < 6 mm.



Mainly for saphenous trunks < 6 mm in diameter, UGFS is considered to be a valuable alternative, provided the use of an adequate injection strategy (i.e., several injections of foam along the target vein, instead of just one injection distally).

Very large GSVs (with a diameter > 12mm) may be treated effectively with EVTA,<sup>286</sup> without the need for high ligation, even if HLS remains a valid alternative (see subsection 4.6.8.1). Apart from very exceptional cases, such as large GSV aneurysms close to the SFJ (see subsection 4.6.8.4), there is no indication for adding high ligation to EVTA.<sup>127</sup>

**4.6.2. Small saphenous vein incompetence.** Incompetence of the SSV represents a significant burden of disease with associated debilitating symptomatology.<sup>287</sup> Ligation of the SPJ with or without stripping of the proximal SSV (open SSV surgery) has long represented the standard of care in this cohort. However, operative dissection is often rendered challenging by the variable anatomy of the SPJ, with extensive anatomical exposures predisposing to a higher risk of neurological morbidity.<sup>288</sup> On the other hand, poor visualisation of junctional anatomy and inadequate control of reflux points increase the risk of subsequent recurrence. As a result, endovenous strategies are advocated increasingly to replace surgery in the management of SSV reflux (Fig. 8).<sup>289</sup>

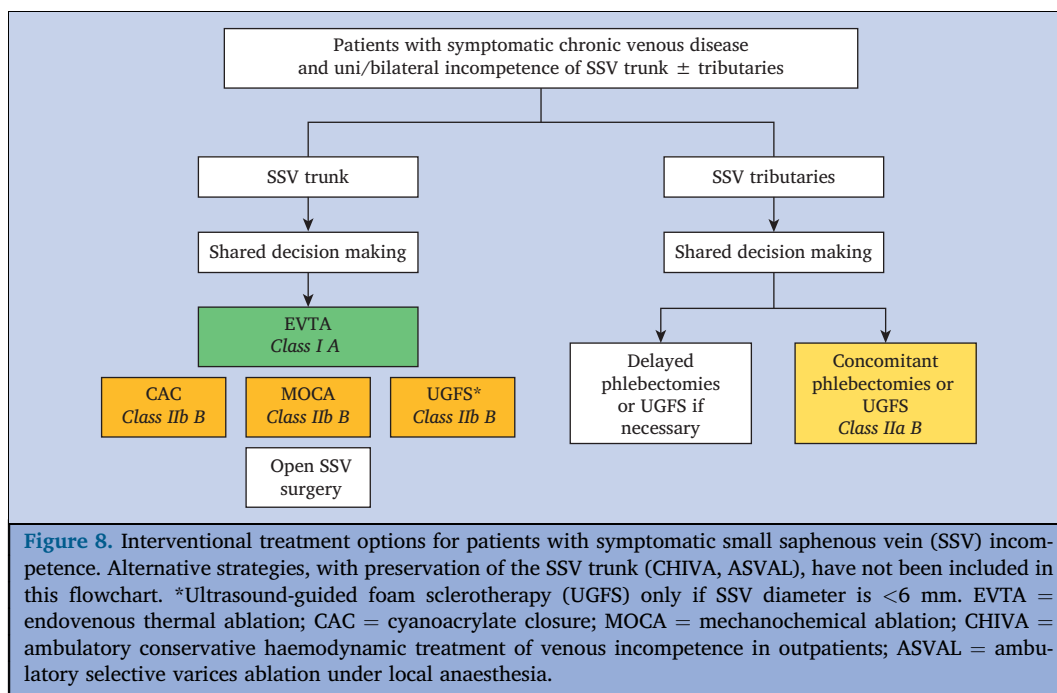
In a Cochrane review, data from three RCTs,<sup>290–292</sup> examining the outcomes of 311 participants undergoing either SSV EVLA or open surgery were studied.<sup>293</sup> One year ultrasound recurrence statistically significantly favoured EVLA (pooled odds ratio = 0.24, 95% CI 0.07 – 0.77,  $p = .016$ ). No differences in early QoL and rate of DVT were identified between groups. Sural nerve injury was

commonly identified and notably higher in the open surgery cohort (28.8% vs. 6.8%).<sup>293</sup> This risk may be precluded further by SSV puncture at midcalf level, with lower access points at the lateral malleolus associated with higher rates of post-procedural pain and neuropathy because of sural nerve injury.<sup>142</sup> Alternatively sural nerve hydrodisplacement may reduce rates of sural nerve injury in those requiring more distal SSV intervention.<sup>294</sup>

Further meta-analysis,<sup>288</sup> of 49 observational studies (including five RCTs) reported procedural occlusion rates of the various SSV interventions as follows; EVLA 98.5%, RFA 97.1%, UGFS 63.6%, open SSV surgery 58%. Early reports of the efficacy of other non-thermal non-tumescent ablative procedures for SSV incompetence (CAC, MOCA) are yet to be supported by additional long term RCTs, to reach a higher level of evidence.<sup>208–210</sup>

For patients with SSV incompetence, treatment strategy should be based on shared decision making, as for the GSV. In view of the above mentioned evidence, EVTA is the first choice treatment modality. Non-thermal non-tumescent techniques, including UGFS, may be a valid alternative and open SSV surgery can still be an option if other techniques are not available (Fig. 8).

Recommendation 43		Changed	
For patients with small saphenous vein incompetence requiring treatment, endovenous thermal ablation is recommended in preference to surgery or foam sclerotherapy.			
Class	Level	References	ToE
I	A	Doganci <i>et al.</i> (2011), <sup>142</sup> Paravastu <i>et al.</i> (2016), <sup>293</sup> Boersma <i>et al.</i> (2016) <sup>288</sup>	



Recommendation 44 <span style="float: right;">New</span>			
For patients with small saphenous vein incompetence requiring treatment, endovenous non-thermal non-tumescent ablation methods may be considered.			
Class	Level	References	ToE
Iib	B	Boersma <i>et al.</i> (2016), <sup>288</sup> Lane <i>et al.</i> (2017), <sup>231</sup> Garcia-Carpintero <i>et al.</i> (2020), <sup>209</sup> Mohamed <i>et al.</i> (2021) <sup>230</sup>	

Recommendation 45 <span style="float: right;">New</span>			
For patients with small saphenous vein incompetence treated by endovenous thermal ablation, care should be taken to avoid injury to the sural nerve if cannulation is carried out below midcalf level.			
Class	Level	References	ToE
I	B	Doganci <i>et al.</i> (2011), <sup>142</sup> Rodriguez-Acevedo <i>et al.</i> (2017) <sup>294</sup>	

**4.6.3. Anterior accessory saphenous vein incompetence.**

Isolated AASV reflux accounts for 10% of symptomatic presentations of patients with VVs.<sup>295</sup> The AASV has a relatively short course (5 – 20 cm from the SFJ) and its incompetence manifests clinically as VVs of the antero-lateral thigh, lateral knee, and lower leg (Fig. 4). AASV incompetence has morbidity rates similar to isolated GSV incompetence.<sup>296</sup> Between 8% and 32% of limbs with ablated GSVs may subsequently develop AASV reflux.<sup>297,298</sup>

Multiple strategic approaches have been described to treat AASV incompetence; however, supportive trial data are sparse.<sup>299</sup> While retrospective reports<sup>300,301</sup> identify

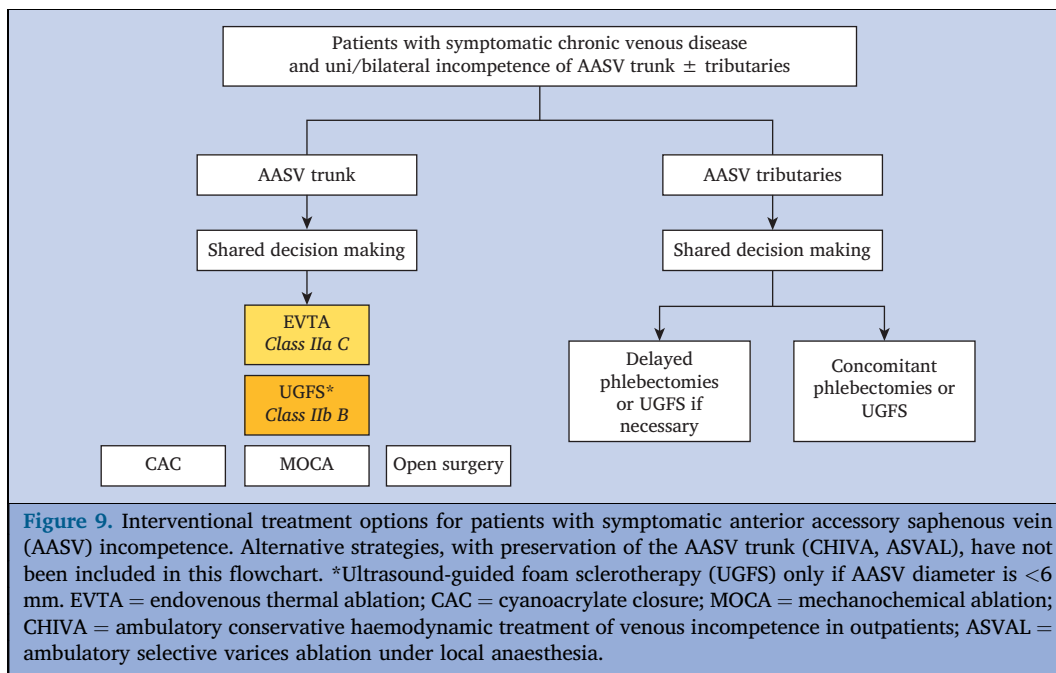
recurrence rates of 1.6% – 36% associated with open surgery (HLS or ligation and short excision of the AASV), this approach has been largely superseded by endovenous intervention.<sup>127,299</sup> In two prospective reports the outcomes of 206 accessory trunks undergoing EVLA with or without UGFS were studied: both found closure rates of 100% and significant improvements in QoL.<sup>302,303</sup> Similarly, a recanalisation rate of 3.6% at 28 months was identified among 139 saphenous trunks, treated with UGFS alone.<sup>304</sup> Most recently, a small series has suggested the early efficacy of AASV CAC.<sup>234</sup> MOCA modalities are yet to be definitively examined; however, given the proven efficacy of non-tumescent non-thermal techniques elsewhere, its effects are probably transferable to alternative saphenous trunks with further data required.

An alternative strategy for patients with symptomatic AASV incompetence consists of performing single ambulatory phlebectomies, without high ligation (see subsection 4.6.7.2). In a small prospective study (65 patients) with one year follow up, this approach appeared to be efficacious and safe. The mean diameter of the AASV significantly reduced (from 6.4 to 3.4 mm) and AASV reflux was abolished in 82% of treated limbs.<sup>305</sup>

The treatment strategy for patients with AASV incompetence is summarised in Fig. 9.

Recommendation 46 <span style="float: right;">New</span>			
For patients with incompetence of the anterior accessory saphenous vein requiring treatment, endovenous thermal ablation should be considered.			
Class	Level	References	ToE
IIa	C	Theivacumar <i>et al.</i> (2009), <sup>302</sup> King <i>et al.</i> (2009) <sup>303</sup>	





Recommendation 47			New
For patients with incompetence of the anterior accessory saphenous vein requiring treatment, ultrasound guided foam sclerotherapy may be considered.			
Class	Level	References	ToE
IIb	C	Bradbury <i>et al.</i> (2010) <sup>304</sup>	

**4.6.4. Concomitant versus delayed phlebectomies/sclerotherapy.** Endovenous ablation procedures may be performed as single interventions on the incompetent saphenous trunks, followed by delayed tributary treatment if needed, or with concomitant phlebectomies or foam sclerotherapy of tributaries.<sup>252,306</sup> The optimal timing of tributary treatment remains unclear and objective testing to assess cohorts who will benefit from adjunctive phlebectomy is lacking.

On one hand, several studies have shown that, after any type of truncal ablation, many tributaries collapse spontaneously after an interval of six weeks to six months.<sup>234,306,307</sup> Nevertheless the durability of this initial result, and in particular the need for re-intervention in the long term, has not been studied extensively.<sup>308</sup> On the other hand, concomitant treatment reduces the need for subsequent treatment of residual tributaries, as has been demonstrated in several RCTs and a meta-analysis.<sup>309</sup> In the AVULS study, 36% of patients required a secondary treatment of tributaries in the EVTA alone group versus 2% in the EVTA plus simultaneous phlebectomies group ( $p < .001$ ).<sup>306</sup> A previously performed, smaller RCT (50 patients) had shown rates of 66% and 4%, respectively.<sup>237</sup> Initially, concomitant phlebectomies resulted in improved VCSS and QoL (AVVQ) scores, but this effect had disappeared after one year and remained the same after five years.<sup>237,306,310</sup>

Another multicentre RCT has shown that foam sclerotherapy in combination with EVTA provided improvement in symptoms and QoL as well as patient and physician assessed appearance ( $p < .05$ ), and reduced the need for additional treatment ( $p < .05$ ).<sup>247</sup> With regard to the risk of VTE, meta-analysis outcomes have identified similar rates of peri-procedural DVT (2.8% vs. 1.8%,  $p = .31$ ) associated with both concomitant and staged approaches, respectively.<sup>309</sup>

For patients with incompetent GSV and SSV, with refluxing varicose tributaries, the treatment strategy for the latter (Figs. 7 and 8) should be based on shared decision making, taking into account the potential advantages and disadvantages of concomitant versus delayed treatment. As the length of the AASV is usually rather short and the visible VVs often extend below the knee, concomitant tributary treatment is considered in most of these cases (Fig. 9).

Recommendation 48			Unchanged
For patients with an incompetent saphenous trunk treated with endovenous thermal or non-thermal ablation, concomitant tributary treatment should be considered, as part of a shared decision process.			
Class	Level	References	ToE
IIa	B	Vasquez <i>et al.</i> (2017), <sup>247</sup> Gibson <i>et al.</i> (2019), <sup>234</sup> Watanabe <i>et al.</i> (2020), <sup>311</sup> Aherne <i>et al.</i> (2020) <sup>309</sup>	

**4.6.5. Incompetence of other superficial veins.** The incorporation of routine DUS into modern treatment strategies has broadened the understanding of atypical reflux sources. To date prospective data examining their management is limited, with little therapeutic consensus.

**4.6.5.1. Giacomini vein.** The Giacomini vein is an inter-saphenous vein, representing a proximal extension of the SSV (or tributary) in the posterior thigh and draining into the cephalad GSV (Fig. 4). Intersaphenous veins have the potential to transmit truncal reflux both in an ascending and descending way. The largest retrospective series reported consisted of 39 limbs with Giacomini vein reflux treated with either EVLA or UGFS.<sup>312</sup> Incompetence of the Giacomini vein was associated with GSV and/or SSV incompetence in all but three limbs. All patients reported symptomatic improvements post-procedure with one UGFS related recurrence at one year. Alternative options include high ligation and stripping of the Giacomini vein; however, there are limited data on efficacy.

**4.6.5.2. Posterior accessory saphenous vein.** Ultrasound studies suggest a posterior accessory saphenous vein (PASV) (Fig. 4) is present in up to 54% of limbs with venous incompetence; however, it is itself only incompetent in 6%.<sup>313</sup> In a large prospective study, treatment of 117 incompetent PASVs with EVLA and UGFS resulted in 100% success at one year, with significant associated improvements in QoL.<sup>303</sup> Endovenous approaches for accessory veins are now widely advocated in place of HLS.<sup>210</sup>

**4.6.5.3. Straight tributary vein.** The ASVAL strategy, described in subsection 4.6.7.2, offers an effective means to treat extrafascial straight tributary veins by means of phlebectomies under local anaesthesia, similar to more tortuous varicose tributaries, with robust supporting data.<sup>314</sup> Indeed its efficacy has prompted the minimally invasive alternative eASVAL characterised by tributary EVLA (see subsection 4.3.3).

Retrospective data suggest that, in combination with EVLA of the GSV, tributary EVLA had similar rates of recurrence compared with AP.<sup>315</sup> Another study found lower recurrence rates and improved QoL after concomitant tributary UGFS when compared with tributary EVLA.<sup>252</sup>

**4.6.6. Perforating vein incompetence.** In an initial stage of CVD (C2 – C3), PVs may act as a re-entry point for superficial venous incompetence, and present a net inward flow during a compression-release manoeuvre.<sup>295</sup> In such cases, treatment of refluxing trunks and tributaries is usually sufficient, as re-entry PVs tend to become competent again after such treatment.<sup>316,317</sup> Treatment of PVs is only indicated in rare cases of isolated PV incompetence, directly responsible for clinically relevant VVs, such as those related to an incompetent midhigh PV of the FV or a popliteal fossa PV. Residual incompetent PVs, after previous truncal vein ablation, may be another indication for treatment, in particular in cases of skin changes. Also, in recurrent VVs treatment of incompetent PVs may be important (see subsection 4.7.3), and it is also an integral part of the CHIVA concept (see subsection 4.6.7.1).

Treatment of PV incompetence has been studied specifically when related to advanced skin changes (CVD clinical CEAP class C4b, C5) and in particular to VLU. Often, the term “pathological PVs” has been used, defined as those near or adjacent to a healed or open VLU demonstrating

reflux > 0.5 seconds and measuring ≥ 3.5 mm in diameter.<sup>318</sup> In a multicentre prospective cohort study, 125 pathological PVs were treated in 83 patients using 1470 nm EVLA (400 µm optical fibre), resulting in a 71.3% closure rate and good clinical results after 12 months.<sup>261</sup> A retrospective study suggested improved VLU healing associated with a combination of truncal and PV EVLA versus truncal ablation alone.<sup>253</sup> In a *post hoc* analysis of 97 patients undergoing surgery for both truncal and PV incompetence (including SEPS), as part of a RCT comparing surgery with conservative treatment,<sup>319</sup> the authors found more recurrent VLUs (C6r) in cases in which PV ligation or division had been incomplete.<sup>254</sup> However, it should be acknowledged that the role of SEPS for VLU treatment remains uncertain. In a Cochrane Database systematic review on this topic, only four mainly small and poorly reported RCTs could be included and the authors concluded that they were unable to determine the potential benefits and harms of SEPS.<sup>264</sup> Comparisons of treatment modalities for PV incompetence are scarce and no difference in VLU healing was found in a recent study.<sup>320</sup>

Recommendation 49			New
For most patients with varicose veins, without skin changes related to chronic venous disease, treatment of incompetent lower leg perforating veins is not recommended.			
Class	Level	References	
III	C	Consensus	

Recommendation 50			New
For patients with advanced skin changes (CEAP clinical class C4b, C5 or C6), with isolated or residual incompetent perforating veins, thought to be significant, treatment may be considered.			
Class	Level	References	ToE
IIb	C	Abdul-Haqq <i>et al.</i> (2013), <sup>253</sup> Kiguchi <i>et al.</i> (2014), <sup>263</sup> van Gent <i>et al.</i> (2015), <sup>254</sup> Gibson <i>et al.</i> (2020) <sup>261</sup>	

CEAP = Clinical Etiological Anatomical Pathophysiological (classification).

**4.6.7. Preservation of the saphenous trunk.** An improved understanding of flow dynamics, based on detailed DUS, has led to the emergence of saphenous sparing strategies to treat patients with varicose veins without removing or ablating the incompetent saphenous trunk: CHIVA, a French acronym for: “*Cure Conservatrice et Hémodynamique de l’Insuffisance Veineuse en Ambulatoire*” (conservative and haemodynamic treatment of venous incompetence in out-patients) and ASVAL (Ambulatory Selective Varicose vein Ablation under Local Anaesthesia).

**4.6.7.1. CHIVA.** The CHIVA strategy aims to re-route the venous circulation via minimally invasive interventions under local anaesthesia, with the objective of suppressing the

overloading flow/pressure, respecting the outflow that drains the tissues.<sup>321</sup> It is based on precise pre-operative DUS investigation to identify the particular haemodynamic pattern of venous incompetence and decide where specific reflux escape points have to be ligated and phlebectomies be performed (the latter only in certain cases). For instance, if the terminal valve of the SFJ and the GSV is incompetent, high ligation is performed at the SFJ to re-route the drainage of the incompetent saphenous trunk into the deep venous system via re-entry points.

In a 2021 Cochrane review, six RCTs were included with 1 160 participants, with a follow up of 1.5 – 10 years. Three RCTs compared CHIVA with HLS, two with EVTA (one RFA, one EVLA), and one study compared CHIVA with compression in patients with VLU.<sup>322</sup> The conclusion was that, based on this small number of trials, the CHIVA method may make little or no difference to the recurrence of VVs compared with HLS, RFA, or EVLA, and it was uncertain whether CHIVA reduced VLU recurrence compared with compression. It was acknowledged that results were imprecise because of the small number of events and that the risk of bias was high. To date no RCTs are available comparing CHIVA with non-thermal non-tumescent techniques.

Detailed DUS and proper understanding of the haemodynamic principles of the CHIVA method is of paramount importance to achieve good results. A single centre retrospective review of 1 489 patients treated for VVs showed that results were far worse than after stripping, if CHIVA was performed incorrectly, by inexperienced surgeons.<sup>323</sup>

Recommendation 51		Unchanged	
For patients with superficial venous incompetence requiring treatment, ambulatory conservative haemodynamic treatment of venous incompetence (CHIVA) may be considered, if performed by physicians experienced in this treatment strategy.			
Class	Level	References	ToE
I <b>b</b>	B	Bellmunt-Montoya <i>et al.</i> (2021) <sup>322</sup>	

CHIVA = ambulatory conservative haemodynamic treatment of venous incompetence in outpatients (= French acronym for ‘Cure Hémodynamique de l’Insuffisance Veineuse en Ambulatoire’).

**4.6.7.2. Isolated ambulatory phlebectomies or ASVAL.** The ASVAL method consists of single APs of incompetent varicose tributaries with preservation of the saphenous trunk, performed under local or tumescent anaesthesia in an ambulatory setting.<sup>324</sup> It is based on the concept of ascending or multifocal evolution of VVs (see subsection 1.3).

In a retrospective study of 221 patients, 303 limbs with VVs and incompetence of the GSV (86%), SSV (12%), or a

combination of both (2%) were treated with the ASVAL method. After four years follow up, 66% showed freedom of reflux, symptoms disappeared or improved in 78% of cases and VVs recurred in 11%.<sup>325</sup> According to a systemic review including 10 additional studies (a total of 2 106 limbs) with shorter follow up, varicosity recurrence at one year ranged from 0.5% to 13.5%. In 68.2% of limbs having GSV incompetence prior to intervention, GSV reflux was successfully abolished at one year. All studies measuring GSV diameter reported statistically significant reductions in vein size.<sup>326</sup>

Of note, patients with milder disease (C2 – C4a) are most likely to respond to ASVAL.<sup>314</sup>

Recommendation 52		Changed	
For patients with uncomplicated varicose veins (CEAP clinical class C2) requiring treatment, phlebectomies with preservation of the saphenous trunk (ASVAL) may be considered.			
Class	Level	References	ToE
I <b>b</b>	C	Pittaluga <i>et al.</i> (2009), <sup>325</sup> Biemans <i>et al.</i> (2014), <sup>314</sup> Richards <i>et al.</i> (2021) <sup>326</sup>	

CEAP = Clinical Etiological Anatomical Pathophysiological (classification); ASVAL = ambulatory selective varicose vein ablation under local anaesthesia.

**4.6.8. Special anatomical considerations**

**4.6.8.1. Very large saphenous trunks.** The definition of large GSV trunks varies in different studies and there is often confusion between focal (or segmental) dilatation and global truncal vein dilatation. Mentioned diameters of a large GSV trunk vary between > 8 mm (measured mid-thigh),<sup>47</sup> to > 15 mm (site of measurement not specified).<sup>327</sup>

In RFA and EVLA studies larger GSVs had lower rates of successful occlusion and higher rates of EHIT, although the latter conclusion was mainly based on multivariable analysis applied to retrospective findings (see subsection 4.2.1.5). For this reason, HLS was advocated, if the GSV diameter exceeded 12 – 15 mm. This has been questioned lately in studies where large GSVs have been successfully ablated with EVLA or RFA, with different suggested tumescence techniques, multiple probe passes, variable energy delivery, different thromboprophylaxis regimens, and early surveillance strategies for EHIT.<sup>327,328</sup> Therefore nowadays, EVTA should be considered for treating large saphenous trunks.

Recommendation 53		New	
For patients with an incompetent great saphenous vein with a very large truncal diameter (more than 12 mm), endovenous thermal ablation should be considered.			
Class	Level	References	ToE
I <b>a</b>	C	Dabbs <i>et al.</i> (2018), <sup>327</sup> Woo <i>et al.</i> (2019) <sup>328</sup>	

**4.6.8.2. Very superficial saphenous trunks.** When treating very superficial truncal veins ( $\leq 5$  mm from the skin), patients should be informed about the potential risk of hyperpigmentation and transient induration. The latter may even persist for a long time after EVTA or UGFS of very superficial saphenous trunks or tributaries outside the saphenous compartment, although it eventually disappears completely. Prevention of such complications mainly consists of optimising the dose of thermal energy or sclerosant. CAC has not been registered for treating tributaries. Caution is also warranted for saphenous trunk treatment with CAC in slim patients, because post-operative induration can be permanent. Phlebectomy may be a good alternative for very superficial veins.

**4.6.8.3. Saphenous trunks with intraluminal changes.** After SVT or previous sclerotherapy, residual intraluminal sequelae of thrombus or fibrotic synechiae may occur, rendering navigation with an intraluminal device more difficult or impossible. Pre-treatment DUS assessment of the trunk is mandatory and cannulation strategy may be adapted accordingly,<sup>141</sup> (see subsection 4.1.4). In case of difficult cannulation, UGFS with direct injection or a short cannula may be used.

**4.6.8.4. Saphenous trunk aneurysms.** A venous aneurysm (VA) of a saphenous vein has been defined as a local dilatation of the vein of at least three times the upper limit of the average diameter, or  $> 20$  mm, if close to the SFJ, or  $> 15$  mm, if close to the SPJ.<sup>329</sup> Superficial VAs of saphenous trunks are relatively rare and may be complicated by local thrombosis, in exceptional cases even causing PE. In the past, superficial VAs were always treated by open GSV, AASV, or SSV surgery. Recently, in a small prospective study, EVTA was used alone or combined with high ligation, the latter if the diameter of a saphenous VA close to the SFJ exceeded 30 mm, and was efficacious and safe.<sup>330</sup>

**4.6.8.5. Foot and ankle veins.** Foot and ankle veins are prone to reflux because of their distal position and limited number of valves. In patients with CVD, they typically present as VVs or corona phlebectatica (C4c) and may be complicated by skin changes, including VLU.

Isolated treatment of visible foot and ankle VVs only is usually not sufficient. Systematic assessment and treatment of the associated (more proximal) superficial venous incompetence is mandatory in these patients. Local treatment by means of phlebectomy, sclerotherapy, and ligation of foot PVs may be performed in combination with the main procedure or separately.<sup>331</sup> Caution is always warranted to avoid foot nerve injury during phlebectomy.<sup>332</sup>

**4.6.8.6. Unusual varicose vein locations.** Sometimes, VVs arise from unexpected anatomical locations. Imaging other than DUS might be useful to identify these rare sources of reflux. In a large series of 1 350 lower extremity VV cases evaluated by DUS and CT, 10.3% had an unusual site of reflux.<sup>333</sup> The most common were vulvoperineal 83.5% and round ligament VVs (5%), both related to pelvic venous incompetence (PVI) (see Chapter 7), followed by persistent sciatic vein incompetence (5%) and intraosseous PV incompetence (2.2%).

Sciatic vein incompetence can be either an isolated finding or associated with congenital venous malformations. It represents a form of developmental anomaly and is classified into three types based on its extent: complete (from the POPV to the IIV, traversing the sciatic notch), proximal (from the upper thigh to the pelvis, traversing the sciatic notch), or distal (confined to the middle and distal thigh, extending into the DFV or subcutaneous veins). Persistent sciatic vein incompetence below the knee easily can be mistaken for reflux of the SSV. The preferred treatment for sciatic vein incompetence is UGFS.

Intraosseous PVs are defined as abnormally large communicating veins between the superficial veins and the intra-osseous venous network, through a round shaped bone defect, usually on the anterior tibia. This defect can be seen on a plain Xray. CT or MR imaging can differentiate them from vascular malformations. Treatment usually by UGFS or phlebectomy of the varicose tributaries connected to the intraosseous PV, was found to be feasible and effective in a small case series (32 patients).<sup>334</sup>

**4.7. Recurrent varicose veins**

Recurrent VVs are a common and costly problem, with a negative impact on QoL. Recurrent VVs after surgery (REVAS)<sup>335</sup> have been defined as newly appearing clinically obvious VVs after HLS. This term has been replaced by PREVAIT (presence of varices after interventional treatment) to consider also recurrent VVs after endovenous interventions. The term PREVAIT aimed to include persistent VVs and newly appearing VVs, irrespective of the cause. However, in most scientific reports the simple term “recurrent VVs” usually encompasses all newly visible VVs and will therefore be further used in this subsection.

The preferred diagnostic approach to investigate clinically obvious recurrent VVs is DUS (see subsection 2.3.1.2). DUS is also used for follow up after interventions to look for recurrent reflux.<sup>16</sup> Such DUS detected reflux is not always accompanied by clinically manifest symptoms and signs; therefore it should be distinguished from recurrent VVs.<sup>336</sup> During the first year after the procedure, which is the short term follow up time, recurrent reflux is often subclinical and may only become clinically relevant after three to five years.<sup>337</sup> This explains why long term follow up is needed to evaluate

Recommendation 54			New
For patients presenting with foot and ankle varicose veins, phlebectomy, sclerotherapy, and foot perforating vein ligation may be considered during or after ablation of proximal reflux.			
Class	Level	References	ToE
IIB	C	De Roos <i>et al.</i> (1998), <sup>332</sup> Albernaz <i>et al.</i> (2018) <sup>331</sup>	



**Table 11. The main causes of varicose vein recurrence after treatment<sup>173</sup>**

Cause	Description
Tactical error	<i>Persistence of reflux because of an inappropriate intervention:</i> Inadequate pre-operative DUS, not identifying the source(s) of reflux Inadequate choice of cannulation site(s)
Technical error	<i>Persistence of reflux because of inadequate intervention</i> <i>for endovenous procedures:</i> Failure to cannulate target saphenous trunk Poor ultrasound visualisation of the target segment, the SFJ, or SPJ Insufficient delivery of energy/glue/sclerosant to target segment <i>for open surgical procedures:</i> Incomplete stripping Other surgical failure
Neovascularisation*	<i>Presence of multiple new small tortuous refluxing veins in anatomical proximity to a previous intervention:</i> Reflux from a previously ligated or ablated SFJ, SPJ, PV, or tributary New veins visible on DUS in connection with varicose veins
Recanalisation*	Partial or complete reopening of an initially ablated saphenous segment with recurrence of reflux
Disease progression*	Development of venous reflux as a result of the natural history and progression of disease, with reflux occurring at new sites

DUS = duplex ultrasound; SFJ = saphenofemoral junction; SPJ = saphenopopliteal junction; PV = perforating vein.

\* Defined by duplex ultrasound.

the clinical effectiveness of any intervention for superficial venous incompetence.

#### 4.7.1. Aetiology and risk factors

**4.7.1.1. Causes of recurrent varicose veins.** The sources of reflux responsible for recurrent VVs can be multiple.<sup>335</sup> The causes of recurrent VVs can be subdivided as represented in Table 11.

Although neovascularisation and recanalisation are different ultrasound features, both are based on similar biology of angiogenesis originating from vasa vasorum, to form new vessels.<sup>338</sup> This can occur in any venous segment. Neovascularisation, as diagnosed by DUS, typically occurs where the vein wall has been transected and the ends are reconnected by new vessels. Recanalisation occurs when the vein wall has been affected on its luminal aspect (e.g. by thermal or mechanical action, by sclerosant, or, by thrombus, in case of SVT) and new vessels grow within the treated vein. Each of these new intraluminal vessels remodel into larger tubes with demonstrable venous flow and some eventually become larger and develop reflux.

Two systematic reviews and meta-analyses reported that neovascularisation was the most common cause of recurrence after HLS whereas recanalisation was more common after endovenous ablation.<sup>177,202</sup> Progression of CVD (see subsection 1.1) may be multifocal and either ascending (superficial veins may dilate and become varicose) or descending (ongoing reflux causes more varicose veins). In addition, as a result of disease progression, incompetence

can also develop in a previously untreated saphenous trunk or in PVs.<sup>255</sup>

**4.7.1.2. Risk factors.** In addition to the aforementioned causes, underlying risk factors for persistent or recurrent disease are advanced age, female gender, prolonged standing, increased BMI, and previous recurrent disease.<sup>336</sup> Pelvic vein reflux has been identified as an important contributing factor to varicose vein recurrence (see Chapter 7). It is particularly common in multiparous women, although it may occur occasionally in men as well.<sup>339</sup> DVI cranially from the SFJ may also influence SFJ recurrence. A retrospective study reported that 27% of the patients who developed SFJ recurrence had pre-operative distal EIV and CFV incompetence cranial from the SFJ.<sup>340</sup>

The type of intervention has an impact on the likelihood of recurrence, although recurrence rates are largely comparable between HLS and EVTA.<sup>134,202,203</sup> Concomitant incompetence of the AASV, or its particular anatomy at the SFJ, may affect recurrence rate.<sup>134,174,176,177,341</sup> Venous obstruction or direct compression, secondary to DVT or pelvic pathology, respectively, also may contribute to VV recurrence.

**4.7.2. Prevention.** Regardless of the choice of intervention modality, detailed pre-operative DUS imaging has been shown to improve the results of VV surgery based on correct identification of incompetence in the GSV, AASV, and/or SSV system.<sup>43</sup> Traditionally, for HLS, flush ligation of the GSV is performed at its junction with the CFV, together with



ligation of all tributaries of the SFJ, to minimise the risk of groin recurrence.

To reduce the incidence of neovascularisation, several techniques have been investigated. A RCT proved that oversewing the SFJ stump to close the endothelial funnel and avoid contact with the surrounding subcutaneous tissue reduced the development of recurrent reflux.<sup>342</sup> Other studies reported good results of implantation of a prosthetic patch or closure of the cribriform fascia to contain neovascularisation at the SFJ.<sup>343,344</sup>

When EVTA is offered, meticulous ultrasound guidance is mandatory to reduce recurrence, similar to other techniques. The ablated length of GSV should be determined by the lowest refluxing tributary, with higher rates of re-intervention associated with inadequate ablation length.<sup>345</sup> However, in a minority of cases, GSV ablation in the calf may result in saphenous nerve injury and this risk must be considered carefully in the context of disease severity. In these cases, adjunctive below knee UGFS with above knee thermal ablation may reduce this risk.<sup>345</sup> Another approach is to use an alternative non-thermal technique, such as MOCA or CAC, if ablation below mid-calf is warranted. To minimise the risk of residual or newly developed reflux in SFJ tributaries and accessory veins (mainly the AASV), it has been proposed to position the tip of a radial laser fibre exactly at the SFJ (see [subsection 4.2.1.2](#)), but evidence about the benefits and safety of such strategy is still lacking.<sup>178</sup>

**4.7.3. Treatment.** In the past, recurrent VVs were mainly treated by redo open surgery. Open exploration of the groin or popliteal fossa through scar tissue takes longer and has a higher complication rate, as well as increased lymphatic leakage and wound infections; therefore, it should be avoided whenever possible.<sup>346,347</sup> A less invasive approach, such as EVTA or non-thermal ablation of an incompetent saphenous trunk, UGFS, or multiple phlebectomies without groin re-exploration, has been advocated to replace invasive redo surgery. These procedures are deemed to be safe and as effective as redo surgery.<sup>346</sup> To determine the most suitable technique, detailed DUS mapping is mandatory.

Several studies have described the use of EVTA as a safe and effective option for the treatment of recurrent VVs, in the presence of a recurrent or residual incompetent saphenous trunk.<sup>348–352</sup> A small RCT compared redo surgery with RFA and found that the latter was superior, with lower pain scores, bruising, and procedure times.<sup>351</sup> In two retrospective studies, in which EVLA of the GSV and the SSV was compared with open redo surgery, the re-recurrence and complication rates were lower in the EVLA groups.<sup>348,349</sup> In particular, sural nerve neuralgia was less common after EVLA than after SSV redo surgery (9% vs. 20%).<sup>348</sup>

UGFS is the most widely used treatment for all kinds of recurrent VVs, including VVs associated with incompetent PVs or lymph node venous networks<sup>16</sup> near the SFJ. The technique is minimally invasive, well tolerated by the patients, does not require anaesthesia, and can be repeated easily.<sup>353</sup> The reported success rates at one year follow up

range from 87% to 91% for recurrent saphenous truncal reflux.<sup>354</sup> In a large prospective cohort study, 142 cases of recurrent VVs related to groin neovascularisation, 155 inguinal recurrences related to residual SFJ stump, and 28 popliteal recurrences related to residual SPJ stump were treated with UGFS. After a mean follow up of 4.4 years, only 20% of treated patients had developed a new clinical recurrence.<sup>353</sup> In conclusion, UGFS is a widely applicable technique in patients with recurrent VVs, especially in the presence of neovascularisation and tortuous tributaries. Foam injections can be combined with other techniques (EVTA, phlebectomies) to eliminate multiple sources of reflux during the same session or subsequently.

Recommendation 55			Unchanged
For patients with symptomatic recurrent varicose veins due to saphenous trunk incompetence, endovenous thermal ablation or ultrasound guided foam sclerotherapy with or without phlebectomy should be considered.			
Class	Level	References	ToE
Iia	B	Hinchliffe <i>et al.</i> (2006), <sup>351</sup> Theivacumar <i>et al.</i> (2011), <sup>352</sup> van Groenendael <i>et al.</i> (2009), <sup>349</sup> van Groenendael <i>et al.</i> (2010), <sup>348</sup> Nwaejike <i>et al.</i> (2010), <sup>350</sup> Darvall <i>et al.</i> (2011) <sup>354</sup>	

Recommendation 56			Unchanged
For patients with symptomatic recurrent varicose veins requiring treatment, where endovenous ablation is possible, re-exploration of the groin or popliteal fossa is not recommended.			
Class	Level	References	ToE
III	B	Hinchliffe <i>et al.</i> (2006), <sup>351</sup> van Groenendaal <i>et al.</i> (2009), <sup>349</sup> van Groenendaal <i>et al.</i> (2010) <sup>348</sup>	

Recommendation 57			New
For patients with symptomatic recurrent varicose veins without truncal incompetence, ultrasound guided foam sclerotherapy and/or ambulatory phlebectomy should be considered.			
Class	Level	References	ToE
Iia	C	Consensus	

**5. INTERVENTIONS FOR DEEP VENOUS PATHOLOGY**

Deep vein reflux and/or obstruction results in a considerable burden to patients and healthcare systems. Initial therapy should usually start with non-invasive treatment, the cornerstone being compression therapy. If there is no clinical improvement, invasive treatment options may be considered.<sup>355,356</sup> An appropriate assessment with confirmation of clinically significant deep vein reflux and/or

obstruction is a prerequisite before starting any type of treatment.<sup>357</sup>

The largest group of patients eligible for deep venous interventions include those who suffer from PTS, although patients with a non-thrombotic iliac vein lesion (NIVL) may be included too.<sup>355</sup>

### 5.1. Post-thrombotic syndrome

PTS is a set of symptoms and signs of CVD, caused by impaired venous outflow as a result of deep venous obstruction and/or reflux following a DVT. Typical symptoms are pain, heaviness, fatigue, itching, cramping, and venous claudication. Typical signs are pain with calf compression, VVs, oedema, and skin changes including VLU. Progress and deterioration may present over time. Several clinical tools and scales are available for the diagnosis and severity of PTS but there is no gold standard diagnostic test. This syndrome occurs in 20% – 50% of DVT patients, of whom 5% – 10% develop severe PTS, including VLUs. Although it usually occurs within the first three to five years after DVT, PTS can occasionally manifest itself even after 10 – 20 years. Diagnosis cannot be confirmed until at least three months after an acute DVT, to rule out ongoing post-DVT symptoms. PTS patients have a lower QoL compared with DVT patients without PTS, as well as being a higher burden on the healthcare system because of high medical costs, absence from work, and unemployment.<sup>358</sup>

Risk factors for development of PTS after a DVT are increased BMI, older age, smoking, pre-existing superficial venous incompetence, iliofemoral and/or ilio caval DVT, recurrent ipsilateral DVT, residual venous symptoms and signs one month after the DVT, residual deep venous obstruction, persistent elevation of D dimer, and subtherapeutic anticoagulation.<sup>358</sup> Prevention of PTS mainly consists of optimising anticoagulant treatment, thrombus removal strategies in selected cases, and adequate compression treatment with below knee ECS.<sup>2</sup> In patients with PTS conservative treatment is the first option and consists of supervised exercise training, compression treatment, usually with below knee ECS, and pharmacotherapy (see Chapter 3). In carefully selected cases, endovenous or surgical techniques (as described in this chapter) may be indicated.<sup>358</sup>

### 5.2. General principles

**5.2.1. Specialised care.** Ideally, invasive treatment should be performed in centres with a high level of expertise, after carefully weighing the pros and cons of intervention, given the considerable learning curve associated with these procedures.

**5.2.2. Anaesthesia.** Recanalisation of obstructed deep veins may take time, and venous dilation and stenting is painful. This should therefore be done under sedation, combined with intravenous analgesia in patients with a NIVL, and under general anaesthesia in patients with post-thrombotic fibrotic lesions, which require a more complex procedure

(sometimes combined with endophlebectomy in the groin, see subsection 5.3.2.7). Interventions for deep vein reflux are delicate and time consuming, and should be performed under general anaesthesia.

**5.2.3. Compression after treatment.** Leg compression is usually prescribed after deep venous procedures but there are scarce data on its effectiveness. However, compression therapy is recommended when symptoms persist after invasive treatment (see subsection 3.2 and Fig. 6).

### 5.3. Treatment of chronic deep venous obstruction

**5.3.1. Indications for treatment.** Treatment of asymptomatic individuals, even with high grade stenosis or occlusion, is not supported by any robust evidence that suggests this reduces the risk of subsequent DVT or PE.

In symptomatic patients, the indications to treat CVD by endovascular recanalisation vary between studies. Clinical selection and reporting of patients has usually been based on the CEAP classification, the Villalta scale and the r-VCSS (see subsection 1.5).<sup>359</sup> The clinical class C3 – C6 of the CEAP classification at baseline is the most commonly used criterion for considering intervention. Second, the Villalta scale has become the gold standard used to diagnose PTS and is therefore also used for selection of patients with moderate (Villalta score 10 – 14) or severe PTS (Villalta score  $\geq 15$ , or VLU). Venous claudication, usually described as heaviness and pain during exercise subsiding during rest, is a non-objective and poorly validated symptom.<sup>32</sup> It is not included in formal scoring systems, but it may be one of the most meaningful indications for intervention in chronic outflow obstruction.

In addition to clinical assessment, arbitrary cutoff values on venography, CTV, MRV, and/or IVUS, most often of at least 50% lumen narrowing, have been used.<sup>359–361</sup> Plethysmographic methods have been used in some centres to identify patients who would benefit from deep venous stenting, but these are still debated.<sup>362–364</sup>

**5.3.2. Iliocaval and iliofemoral obstruction.** Both intra- and extraluminal causes of ilio caval and iliofemoral outflow obstruction can be treated by endovascular procedures. In some exceptional cases, only the IVC is obstructed. This may be post-thrombotic or result from “congenital absence” of the IVC (also known as vena cava atresia). The latter may also be caused by DVT in the neonatal period or at a very young age. Even in such cases, recanalisation may be possible, although this can be a very challenging procedure.

**5.3.2.1. Technical considerations of recanalisation and stenting.** Although indications for treatment have not reached consensus, treatment technique and approach are fairly uniform. Specific details include characteristics and sizes of devices used for recanalisation. Ultrasound guided access can be achieved from a leg vein or the internal jugular vein. In the leg, the tip of the sheath should be caudal to the confluence of the DFV and the FV, to allow concomitant treatment of the CFV. The obstruction is crossed with a hydrophilic wire and a supporting catheter. It

should always be checked that the wire courses ventral from the lumbar spine into the IVC, to avoid passing into spinal collateral veins. The use of IVUS during the procedure, to determine the extent of the lesion and guide stent placement, should be considered. Self expanding stents should land in healthy segments above and below the lesion. Pre- and post-dilation is mandatory, using a non-compliant balloon with the same diameter as the stent. Final multiplanar venography is performed to visualise rapid wash out of contrast, with disappearance of collateral veins. Used directly after stenting, IVUS is also effective in detecting residual stenoses.

Although data are scarce, the general consensus is that percutaneous transluminal angioplasty alone is not sufficient to treat large vein obstruction because of frequent immediate elastic recoil of the treated vein segment and therefore stenting is usually needed. The most commonly used stent sizes are 20 – 24 mm for the IVC, 14 – 16 mm for the iliac veins, and 12 – 14 mm for extension into the CFV. Stenting should not be restricted to the anatomical level of the inguinal ligament if post-thrombotic sequelae continue down into the CFV compromising stent inflow. However, stent extension below the major confluence of the FV and DFV should be avoided as far as possible.<sup>365</sup> Nevertheless, in severe PTS with extensive iliofemoral obstruction, stent extension into a single inflow vein may be a valuable option.<sup>366</sup>

**5.3.2.2. Post-operative surveillance.** Post-operative surveillance after deep venous interventions is of key importance. A baseline DUS is required on the first day after the procedure. Because a thrombosed stent can be recanalised with thrombolysis within 14 days of the thrombotic event, and most thrombotic complications occur shortly after the intervention, a second ultrasound should be performed within two weeks after stent placement. Further follow up visits are scheduled at six weeks, three and six months, and yearly.<sup>367</sup> If symptoms recur, patients should be instructed to contact their vascular specialist as soon as possible. A suspected stenosis of > 50% diameter reduction or occlusion on ultrasound warrants immediate further evaluation and consideration of treatment. In a case control study of 120 patients, the performance of various duplex parameters for detecting venous stent obstruction, confirmed by biplane venography or IVUS was tested. The most effective parameter was the combination of peak flow velocity and flow pattern analysis at the stent inlet. A peak flow velocity > 10 cm/s and a flow pattern spontaneously modulated by respiration ruled out venous stent obstruction with a specificity of 93.7% (95% CI 86.0% – 97.3%). A peak flow velocity ≤ 10 cm/s or any Doppler flow pattern other than spontaneously modulated by respiration resulted in a sensitivity of 92.1% (95% CI 79.2% – 97.3%) to detect venous stent obstruction or occlusion.<sup>368</sup>

**5.3.2.3. Outcome of recanalisation and stenting.** The results of endovascular treatment of CVD are difficult to interpret, categorise, and appraise because of heterogeneity across trials and reports. Multiple systematic reviews concluded that the available data quality is weak.<sup>355,369</sup> The

heterogeneous nature of most studies is one of the major challenges, with multiple classification systems and different treatment criteria, as discussed above, being a top concern. Furthermore, heterogeneous populations of patients such as those with a NIVL and/or (sub-)acute DVT, are pooled with those with chronic post-thrombotic obstructions. Iliocaval occlusions are mixed with iliofemoral stenoses. Variable and largely poorly defined confounders impact outcome measures such as technical success and primary patency. This is further complicated by variable and often suboptimal imaging protocols that add to the poor identification of obstructive lesions and unclear patient selection. From the available data, however, it can be concluded that patency after NIVL treatment approximates to 95% – 100% and is superior compared with adequate post-thrombotic recanalisation with patency rates of 70% – 80%, after at least six months of follow up,<sup>369</sup> or a median follow up of 23.5 months.<sup>355</sup> The main related factor is the quality of the inflow vessels.

Clinical outcome results are even more difficult to appraise. While significant reductions in r-VCSS and Villalta score have been reported, multiple studies mention less specific outcomes like “oedema relief”, “alleviation of symptoms”, and “some” or “partial improvement”, which have no objective definition. In a minority of studies this improvement was related to venous claudication, which is also not clearly defined. On the other hand, VLU healing is a significant outcome variable with lack of consistent reporting. Again, the quality of the data is poor, with a wide range of ulcer healing and recurrence (56% – 100% and 0% – 17%, respectively).<sup>369,370</sup> Finally, QoL has been measured with a variety of scoring systems, for example, SF-36, CIVIQ-20, and VEINES-QOL/Sym. The reported results suggest an improvement in QoL after successful intervention.<sup>356</sup>

Currently, there are no reliable data to suggest superiority of any on label venous stents over the previously used stents to treat chronic venous outflow obstruction.<sup>355</sup> Further studies are required to identify which stents perform better in the long term.

In conclusion, even though several studies suggest a relative benefit from endovascular treatment of CVD, all of these studies, including a RCT comparing iliac vein stenting with medical treatment,<sup>356</sup> have essential systematic errors, predominantly patient selection and treatment selection bias. Nevertheless, these studies support a role for endovascular treatment in patients with chronic venous outflow obstruction when selection of these patients is appropriate.

**5.3.2.4. Indications for re-intervention after stenting.** It is important to emphasise that careful case selection for the primary procedure, with consideration of anatomical and patient related (e.g., haematological) factors is imperative to prevent complications that may require re-interventions. In patients with advanced CVD, occlusion of venous stents is a significant problem as both repeat recanalisation and surgical bypass alternatives pose significant challenges.

Indications for re-intervention include acute in stent thrombosis needing restoration of patency; symptomatic in stent thrombus lining/stenosis; complications of deep venous

stenting (such as stent migration or contralateral thrombosis); and residual obstructive disease (inflow, in stent or outflow) that may compromise future stent patency.

In addition, there may be haematological or other patient related factors contributing to stent failure, which also need to be recognised and addressed for optimal outcomes. In a systematic review, including 3 072 patients in which standard stents were used for post-thrombotic obstruction or NIVL, the median primary, assisted primary, and secondary patency rates were 71%, 89%, and 91%, respectively, with a median study follow up of 23.5 months.<sup>355</sup> In a meta-analysis of iliofemoral stenting for PTS in 504 limbs, 36 month primary and secondary patency were 68% and 86%, respectively, showing that a significant minority of patients required at least one re-intervention over a three year period.<sup>370</sup> In another series, the re-intervention rate was 43%, with a median time to re-intervention of 32 days (range 0 – 520 days).<sup>371</sup> The majority of these patients had only a single re-intervention and achieved good patency at two years with significant symptom improvement.

Re-intervention for asymptomatic in stent re-stenosis is controversial because of a lack of evidence to support better outcomes. In selected cases with symptomatic in stent re-stenosis, conservative measures or extended anticoagulation may also be a valid treatment option. There is only sparse evidence that prophylactic intervention can reduce future thrombosis risk in these patients.

**5.3.2.5. Options for re-intervention after stenting.** The vast majority of reported re-interventions after deep venous stenting have been performed for acute stent thrombosis or in stent stenosis. The principles of management for acute thrombosis should mirror the management of primary acute DVT.<sup>2</sup> Patients with stent thrombosis will often present with significant swelling and pain, and therefore early thrombus removal strategies have to be considered. Departments with experience in deep vein recanalisation and stenting procedures must carry out the interventions if needed. A detailed description of thrombus removal options is beyond the remit of these guidelines, but the mainstays of treatment are endovenous pharmacomechanical, pure thrombectomy, and catheter directed thrombolysis interventions.<sup>2</sup> It is important to recognise that, after successful thrombus removal, adequate treatment of any underlying obstructive disease is imperative to prevent re-thrombosis. Generally, attempts at deep venous stent recanalisation, when occluded for more than two weeks, are unlikely to be successful or durable.

For the treatment of symptomatic stenosis, venoplasty or additional stenting may be feasible. A mild degree of in stent thrombus lining is common, which complicates identification of an aetiology and a prolonged venoplasty may be required. For re-intervention for inflow or outflow disease, it is possible to perform additional stenting to comply with the principle of stenting from “good inflow vein” to “good outflow vein”.

**5.3.2.6. Surgical reconstruction.** Surgical reconstruction of the ilio caval vessels is performed rarely. Thus, reliable data on indications and outcomes are scarce. The main difficulty is result assessment of the different surgical strategies in

terms of symptom relief, long term patency, and risk factors for procedural failure. Recent studies present heterogeneous patient selection and difficult comparative analyses.

The most well known surgical technique is the Palma bypass graft, initially performed in 1958, for unilateral iliac occlusion.<sup>372</sup> This procedure uses autologous vein or a prosthetic graft, mainly expanded polytetrafluoroethylene. Smaller series have been published in which prosthetic and autologous vein grafts have been used in either anatomical or extra-anatomical configurations to bypass occluded iliac and ilio caval segments. These studies reported high variability and induced considerable controversy.<sup>373</sup>

The published long term patency (five year) for the Palma technique reports a patency between 70% and 85%, as well as clinical improvement of 63% – 88% after reconstruction.<sup>374</sup> This is superior to other bypass graft configurations, including caval-iliofemoral bypass.

The use of an adjunctive arteriovenous fistula (AVF) is a controversial topic with pros and cons discussed in experimental and clinical reports.<sup>375,376</sup> There is insufficient evidence to make strong recommendations, but an AVF may be considered for patients with insufficient inflow, who may struggle to keep the graft open.

Overall, there is a lack of strong evidence supporting the benefits of surgical reconstruction. It must be considered in exceptional cases such as major disease with no other treatment alternatives, especially patients with C4 – C6 disease, severe PTS, and/or disabling venous claudication with daily activity limitations. Endovascular techniques should be the first treatment option.

**5.3.2.7. Hybrid procedures.** Chronic iliac occlusive disease (stenosis or occlusion) can be treated by venoplasty and stent in the majority of cases where intervention is required.<sup>365</sup> However, the literature suggests worse outcomes in disease with CFV compromise, possibly related to insufficient stent inflow and subsequent higher rates of thrombosis. Additional complications may occur because of absence of any identifiable “landing zone” secondary to obstruction by residual luminal trabeculations.

Iliac vein stenting could be combined with surgical removal of the obstructive element from the CFV, its tributaries, and especially the DFV orifice. The latter technique is known as endophlebectomy.<sup>377,378</sup> In conjunction with iliac vein stenting, it provides adequate inflow by securing supply from all major side branches of the CFV, thereby reducing the risk of early stent thrombosis.

The endophlebectomy literature provides limited evidence and high variability.<sup>379–381</sup> The largest published series reports on 157 patients with a cumulative patency of 89% at 12 months.<sup>382</sup> However, the majority of published patency rates are about 60%, with high complication rates in terms of infection, seroma, lymph leak, and haematoma occurring in up to 40% of cases.

The heterogeneity of the published data makes interpretation difficult. There are no clear criteria for case selection, with widely variable decisions on what constituted severe enough disease to warrant this more invasive



intervention. However, endophlebectomy has been recommended for healing VLU.<sup>383</sup>

There are no RCTs and only limited heterogeneous case series, therefore any substantial recommendation either in favour of or against endophlebectomy is not possible. Based on the literature these procedures should be performed only in patients with significant disease and severe symptoms/signs (VLU, severe PTS, and disabling venous claudication with no alternative intervention).

### 5.3.3. Femoropopliteal obstruction

**5.3.3.1. Endovenous recanalisation.** A patent FV and POPV are helpful to ensure enough inflow into the iliac veins and prevent early occlusion after iliac recanalisation. It can therefore be assumed that it may be beneficial to perform an angioplasty with or without stent placement in segments of the FV to increase iliac vein stent patency in post-thrombotic cases. Limited data on concomitant disobliteration of the FV during iliac vein stenting does not support this assumption.<sup>384</sup> Nevertheless, in severe PTS with extensive iliofemoral disease, stent extension into a single inflow vein may be a valuable option to support stent patency and improve symptoms.<sup>366</sup>

Recanalisation of an isolated chronically occluded FV and POPV as a stand alone intervention, especially with a patent DFV has not been recommended.<sup>385</sup> However, one study demonstrated benefits of femoropopliteal recanalisation by percutaneous transluminal angioplasty, supported by ultrasound assisted thrombolysis. Both PTS related clinical outcome and disease specific QoL improved significantly, irrespective of additional iliac vein stenting.<sup>386</sup> Recommendation of these techniques for clinical practice requires stronger evidence.

**5.3.3.2. Surgical reconstruction.** Surgical options for reconstruction of an occluded femoropopliteal system are extremely limited. The only operation described in any detail is the May-Husni procedure, which is designed to relieve unilateral FV outflow obstruction by ipsilateral saphenous vein transposition to the distal FV or POPV.<sup>387</sup> In many cases, this may also include some form of endophlebectomy of the POPV. Obstruction is relieved by re-routing blood flow through the GSV, which subsequently drains the calf.

The data available for patency at long term follow up are variable but this appears to be around 50%. Despite this low patency rate, clinical improvement appears to be better than patency rates.<sup>388</sup> There is a lack of data on either positive or negative outcomes, not allowing for any recommendation regarding surgical reconstruction of the occluded femoral segment.

**5.3.4. Antithrombotic treatment.** Peri- and post-operative antithrombotic treatment is crucial, but the use of the various regimens is heterogeneous among studies.<sup>355</sup> Neither type of anticoagulation nor duration have been studied prospectively. In a single centre retrospective study of 154 PTS patients undergoing iliofemoral venous stenting,

rivaroxaban exhibited similar safety but superior efficacy to warfarin.<sup>389</sup> Close collaboration with a haematologist is often warranted, to decide on an individualised anti-thrombotic treatment strategy.

Patients on anticoagulants should be bridged to LMWH pre-operatively and continue treatment after the procedure. Peri-operatively, all patients should be adequately heparinised. Patients on indefinite anticoagulation (vitamin K antagonists or DOACs) before the procedure, should continue anticoagulation after the procedure, unless major bleeding complications occur. If there is no indication for indefinite anticoagulation, post-operative anticoagulation should be prescribed, but there is insufficient evidence to guide decision making regarding the optimum duration. According to experts participating in a Delphi consensus, anticoagulant treatment should be continued for at least six months after intervention in patients with a history of DVT. Regarding the role of antiplatelets, no consensus was reached.<sup>390</sup>

In addition to antithrombotic treatment, use of an IPC during and immediately after the procedure, and early mobilisation may help to reduce thrombotic complications after deep venous interventions but, as with the above strategies, there is a paucity of evidence. Also, in patients undergoing stenting for NIVL, there is a lack of evidence to guide antithrombotic strategies and hence no particular strategy can be recommended.

**5.3.5. Safety issues.** Peri-operative death and PE are extremely rare after deep venous interventions and reports of this complication are sparse. The overall rate of complications was 3% in one study involving almost 4 000 stented limbs.<sup>355</sup> Complications include access site haematoma, stent migration or fracture, iliac vein rupture, stent thrombosis, and contralateral DVT. The incidence of contralateral DVT varies from 0% to 15.6% among studies. It usually results from stenting into the IVC, which is often unavoidable, thereby jailing the contralateral iliac vein.<sup>391</sup>

**5.3.6. Multidisciplinary team.** It is strongly suggested that patients undergoing intervention for iliac venous obstruction, in particular those with PTS, are managed within a multidisciplinary team. This team should consist principally of an interventional radiologist, a vascular surgeon, and a haematologist (with a specified interest in thrombosis). Other specialists may be added to the team as necessary.

Recommendation 58		Unchanged	
For patients with iliac vein outflow obstruction and severe symptoms/signs, endovascular treatment should be considered, as the first choice treatment.			
Class	Level	References	ToE
Ila	B	Neglen <i>et al.</i> (2007), <sup>365</sup> Seager <i>et al.</i> (2016), <sup>369</sup> Rossi <i>et al.</i> (2018), <sup>356</sup> Williams <i>et al.</i> (2020) <sup>355</sup>	



Recommendation 59			New
For patients with iliac vein outflow obstruction undergoing endovascular treatment, the use of intravascular ultrasound should be considered to guide treatment.			
Class	Level	References	
IIa	C	Consensus	

Recommendation 60			Changed
For patients with iliac vein outflow obstruction suffering from a recalcitrant venous ulcer, severe post-thrombotic syndrome, or disabling venous claudication, surgical or hybrid deep venous reconstruction may be considered when endovascular options alone are not appropriate.			
Class	Level	References	ToE
IIb	C	Dumantepe et al. (2020) <sup>382</sup>	

Recommendation 61			New
For patients with iliac vein outflow obstruction, without severe symptoms, neither endovascular nor surgical interventions are recommended.			
Class	Level	References	
III	C	Consensus	

Recommendation 62			New
For patients undergoing either endovascular or surgical reconstruction of iliac vein outflow obstruction, duplex ultrasound surveillance is recommended one day and two weeks after the intervention, and at regular intervals thereafter.			
Class	Level	References	
I	C	Consensus	

Recommendation 63			New
For patients with iliac vein outflow obstruction, management by a multidisciplinary team is recommended.			
Class	Level	References	
I	C	Consensus	

**5.4. Treatment of deep venous incompetence of the lower limbs**

DVI may be treated surgically if, in patients without outflow obstruction, or with previously corrected outflow obstruction, conservative management of deep venous incompetence (DVI) of the lower limbs has failed and severe symptoms and signs of CVD persist. Only patients with axial reflux from the level of the thigh, across the POPV and into the calf veins, are considered for intervention.<sup>392</sup> The diagnosis of DVI can be made initially with DUS, but when planning an intervention, descending venography (see subsection 2.5.1) may be useful to confirm the presence and extent of axial reflux. If so, valvuloplasty or transposition of the FV can be performed. Other options for reconstruction

are transplantation of a vein segment with a competent valve (usually the axillary vein) or creation of a neovalve from the thickened vein wall or a prosthetic artificial valve.<sup>393</sup>

The evidence for the long term benefits of open interventions is poor. Most publications are single centre retrospective studies that are heterogeneous and of poor quality because they employ a variety of surgical techniques and there is selective reporting of the outcomes (including complication rates). Often there is only a short term follow up.

A Cochrane review identified four RCTs in patients with primary valvular incompetence in which valvuloplasty with superficial venous surgery was compared with valvuloplasty without superficial venous surgery.<sup>394</sup> In view of the poor quality of these trials, no conclusions could be drawn. There were no trials available including patients with post-thrombotic valvular incompetence. Overall, ulcer free rates after open valve reconstructions for DVI vary between 54% and 100% up to five years, but this could also be attributed to treatment of superficial reflux or compression therapy applied in some of these patients. As no comparative studies have been performed, it is not possible to make any recommendations on selecting between the different types of surgery for DVI.

Recommendation 64			Unchanged
For patients with extensive axial deep venous incompetence and severe persistent symptoms and signs, where previous management has failed, surgical repair of valvular incompetence may be considered in specialised centres.			
Class	Level	References	ToE
IIb	B	Goel et al. (2015) <sup>394</sup>	

**5.5. Combined superficial and deep venous pathology**

The presence of concomitant deep and superficial venous pathology is commonly perceived as a relative contraindication to superficial venous intervention. This is particularly apparent in patients with a history of DVT, in whom treating physicians incorrectly perceive that ablation of refluxing superficial veins will further impair venous drainage and exacerbate the symptoms of CVD.

First, it is important to distinguish between reflux and obstruction in the deep venous system. In the presence of combined superficial and deep vein reflux, it is always possible to treat superficial reflux. Moreover, in as many as 50% of cases, superficial vein treatment may result in correction of segmental deep venous reflux.<sup>395</sup> The VCSS has been found to improve substantially after EVLA of incompetent saphenous veins in patients with combined superficial and deep vein reflux.<sup>396,397</sup>

In the group of patients with superficial reflux in the presence of deep vein obstruction. the GSV rarely functions as a collateral. Moreover, it does not contribute to leg drainage if there is reflux in the GSV. Therefore, in this group, the principal decision is to evaluate whether the GSV is playing any role in limb drainage. This can be achieved either through DUS in experienced hands, or through venography

by performing runs with and without a tourniquet and assessing the drainage pattern. Air plethysmography may also be useful to quantify the contribution of the GSV to the venous drainage of the limb, with and without GSV occlusion. If there is no significant drainage via the GSV (see subsection 2.7), it can be ablated without risk of compromising venous drainage of the limb. However, ablation of a competent, often very large GSV with antegrade flow, may worsen the situation by compromising venous outflow of the leg in case of femoropopliteal occlusion. For iliac or iliofemoral occlusion, the cranial extent of ipsi- or contralateral GSV ablation may have to be limited to preserve inflow and outflow of cross pubic collateral circulation.<sup>398</sup>

Recommendation 65			New
<b>In patients with chronic venous disease, caused by combined superficial and deep venous incompetence, treatment of incompetent superficial veins should be considered.</b>			
Class	Level	References	ToE
IIa	C	Knipp <i>et al.</i> (2008), <sup>396</sup> Marston <i>et al.</i> (2008) <sup>397</sup>	

### 5.6. Aneurysms of the deep veins

Aneurysms of the deep veins are defined as isolated dilations of at least twice the normal vein diameter. In the extremities, the most common are popliteal VAs, which can be either fusiform or saccular in shape. The diagnostic tool of choice is DUS performed in the standing position.<sup>399</sup>

Popliteal VAs may be asymptomatic or cause only local complaints because of the mass effect. However, if they thrombose, they may also cause DVT and PE.<sup>400</sup> Older age, aneurysm diameter > 20 mm, and the presence of turbulent flow in the aneurysm were found to increase the risk of DVT and PE.<sup>399</sup>

There is no clear consensus on treatment strategies for popliteal VAs. Surgical treatment options consist of tangential resection of the aneurysm with venorrhaphy, resection with end to end anastomosis or interposition of a graft, and patch venoplasty, depending on the size and shape of the aneurysm. This is usually advised for large saccular popliteal VAs and fusiform VAs (> 20 mm), or those containing thrombus, irrespective of size. Alternatively, a conservative approach of lifelong anticoagulation can be considered. For smaller popliteal VAs, clinical surveillance with yearly DUS may be sufficient and ECS can be advised for oedema.<sup>399</sup>

Recommendation 66			New
<b>For patients with a popliteal vein aneurysm with thromboembolic complications or those that are saccular, fusiform exceeding 20 mm, or containing thrombus, surgical repair should be considered.</b>			
Class	Level	References	ToE
IIa	C	Sessa <i>et al.</i> (2000), <sup>401</sup> Bergqvist <i>et al.</i> (2006), <sup>400</sup> Noppeney <i>et al.</i> (2019) <sup>399</sup>	

### 5.7. Popliteal venous entrapment

Some patients may suffer from clinical features not related to valvular incompetence or intraluminal obstruction of the POPV, but to extrinsic compression. Parallel to the popliteal artery entrapment syndrome, this has been called POPV entrapment syndrome (PVES). This is a rare entity, in which compression of the POPV in the popliteal fossa, mainly by surrounding musculotendinous structures, occurs to a degree sufficient to cause signs and symptoms, such as leg oedema and pain below the knee associated with prolonged standing or exertion, or venous claudication. PVES rarely occurs in isolation but often presents simultaneously with arterial compression. Individuals with anatomical variations of the gastrocnemius muscle or popliteus hypertrophy are predisposed to PVES.<sup>402</sup> Athletes may be at increased risk, especially in sports with exertion of the triceps surae.<sup>403</sup>

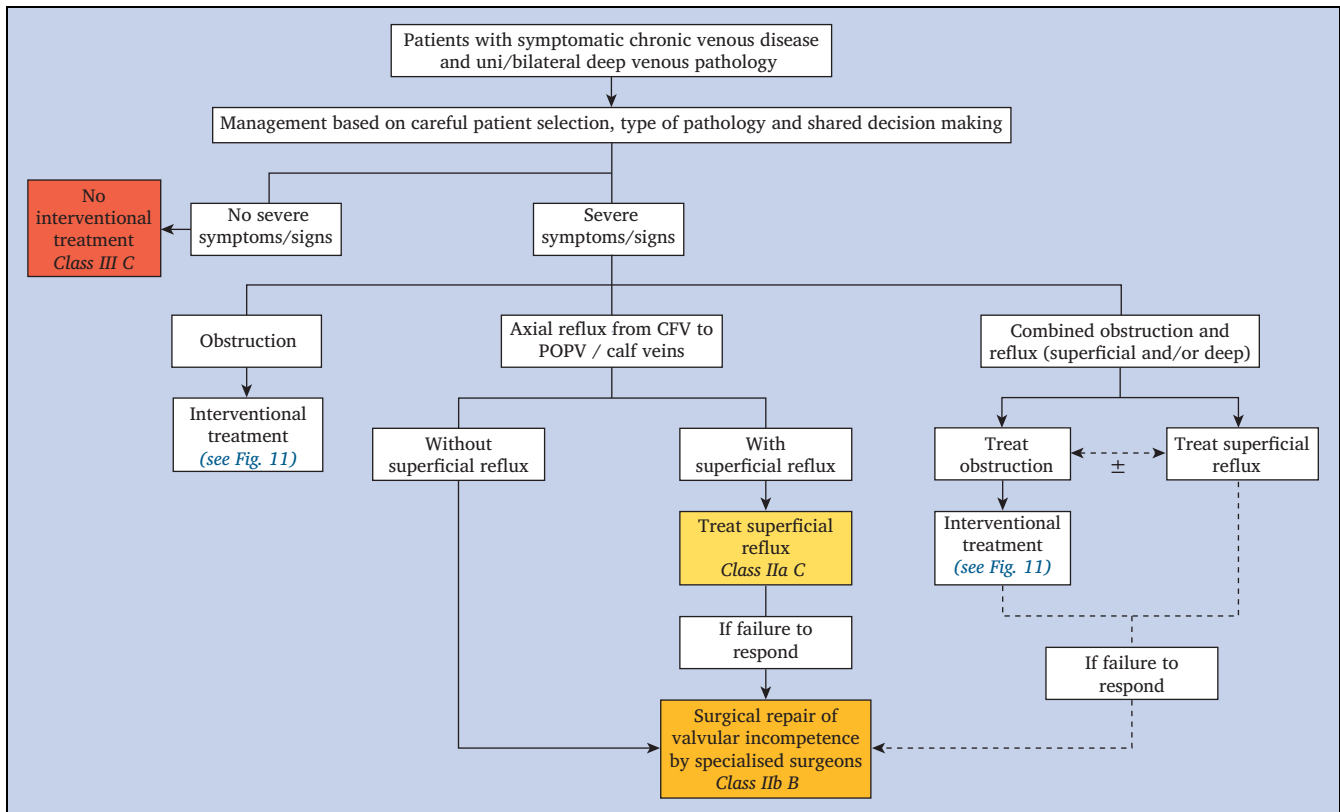
As part of a systematic review on popliteal entrapment syndrome, four of the 44 included studies described patients with PVES. The median age was 28 years (range 27.6 – 43.6 years) with a female predominance (median 73%, range 53% – 100%).<sup>402</sup> PVES presents with symptoms and signs typical of chronic venous hypertension in the absence of venous reflux, venous obstruction, or primary calf pump dysfunction, although it may ultimately lead to a DVT. The popliteal compartment pressure may increase as shown in a study in which with knee extension the median popliteal compartment pressure in PVES patients was 53 cm H<sub>2</sub>O (range 38 – 76) compared with 26 cm H<sub>2</sub>O (range 17 – 43) in controls (*p* < .001). This study also found that BMI was higher in patients with PVES (32 kg/m<sup>2</sup>, range 26–45.8) compared with controls (28 kg/m<sup>2</sup>, range 19–31, *p* = .050) Obesity may increase the popliteal compartment pressure while standing because of the presence of a larger popliteal fat pad, compared with patients with a lower BMI.<sup>404</sup>

DUS, dynamic venography, and MRV are modalities to diagnose PVES. At rest, the POPV shows no abnormalities, unless there are signs of chronic venous injury. Provocation with ankle movements (active ankle plantar flexion and passive ankle dorsiflexion with full knee extension) during imaging, should elicit evidence of POPV compression.

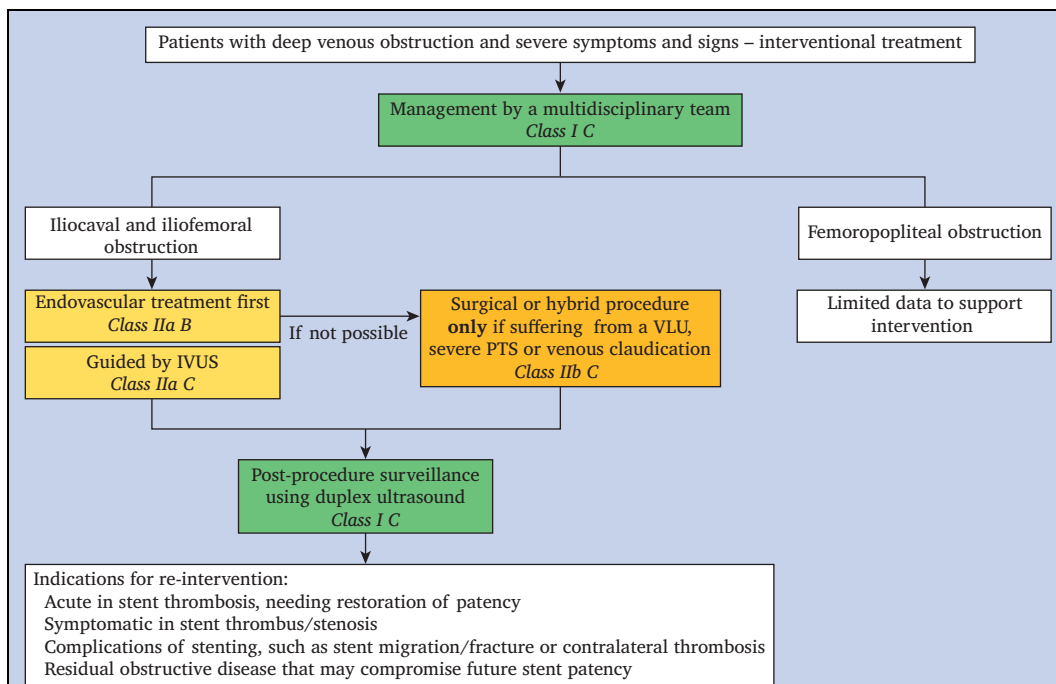
PVES can be treated conservatively (compression stockings and leg elevation) or, for severe symptoms and/or signs of venous hypertension, by decompressive surgery (fasciotomy with or without musculotendinous section), with or without POPV reconstruction.

### 5.8. Interventional treatment strategy for deep venous pathology

The management strategy for patients with deep venous disease can be divided into treatment(s) for those suffering from obstruction, axial reflux (from CFV to POV or calf veins) or a combination of obstruction and reflux (superficial and deep) (Fig. 10). It is essential that attention is paid to the presenting symptoms and signs (see subsection 5.3.1) and ensuring that only patients with severe, disabling symptoms and/or signs genuinely attributable to deep venous disease



**Figure 10.** Management strategy for patients with symptomatic deep venous obstruction, venous reflux, or a combination of both – general overview. CFV = common femoral vein; POPV = popliteal vein.



**Figure 11.** Management strategy for interventional treatment in patients with chronic venous disease of the lower limbs and severe outflow obstruction. IVUS = intravascular ultrasound; VLU = venous leg ulcer; PTS = post-thrombotic syndrome.

are considered for intervention. Careful patient counselling regarding long term risk and benefit are essential, particularly in patients with PTS, in whom the results may be worse.

Management strategies for patients with deep venous obstruction are summarised in Fig. 11. Selecting a treatment strategy is often challenging in patients with combined deep venous obstructive disease and superficial venous incompetence (with or without deep venous reflux). There is little consensus in the literature regarding in which order to treat these patients and therefore it is important to tailor the treatment to each individual patient,<sup>405</sup> and to adequately discuss the pros and cons with the patient, as part of a shared decision making process. There may be a trend towards favouring treating deep venous outflow obstruction first, followed by correction of superficial venous reflux, but this can also be done in reverse order (see subsection 6.5, in case of VLUs). Finally, deep venous reflux should be treated only in patients who fail to respond to the above two interventions.<sup>406</sup>

Broadly, failure of stenting can be divided into three categories: technical, haematological, and flow related. When considering why a stent has failed, this serves as a framework to allow for correction and ultimately achievement of the goal of long term patency. Technical failure is probably the single largest cause of early stent failure. In the majority of cases, failure is a result of inadequate inflow treatment by not extending the stent caudally enough to manage disease in the CFV or not extending the stents cranially enough to treat outflow disease. Failure may also occur as a consequence of stent fracture. In these cases, stent extension or relining may be required.

Antithrombotic strategies are vital after stent placement to reduce the risk of early stent thrombosis, although there is no consensus as to the optimal regimen. This is especially important in the context of acute and chronic post-thrombotic disease.<sup>2</sup> Although the importance of anticoagulation may be less in patients with NIVL, early stent thrombosis has still been reported, and these patients also need to be provided with a plan for anticoagulation or antiplatelets. In patients with stent thrombosis, evaluation of patient compliance with anticoagulation and an assessment of anticoagulation adequacy is vital, especially if re-intervention is performed.

Flow is the single most difficult factor to account for, and in many respects, this becomes more of an issue of patient selection. It is increasingly apparent from data analysis that patients with normal inflow to the CFV and good flow into the stents are more likely to do well regardless of the length of the stent cranial to this.<sup>371</sup> The remaining options for improving inflow are to consider an endophlebectomy and AVF or a stent extension into a single inflow vein.

Finally, only those patients with extensive axial deep venous incompetence and severe persistent symptoms and signs, in whom all previous treatment strategies have failed, eventually may be referred to a specialised centre, for surgical repair of valvular incompetence.

## 6. MANAGEMENT OF VENOUS ULCERATION

### 6.1. General principles

Active VLU is the most severe manifestation of CVD, classified as CEAP clinical class C6. There may be multiple contributing factors (including venous reflux, outflow obstruction, calf muscle pump failure, and obesity) causing chronic venous hypertension. VLUs represent a considerable economic burden on healthcare services. The prevalence of VLU is around 1% of the population, rising to 3% for those > 80 years of age.<sup>407</sup> Up to 93% of VLUs will heal in 12 months, with 7% remaining unhealed after five years,<sup>408</sup> although real world outcomes are likely to be inferior. Furthermore, the recurrence rate within three months after wound closure is as high as 70%.<sup>409,410</sup> Therefore, well organised services and cost effective treatment strategies are needed to prevent VLU, facilitate healing when they occur and prevent recurrence.<sup>411</sup>

**6.1.1. Specialist care.** In recent years, the trend towards a multidisciplinary approach to chronic wound care has led to better diagnostic procedures and clinical outcomes.<sup>412</sup> The introduction of a systematic approach to wound management in 2003, known as the “TIME” (*Tissue, Infection/inflammation, Moisture balance and Edge of wound*) concept, has been considered a potentially useful tool.<sup>413,414</sup> Despite a lack of RCTs, the TIME principles are widely adopted for the treatment of VLUs.

**6.1.2. Pain control.** Pain is a significant complaint for patients with VLUs. Patients most commonly describe wound related background pain and pain related to dressing changes and wound procedures.<sup>415</sup> A pain assessment should include location, severity, quality/characteristics, frequency, and timing. Triggers, effective relievers, and the impact of pain on QoL and functional ability should also be recorded. There are several pain assessment tools in use but the visual analogue scale (VAS) is the most often applied.<sup>411</sup> A recent meta-analysis of 36 publications showed that the prevalence of wound related background pain in patients with VLUs (from 10 studies) was 80% (95% CI 65% – 92%) and the mean pain intensity score (from 27 studies) was 4 (95% CI 3.4 – 4.5) on a 0 – 10 VAS scale.<sup>416</sup> A systematic review found no trials evaluating interventions for persistent pain in VLU patients.<sup>417</sup> However, a eutectic mixture of local anaesthetic (EMLA cream) was found to be superior to placebo in controlling pain during wound debridement (mean difference –20.65 on a 100 mm VAS, 95% CI –12.19 – –29.11). In terms of general principles, the three step analgesic ladder developed by the World Health Organization for management of cancer and chronic pain is an effective approach.<sup>415</sup>

**6.1.3. Antibiotics and antiseptics.** Colonisation of VLUs by bacteria is common and of little clinical significance, but the presence of infection may delay ulcer healing. Systemic antibiotics and topical antibiotics or antiseptics have been proposed for treatment of clinical infection in VLUs. The evidence from a Cochrane review suggests that routine use



of systemic antimicrobials is not beneficial for VLUs.<sup>418</sup> In terms of topical preparations, there is no evidence to support the efficacy of topical antibiotics. Therefore, the practice of taking routine bacteriological swabs from leg ulcers is not recommended. The pooled estimate from 11 RCTs showed that more VLUs healed when treated with topical cadexomer iodine (an antiseptic) compared with the standard care at four to 12 weeks (RR 2.17, 95% CI 1.30 – 3.60). Systematic reviews have also suggested that silver dressings (with recognised antimicrobial effects) may increase the probability of VLU healing (RR 2.43, 95% CI 1.58 – 3.74),<sup>419</sup> although further studies evaluating time to complete wound healing (rather than healing rate) are needed.<sup>420</sup>

**6.1.4. Mobilisation and physical therapy.** The aim of mobilisation and physical therapy in patients with VLUs is to decrease venous hypertension and oedema (see subsection 3.1). This can be achieved through activation of the calf muscle pump by specific exercises of the ankle or by biomechanical stimulation of the calf muscle pump. Although beneficial in principle, studies demonstrating improved VLU healing or reduction of recurrence rate with exercise or specific physical therapy are scarce.

**6.1.5. Comorbidities.** Patients with VLUs are often elderly and co-existent comorbidities are common.<sup>421</sup> Ankle stiffness (resulting in calf muscle pump failure) and obesity are common causes of venous hypertension (see subsections 3.1 and 8.2.1, respectively). Optimisation of systemic medical issues should be considered to promote wound healing. The presence of lower extremity atherosclerotic disease is particularly relevant, so a basic assessment of arterial status (continuous wave Doppler, to measure ankle pressure and ABI) should be performed. An ABI > 0.8 may be considered as normal and allows commencement of full compression therapy.<sup>422</sup> In patients with diabetes and incompressible arteries, evaluation using arterial DUS or toe pressure may be required to exclude arterial disease. Modified compression may be beneficial in patients with mixed arterial and venous ulceration (see subsection 6.3.3).

<b>Recommendation 67</b>		<b>Unchanged</b>	
For patients with active venous leg ulceration without infection, the use of local or systemic antibiotics to improve ulcer healing is not recommended.			
<b>Class</b>	<b>Level</b>	<b>References</b>	<b>ToE</b>
III	B	O'Meara et al. (2014) <sup>418</sup>	

<b>Recommendation 68</b>		<b>New</b>	
For patients with active leg ulceration, objective arterial assessment is recommended.			
<b>Class</b>	<b>Level</b>	<b>References</b>	
I	C	Consensus	

**6.2. Wound care**

Chronic wound care should be delivered by appropriately trained specialist nurses or wound care professionals, working as part of a multidisciplinary team. Evaluation of a VLU should include location (gaiter area, malleolar area), ulcer size (depth), amount and type of exudate (mild to severe), appearance of the ulcer bed (irregular in shape), condition of the wound edge (attached, rolled), signs of clinical infection, and changes to the surrounding skin.<sup>423</sup> Wound bed preparation aims to convert the biology of a chronic wound to that of an acute healing wound.

**6.2.1. Debridement.** Wound debridement describes the removal of necrotic tissue, debris, or foreign bodies from a wound.<sup>424</sup> It should be preceded by wound cleansing, defined as the “removal of surface contaminants, bacteria and remnants of previous dressings from the wound surface and its surrounding skin”.<sup>425</sup> Methods for wound debridement include:

- surgical/sharp debridement
- mechanical debridement (washing solutions, whirlpool therapy, wet to dry dressings, ultrasound assisted debridement and lavage)
- enzymatic debridement (topical application of enzymes breaks down the tissue attaching necrotic tissue to the wound bed)
- autolytic debridement (application of dressings facilitates development of the body’s own enzymes to rid a wound of necrotic tissue)
- biosurgical debridement (sterile larvae).

A Cochrane review identified 10 RCTs involving 715 participants with VLUs and several debridement strategies were studied.<sup>426</sup> The authors concluded that there was limited evidence that active debridement of a VLU has a significant impact on healing. However, this conclusion was based on low quality (and quantity) evidence, so larger trials are required.

**6.2.2. Dressings and topical agents.** A large number of types of wound dressings are in current use for VLUs. A recent Cochrane review and network meta-analysis included 59 RCTs (5 156 participants) and concluded that more research is needed to evaluate whether VLU healing is improved by any particular dressings or topical agents.<sup>419</sup> Similarly, another Cochrane review including 12 studies of protease modulating matrix treatment concluded that the quality of evidence was too low to demonstrate whether ulcer healing or adverse events are influenced by this local treatment.<sup>427</sup> Despite this, specific dressings are likely to be useful in management of specific wound characteristics (such as excessive exudate). There is a lack of reliable evidence supporting the use of hyperbaric oxygen therapy to improve VLU healing.<sup>428</sup>

### 6.2.3. Other wound therapies

**6.2.3.1. Therapeutic ultrasound.** A Cochrane review has been updated recently and 11 studies were included with 969 participants.<sup>429</sup> It remains unclear whether therapeutic ultrasound (either high or low frequency) improves VLU healing, and the review authors suggest that any effect is likely to be small.

**6.2.3.2. Electromagnetic therapy.** The effects of electromagnetic therapy (EMT) on VLU were studied in three RCTs involving a total of 94 patients. All the trials compared the use of EMT with sham EMT. Meta-analysis of these trials was not possible because of heterogeneity so the effects of EMT have yet to be established through high quality RCTs.<sup>430</sup>

**6.2.3.3. Negative pressure wound therapy.** There is no RCT evidence of the effectiveness of negative pressure wound therapy as a primary treatment for VLU. There is some evidence that the treatment may reduce time to healing as part of a treatment that includes a punch skin graft transplant. However, the applicability of this finding may be limited by the very specific context in which negative pressure wound therapy was evaluated.<sup>431</sup>

## 6.3. Compression

Compression therapy is the mainstay of conservative VLU treatment, as it is effective in compressing leg veins and soft tissues, improving venous haemodynamics, and therefore reducing the effects of venous hypertension. Compression therapy has been shown unequivocally to improve VLU healing compared with no compression,<sup>432</sup> and to reduce pain.<sup>433</sup>

**6.3.1. Compression materials.** Compression for VLU treatment can be applied by means of ECS, superimposed ECS, elastic bandages and IB, ACG, and IPC (see subsection 3.2). Superimposed ECS are mainly used for small VLUs (area < 5 cm<sup>2</sup>). The inner stocking keeps the ulcer dressing in place and is removed only at dressing changes. It can be worn day and night, as the sustained low pressure of 20 mmHg is well tolerated, even in the supine position. The second stocking exerting 20 – 25 mmHg is worn on top of the inner stocking during the daytime. The complete kit exerts a pressure of around 40 mmHg in the supine position rising to almost 50 mmHg in upright position, which is useful to promote VLU healing. Inelastic bandages are mostly applied as multi-component, multilayer bandages, which are superimposed. This makes the final bandage totally inelastic, according to objective measurements. The best indicator of the elastic characteristics of a compression system is the “static stiffness index” (SSI), which is obtained by calculating the difference between standing and supine pressure (in mmHg).<sup>434</sup> The SSI of IB is always > 10 mmHg, while elastic material shows a SSI < 10 mmHg. The SSI of the so called “four layer” bandages (consisting of four elastic bandages) appeared to be in the range of IB (> 10 mmHg).<sup>435</sup> This is

mainly because of the friction produced by superimposing the four components of this multicomponent, multilayer bandage (resulting in more than 10 layers if applied properly).

In recent years, ACG have increased in popularity, also for patients with VLU, and could represent an increasingly interesting option for the future. ACG are manufactured with inelastic material and are similar to IB in terms of pressure and stiffness. While applying ECS, superimposed ECS or ACG is relatively simple, wrapping IB in the correct way providing the necessary strong pressure is not easy.<sup>436</sup> For IB, the compression pressure is not determined by the material, but depends on the stretch applied during bandaging and on how the different turns are superimposed.

### 6.3.2. Haemodynamic and clinical effects in patients with venous leg ulceration.

Inelastic materials have been shown to be more effective than elastic materials in reducing venous reflux and increasing venous pump function, thereby improving venous haemodynamics.<sup>437</sup> Inelastic compression by multicomponent, multilayer bandages or ACG, exerting a high pressure  $\geq 40$  mmHg,<sup>438–440</sup> should be applied in VLU treatment. In small VLUs, superimposed ECS may be a good alternative, as was obvious from a large RCT, including 457 participants with VLU, randomised between superimposed ECS and four layer bandage.<sup>440</sup> In this study, the median ulcer area was small (3.9 cm<sup>2</sup>, interquartile range [IQR] 1.6, 8.7) and the median ulcer duration was four months (IQR 2, 11 months). Median time to ulcer healing was 99 days (95% CI 84 – 126) in the superimposed ECS group and 98 days (95% CI 85 – 112) in the bandage group.

ACG can be applied with high pressure and high stiffness and are haemodynamically very effective as they are able to maintain their compression pressure. When compared with IB, ACG were demonstrated to be even more effective for VLU healing.<sup>441,442</sup> ACG are also more cost effective and have the advantage of allowing self management.<sup>442</sup>

IPC increases VLU healing compared with no compression but was not shown to be more effective than other compression modalities when used as single treatment. There is limited evidence, based on a small RCT, demonstrating that IPC may improve the VLU healing rate when used in addition to standard compression.<sup>443</sup> In clinical practice, IPC is used in VLU treatment as a single treatment or in association with other kinds of compression. It is mainly indicated when other compression methods cannot be applied because of problems with patient compliance or because they fail to improve VLU healing.

### 6.3.3. Treatment of mixed venous and arterial ulcers.

In about 15% – 20% of VLU, the patients also suffer from arterial disease of the affected leg, with an ABI < 0.8.<sup>444,445</sup> The role of compression therapy for patients with ABI < 0.8 is controversial as there is thought to be a greater risk of iatrogenic skin damage with the use of compression therapy

in the presence of arterial disease. However, it has been demonstrated that modified compression therapy, using short stretch material with a pressure  $\leq 40$  mmHg, is very effective in obtaining healing of a mixed ulcer, provided the absolute value of the ankle pressure is  $> 60$  mmHg, the toe pressure  $> 30$  mmHg and the ABI  $> 0.6$  (see contraindications for compression, Table 7). If these conditions are respected, mixed ulcers eventually heal, although with some delay compared with VLUs.<sup>446,447</sup> Close clinical supervision is mandatory when using compression therapy in patients with mixed arterial and venous disease and compression should be discontinued immediately if ulceration deteriorates or if the leg is very painful after applying the bandage. For an ankle pressure  $< 60$  mmHg, a toe pressure  $< 30$  mmHg, or an ABI  $< 0.6$ , sustained compression therapy should be avoided in most cases and arterial revascularisation should be considered.<sup>444</sup>

**6.3.4. Prevention of ulcer recurrence.** For the majority of VLU patients, correction of superficial venous incompetence (see subsection 6.4) and/or underlying deep venous pathology (see subsection 6.5) are essential tools to prevent VLU recurrence. Alternatively, a conservative approach, consisting of compression therapy using below knee ECS may be useful to prevent ulcer recurrence. The higher the compression pressure, the lower the ulcer recurrence rate;<sup>448</sup> however, it should also be acknowledged that the higher the pressure, the lower the compliance.<sup>90</sup> It has been reported that the lowest VLU recurrence rates were seen in patients who were compliant with hosiery regardless of the compression level.<sup>449</sup>

Recommendation 69		Unchanged	
For patients with active venous leg ulceration, compression therapy is recommended to improve ulcer healing.			
Class	Level	References	ToE
I	A	O'Meara et al. (2012) <sup>432</sup>	

Recommendation 70		Changed	
For patients with active venous leg ulceration, multilayer or inelastic bandages or adjustable compression garments, exerting a target pressure of at least 40 mmHg at the ankle, are recommended to improve ulcer healing.			
Class	Level	References	ToE
I	A	O'Meara et al. (2012), <sup>432</sup> Dolibog et al. (2014), <sup>439</sup> Mosti et al. (2020) <sup>442</sup>	

Recommendation 71		New	
For patients with active venous leg ulceration, superimposed elastic compression stockings exerting a target pressure up to 40 mmHg at the ankle should be considered for small and recent onset ulcers.			
Class	Level	References	ToE
Ila	B	Jünger et al. (2004), <sup>450</sup> Ashby et al. (2014) <sup>440</sup>	

Recommendation 72		New	
For patients with active venous leg ulceration, with ankle pressure less than 60 mmHg, toe pressure less than 30 mmHg, or ankle brachial index lower than 0.6, sustained compression therapy is not recommended.			
Class	Level	References	ToE
III	C	Consensus	

Recommendation 73		Unchanged	
For patients with active venous leg ulceration, intermittent pneumatic compression should be considered when other compression options are not available, cannot be used, or have failed to promote ulcer healing.			
Class	Level	References	ToE
Ila	B	Dolibog et al. (2014), <sup>439</sup> Alvarez et al. (2020) <sup>443</sup>	

Recommendation 74		New	
For patients with a mixed ulcer caused by coexisting arterial and venous disease, modified compression therapy under close clinical supervision, with a compression pressure less than 40 mmHg may be considered, provided the ankle pressure is higher than 60 mmHg.			
Class	Level	References	ToE
Iib	C	Mosti et al. (2016), <sup>446</sup> Stansal et al. (2018) <sup>447</sup>	

Recommendation 75		New	
For patients with healed venous leg ulceration, long term compression therapy should be considered to reduce the risk of ulcer recurrence.			
Class	Level	References	ToE
Ila	B	Clarke-Moloney et al. (2014), <sup>449</sup> Milic et al. (2018) <sup>448</sup>	

**6.4. Treatment of superficial venous incompetence**

**6.4.1. Rationale for superficial venous interventions in venous ulceration.** Chronic venous hypertension is accepted as the underlying pathophysiological cause of the skin damage that results in VLU with several potential contributing factors. General measures such as effective compression and elevation are important and should be advised wherever possible. However, superficial venous reflux is a very common finding and is usually an important factor contributing to venous skin damage, even in the presence of other pathologies. Several RCTs have demonstrated clinical advantages (improved VLU healing and reduced recurrence) with treatment of superficial venous reflux in patients with VLU.<sup>451,452</sup> There is a clear logic to treatment of the underlying cause of the chronic venous hypertension. Randomised studies have shown that improved outcomes after treatment of superficial reflux are seen, even when concomitant deep venous reflux is

present, indicating that deep reflux should not be considered a contraindication to superficial venous intervention.<sup>451,452</sup>

**6.4.2. Timing of interventions.** For patients with VLUs and superficial venous reflux, it would seem logical to address the underlying pathophysiology as soon as possible to deliver maximum clinical benefit. However, the evidence to support this rational strategy has been lacking until recently. In the multicentre “Early Venous Reflux Ablation” (EVRA) study, 450 participants with VLUs (between six weeks and six months duration) and superficial venous reflux were randomised to compression with early endovenous reflux ablation within two weeks, or compression with deferred ablation of superficial reflux, once the ulcer had healed. Early endovenous ablation accelerated VLU healing with 24 week healing rates of 85.6% and 75.4% in early and deferred intervention groups, respectively ( $p < .001$ ).<sup>451</sup> These findings suggest that prompt ablation of superficial reflux reduces venous hypertension over and above compression therapy alone. Long term findings showed that overall ulcer recurrence was lower in the early intervention group.<sup>453</sup> It should be noted that patients in the EVRA trial had ulcers of less than six months duration and trial participants had a high level of compliance with compression therapy, which is not usually the case in real world practice. However, most would argue that for patients with chronic VLU of greater than six months duration, or those unable to tolerate compression therapy, aggressive and early ablation of the underlying pathological reflux is even more important.

Other RCTs have also evaluated the clinical benefits of superficial venous intervention in patients with VLU. In the ESCHAR trial (Effect of Surgery and Compression on Healing and Recurrence trial), 500 patients with active, or recently healed, VLU were randomised to compression alone, or compression with open superficial venous surgery. Surgical interventions were performed at a median of seven weeks post-randomisation and, although there was no difference in VLU healing rates, lower VLU recurrence rates were seen in the intervention group (four year VLU recurrence rates of 31% vs. 56%). Other studies including patients with VLU, e.g.; the Dutch SEPS<sup>319,454</sup> and USABLE<sup>455</sup> trials, also demonstrated excellent outcomes after intervention for superficial reflux, although there were no statistically significant benefits when compared with compression alone.

In many healthcare systems, VLU care is delivered mainly in primary care settings, without easy or prompt access to tools for assessment or treatment of venous disease. Therefore, a pragmatic approach should be adopted where assessment and ablation of superficial venous reflux are performed as quickly as possible, and ideally within two weeks.

**6.4.3. Choice of superficial venous intervention.** As described in Chapter 4, there are a large number of endovenous and surgical treatment modalities for the ablation of refluxing superficial veins. In the ESCHAR trial, traditional superficial venous surgery (including SFJ/SPJ ligation alone) were used. In the Dutch SEPS trial, a combination of open surgery and SEPS were performed. In recent years, open surgical interventions have been superseded by endovenous interventions. These minimally invasive procedures, performed using tumescent anaesthesia alone, can be used for the entire population with VLUs. In the EVRA study, only endovenous ablation procedures (thermal ablation, non-thermal ablation or UGFS) were allowed. The choice of modality was left to the discretion of the treating physician. Subgroup analyses showed similar healing improvements irrespective of the modality. Therefore, selection of endovenous intervention should be guided by physician skill/experience and patient choice (see subsection 4.6).

The management of incompetent PVs in patients with VLUs is a source of considerable controversy and variation in practice (see subsection 4.6.6). It is common to identify pathological PVs in limbs with C6 disease, usually in combination with truncal saphenous reflux. In the ESCHAR trial, the superficial venous intervention targeted the truncal saphenous reflux only. In the EVRA study, no specific perforator interventions were performed, although most participants were treated with UGFS, so some perforators may have been ablated indirectly. There are no RCTs demonstrating additional benefit from concomitant PV intervention, although persisting incompetent PVs were associated with recurrent ulceration in one study with 10 years follow up.<sup>454</sup> To date, the experience with endovenous treatment of PV incompetence (mainly of PVs close to the diseased skin), in combination with truncal thermal ablation, remains limited in patients with VLU.<sup>253,261</sup> Although there may be a pragmatic logic to aggressive intervention for incompetent PVs, such interventions may be challenging, evidence for the additional benefit of PV ablation (over and above truncal ablation) is weak and previous guidelines only offer minor support for such an approach.<sup>383</sup>

**6.4.4. Treatment of the sub-ulcer venous plexus.** The frequent presence of a leash of small, incompetent tributaries under a VLU has led to the hypothesis that this plexus of veins plays an important role in transmitting the venous hypertension to the soft tissues and skin, directly contributing to ulceration. Ablation of this venous plexus using foam sclerotherapy has been proposed as a logical approach and has been used in isolation,<sup>456–458</sup> or in combination with saphenous vein ablation procedures.<sup>451,459</sup> Even if UGFS of the sub-ulcer venous plexus is a commonly used approach in clinical practice, well



performed studies clearly demonstrating its additional benefit are lacking.

Recommendation 76 <span style="float: right;">New</span>			
For patients with active venous leg ulceration and superficial venous incompetence, early endovenous ablation is recommended to accelerate ulcer healing.			
Class	Level	References	ToE
I	B	Gohel <i>et al.</i> (2018) <sup>451</sup>	

Recommendation 77 <span style="float: right;">New</span>			
For patients with superficial venous incompetence and healed venous leg ulceration, treatment of the incompetent veins is recommended to reduce the risk of ulcer recurrence.			
Class	Level	References	ToE
I	A	Gohel <i>et al.</i> (2007), <sup>452</sup> Gohel <i>et al.</i> (2020) <sup>453</sup>	

Recommendation 78 <span style="float: right;">New</span>			
For patients with active venous leg ulceration, ablation of the sub-ulcer venous plexus using ultrasound guided foam sclerotherapy should be considered as part of the treatment strategy.			
Class	Level	References	ToE
Iia	C	Bush <i>et al.</i> (2010), <sup>456</sup> Bush <i>et al.</i> (2013), <sup>457</sup> Kamhawy <i>et al.</i> (2020) <sup>458</sup>	

Recommendation 79 <span style="float: right;">New</span>			
For patients with superficial venous incompetence and active or healed venous leg ulceration, treatment of incompetent superficial veins is recommended, even in the presence of deep venous incompetence.			
Class	Level	References	ToE
I	A	Gohel <i>et al.</i> (2007), <sup>452</sup> Gohel <i>et al.</i> (2018) <sup>451</sup>	

Recommendation 80 <span style="float: right;">New</span>			
For patients with active venous leg ulceration as a result of superficial venous incompetence and perforating vein incompetence close to the ulcer, concomitant treatment of both truncal reflux and incompetent perforators may be considered.			
Class	Level	References	ToE
Iib	C	Abdul-Haqq <i>et al.</i> (2013), <sup>253</sup> van Gent <i>et al.</i> (2015), <sup>254</sup> Gibson <i>et al.</i> (2020) <sup>261</sup>	

### 6.5. Treatment of deep venous pathology

Patients with VLUs may have either superficial or deep vein pathology, or a combination of both. It is important that in patients with VLUs both the superficial and the deep venous system are examined, and the latter is checked for reflux as well as obstruction. This examination should not

only involve the legs, but also the pelvic and abdominal veins (see Chapter 2 and Fig. 5).

Treatment of the deep veins consists of correcting obstruction or reflux. Iliocaval and iliofemoral obstruction can be corrected with endovascular or open surgical interventions (see subsection 5.3). Surgery to correct deep vein reflux is performed more rarely (see subsection 5.4). Available data on VLUs do not describe the involvement of each system separately, and iliocaval venous imaging has often not been performed. Also, there is conflicting evidence regarding the relative role of obstruction and reflux as PTS predictors.<sup>460</sup> In patients with VLUs with reflux in addition to iliocaval and/or iliofemoral obstruction, it is therefore difficult to determine the best treatment strategy.

A prospective cohort of 192 patients with VLUs were treated by the following algorithm: 1) incompetent saphenous vein ablation only if the vein diameter was  $\geq 5$  mm and no features of iliac vein obstruction, 2) iliac vein stenting plus saphenous ablation if the vein diameter was  $< 5$  mm or features of iliac vein obstruction were considered dominant, 3) iliac vein stenting only if there was no saphenous reflux and demonstrated iliac vein obstruction. Residual deep reflux was not treated. Long term VLU healing at five years was overall 75%, with no differences between the three groups. Residual reflux did not influence VLU healing.<sup>405</sup> In a retrospective cohort, patients with C1 – C6 disease and both CIV compression and superficial venous incompetence were offered iliac vein stenting plus EVLA. In 121 patients, combination treatment was performed, while 86 patients refused a stent and served as controls. They were treated with EVLA only. During a mean follow up of 5.9 years, in the stent plus EVLA group, a VLU was present in 15.7% before and in 2.0% of patients after treatment ( $p = .001$ ). In the EVLA only group, this was 12.8% before and 5.9% after treatment ( $p = .15$ ).<sup>359</sup> There is one RCT comparing iliac vein stenting with conservative treatment. In this study, 51 patients with a  $> 50\%$  stenosis on IVUS were randomly assigned to treatment with a stent or conservative treatment. This RCT did not specifically study patients with VLUs but included patients with C3 – C6 disease and hence there were too few patients with C6 disease to draw firm conclusions.<sup>356</sup> In a systematic review consisting of no RCTs, and all but two retrospective studies, 3 812 stented limbs from 23 studies were analysed. The VLU healing rate was 71% in the stented limbs.<sup>355</sup> There are no data on the effect of surgery for DVI with respect to VLU healing.

Recommendation 81 <span style="float: right;">New</span>			
For patients with active or healed venous leg ulceration and iliac vein outflow obstruction, venous stenting should be considered.			
Class	Level	References	ToE
Iia	B	Raju <i>et al.</i> (2013), <sup>405</sup> Yin <i>et al.</i> (2015), <sup>359</sup> Williams <i>et al.</i> (2020) <sup>355</sup>	

### 6.6. Pharmacotherapy

The effects of VADs on venous symptoms and oedema were discussed in Chapter subsection 3.3. Some of these drugs have also been investigated in VLU treatment. MPFF was assessed in a meta-analysis, which demonstrated a statistically significantly higher chance of VLU healing at six months, which was 32% more frequent in patients treated with MPFF as an adjunctive treatment compared with compression and local therapy alone.<sup>461</sup> Similar results were reported by a 2013 Cochrane review, which reported a risk ratio of 1.37 for VLU healing and also better ulcer area reduction in two RCTs;<sup>462</sup> however, some methodological issues were detected.

Hydroxyethylrutosides (HR) were evaluated by three placebo controlled RCTs as an adjunctive treatment compared with compression and wound care alone, corresponding to a pooled risk ratio of 1.7 for VLU healing.<sup>462</sup> Meta-analysis of three sulodexide RCTs suggested an increase in the proportion of VLUs completely healed with sulodexide as an adjuvant to compression therapy and wound care compared with compression and wound care alone (rate of complete healing with sulodexide 49% compared with 30% with local treatment alone; risk ratio 1.66).<sup>463</sup> In a systematic review, pentoxifylline was found to promote VLU healing compared with placebo or no treatment in terms of complete VLU healing, or ulcer improvement > 60% (risk ratio 1.70).<sup>464</sup>

Recommendation 82		Unchanged	
<p><b>For patients with active venous leg ulceration, micronised purified flavonoid fraction, hydroxyethylrutosides, pentoxifylline, or sulodexide should be considered, as an adjunct to compression and local wound care to improve ulcer healing.</b></p>			
Class	Level	References	ToE
Iia	A	Coleridge-Smith <i>et al.</i> (2005), <sup>461</sup> Jull <i>et al.</i> (2012), <sup>464</sup> Scallan <i>et al.</i> (2013), <sup>462</sup> Wu <i>et al.</i> (2016) <sup>463</sup>	

### 6.7. Management strategy for patients with venous leg ulceration

The management of VLU patients requires multidisciplinary care, optimally coordinated between primary and secondary healthcare, to address underlying chronic venous hypertension and optimise other factors contributing to poor wound healing. In the first place, treatment should try to reduce the impact of underlying risk factors such as poor mobility, ankle stiffness, and in particular obesity, by encouraging exercise and weight loss (see subsections 3.1 and 8.2.1, respectively). The main management strategies discussed in this chapter are summarised in two flowcharts (Figs. 12 and 13). Where possible, the pathophysiological cause of the venous hypertension should be treated. Where this is not feasible, effective compression and elevation should be optimised to counter the venous hypertension. Assessment and treatment should

be customised for each patient taking into account their preference. However, the key principles can be summarised as:

- Appropriate model of care (experienced multidisciplinary team, with good links between primary care and specialist services)
- Early assessment and wound bed preparation
- Effective compression therapy (to promote ulcer healing and reduce recurrence risk)
- Prompt intervention for superficial venous reflux (within two weeks using endovenous modalities)
- Consideration of deep venous intervention in appropriate cases
- Pain management
- Consideration of adjuvant pharmacotherapy.

A major challenge for VLU care is to make sure that the model of care is appropriate to ensure prompt and adequate management across primary and secondary care settings. Traditionally, leg ulcer care has been the domain of undersupported community nursing teams, without ready access to venous diagnostics, endovenous procedures, or other advanced wound care therapies. An important component should be VLU prevention strategies, primarily by ensuring that those patients with recently healed VLUs (and therefore at high risk of recurrence) are well educated in VLU prevention strategies (e.g., about the importance of compliance with ECS) and have appropriate treatment of CVD.

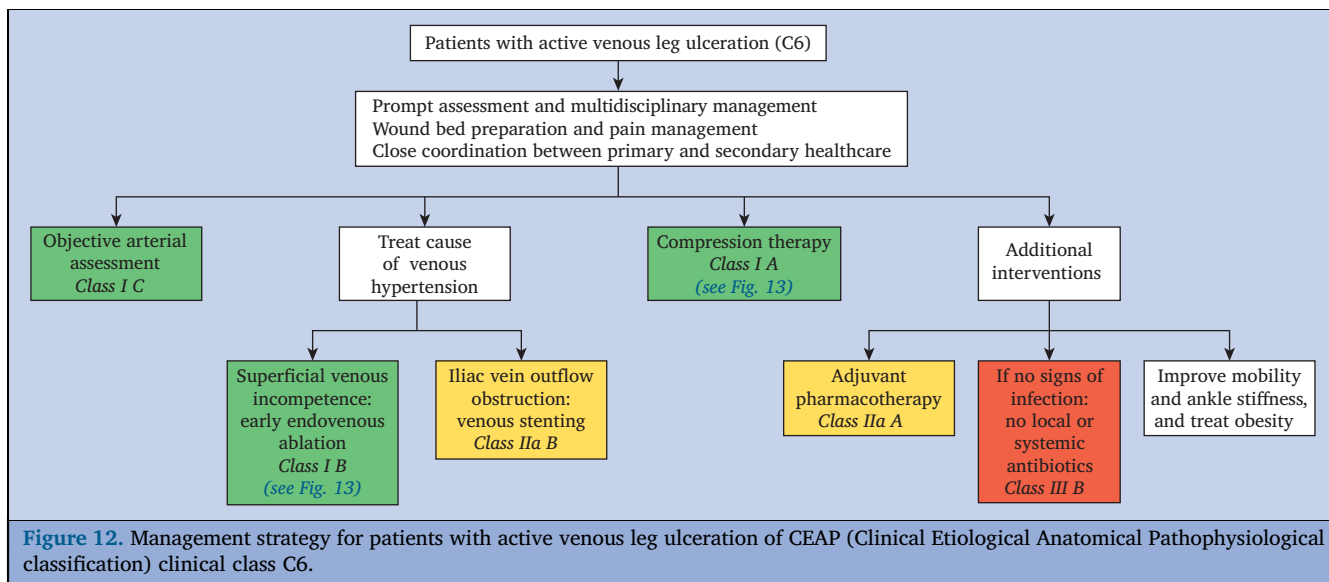
Healthcare professionals involved in VLU care also have an important role in educating patients, community nurses, and primary and secondary care healthcare professionals to ensure that patient care is aligned with best practice.

## 7. MANAGEMENT OF PELVIC VENOUS DISORDERS CAUSING VARICOSE VEINS

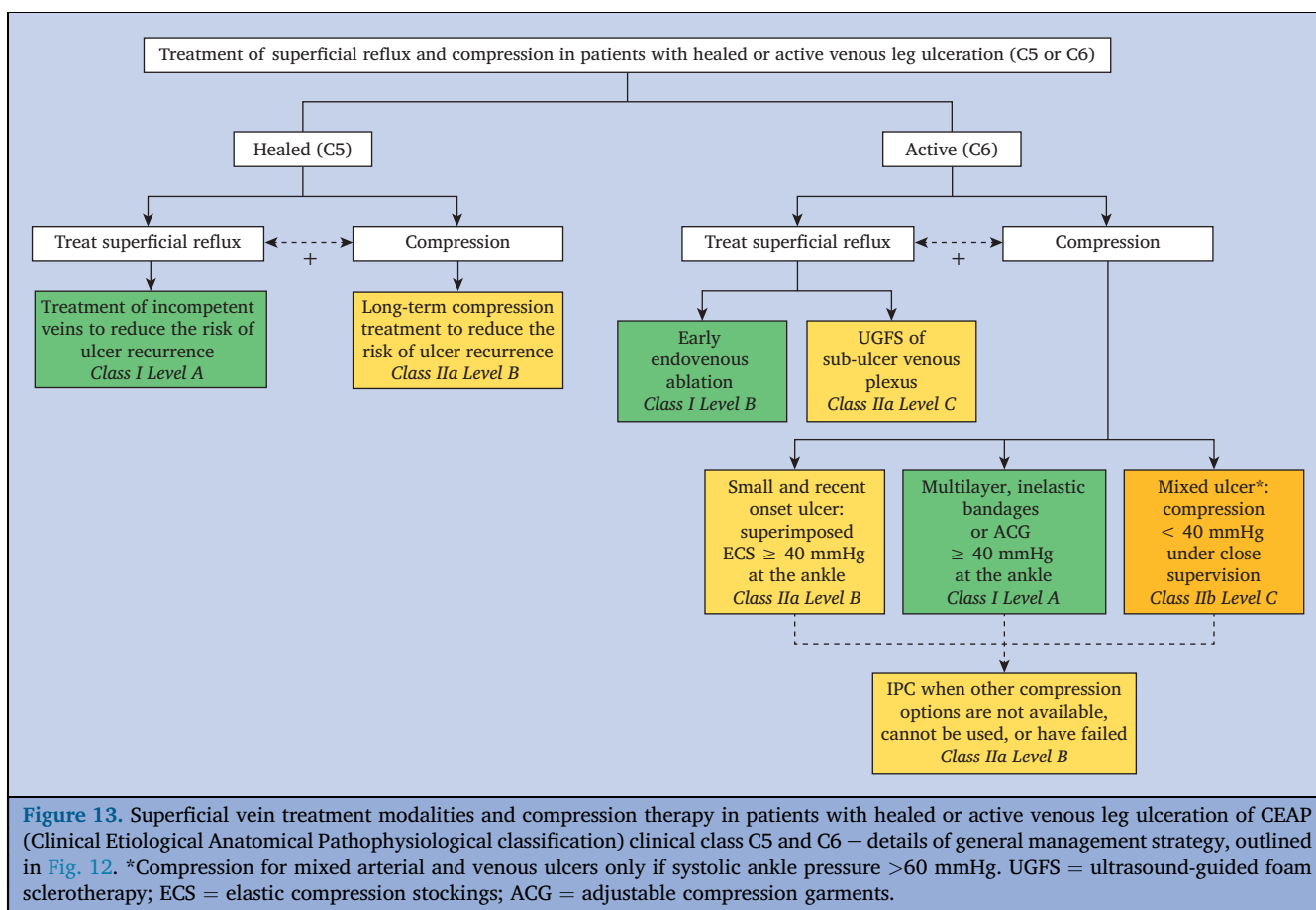
### 7.1. General principles and classification

This chapter mainly discusses the management of patients with VVs and gonadal (ovarian or testicular) vein/IVV reflux, being part of the larger group of patients with PeVD. Historically the nomenclature for PeVD has been unclear. Terms such as “May-Thurner”, “pelvic congestion”, and “nutcracker” syndromes, often failed to recognise the correlation between pelvic symptoms and their underlying pathophysiology. Recently, the American Vein and Lymphatic Society developed a new classification instrument for PeVD.<sup>465</sup> This instrument, has been called the “SVP classification” for PeVD and includes three main domains: Symptoms (S), Varices (V), and Pathophysiology (P), occurring in four anatomical zones of the abdomen and pelvis (Fig. 14). For patients with VVs and related symptoms of pelvic origin, this new SVP classification will be used in future research, in conjunction with CEAP.

**7.1.1. Primary sources of incompetence.** PVI can originate from the left or right gonadal vein (ovarian or testicular



**Figure 12.** Management strategy for patients with active venous leg ulceration of CEAP (Clinical Etiological Anatomical Pathophysiological classification) clinical class C6.

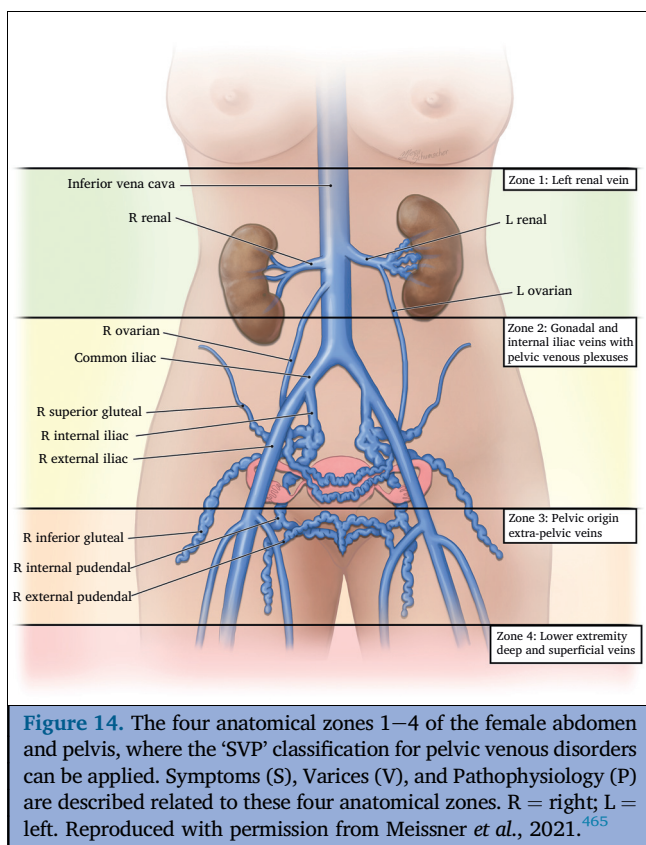


**Figure 13.** Superficial vein treatment modalities and compression therapy in patients with healed or active venous leg ulceration of CEAP (Clinical Etiological Anatomical Pathophysiological classification) clinical class C5 and C6 – details of general management strategy, outlined in Fig. 12. \*Compression for mixed arterial and venous ulcers only if systolic ankle pressure >60 mmHg. UGFS = ultrasound-guided foam sclerotherapy; ECS = elastic compression stockings; ACG = adjustable compression garments.

vein), from the left or right IIV, or from a combination of these veins. Incompetent pelvic veins can be connected with perineal or vulvar veins, with veins of the proximal thigh, or with the sciatic vein, causing lower limb VVs.

**7.1.2. Associated pathologies.** PVI can be secondary to compression of the left CIV by the right common iliac artery

(previously known as “May-Thurner syndrome”), which can cause flow reversal (reflux) in the left IIV, resultant pelvic venous hypertension, and subsequently VVs of the lower limb, with or without pelvic symptoms. Extrinsic compression may also be caused by endometriosis, or a tumour mass. Similar pressure and flow patterns may be seen frequently in cases of post-thrombotic iliac obstruction.



Another rare venous compression entity, namely left renal vein (LRV) compression may also occur (previously known as “nutcracker syndrome”), in which the LRV is compressed between the aorta and the superior mesenteric artery, resulting in increased venous pressure, which may be relieved through perirenal collaterals and/or the left gonadal vein, with reflux into the pelvis and beyond.<sup>466</sup>

## 7.2. Clinical presentation and investigations

**7.2.1. Clinical presentation.** PeVD caused by PVI with or without associated pathologies may clinically manifest through pelvic symptoms, especially chronic pelvic pain (CPP), dyspareunia or prolonged post-coital ache, lower extremity VVs and/or vulvar VVs, lower extremity pain and/or swelling, and left flank pain and/or haematuria.<sup>467</sup>

In women, according to a systematic review by the World Health Organization, the prevalence of CPP, characterised by non-cyclic pain lasting for at least six months, ranged from 4% to 43%, based on 18 studies including 299 740 women.<sup>468</sup> Pelvic venous disorders accounted for 16% – 31% of these cases. The other common causes of CPP include a wide range of gynaecological disorders, especially endometriosis, pelvic inflammatory disease, adhesions, adenomyosis, and also irritable bowel syndrome, interstitial cystitis, musculoskeletal and neurological problems, often with overlapping symptoms in individual patients.<sup>465,469</sup> All these alternative pathologies should be ruled out before correlating CPP with PeVD.

Compression of the CIV and the LRV causing  $\geq 50\%$  area reduction, may be present in 25% – 33% and 51% – 72% of

the general population, respectively. Although most patients are asymptomatic, some may develop CPP, leg oedema, venous claudication, VLU (in cases of CIV compression) or left flank pain and/or haematuria (in cases of LRV compression).<sup>465</sup>

Pelvic venous hypertension can have different pelvic floor escape points (perineal, inguinal, obturator, clitoral, inferior gluteal and superior gluteal) and cause either atypical lower extremity and vulvar VVs or more typical saphenous truncal incompetence (GSV, AASV, SSV) and related VVs. In a large study of patients with symptoms and signs of CVD in 835 limbs, the frequency of non-saphenous reflux according to DUS was 10% and in one third of the latter group this was a result of PVI, which results in an estimated frequency of 3.4%.<sup>470</sup> This may be higher during pregnancy and in patients with persistent or recurrent VVs after previous treatment. Among patients presenting with VVs resulting from PVI, CPP has been reported in  $< 10\%$ .<sup>467</sup>

Vulvar VVs can also be the result of reflux arising from the SFJ through an incompetent superficial or deep external pudendal vein, especially in pregnant women.<sup>471</sup>

In men, VVs of the lower extremity or the scrotum can also be associated with PVI. They are mainly caused by IIV incompetence through obturator or internal pudendal tributaries, or to testicular vein reflux through the inguinal canal. However, they can also be related to SFJ incompetence and external pudendal vein reflux.<sup>339</sup>

**7.2.2. Investigations.** To investigate VVs potentially resulting from PVI, a usual full leg DUS of lower extremity veins in the upright position is necessary as well as transperineal DUS for evaluation of pelvic escape points.<sup>50,470</sup> Visualisation of the SFJ is obviously important, as its incompetence can be the reason for vulvar VVs. On the other hand, in patients with vulvar VVs or recurrent VVs after previous treatment, the presence of a competent SFJ may suggest underlying PVI.

Whenever PeVD are suspected, DUS of pelvic veins (abdominal and/or transvaginal) should be the first line investigation.

**7.2.2.1. Transvaginal ultrasound.** Transvaginal ultrasound (TVUS) is a non-invasive diagnostic method for PeVD. The vaginal approach reduces the distance between the probe and the pelvic structures, enabling the use of higher frequencies and providing better resolution and image quality than with transabdominal DUS.<sup>472</sup> If TVUS is performed in an upright position, it is useful in demonstrating pelvic varicoceles and in the differential diagnosis of CPP. It allows haemodynamic assessment of pelvic vein reflux during a Valsalva manoeuvre. At TVUS, the presence of a vein  $> 5$  mm in diameter crossing the uterus and the presence of pelvic varicoceles have a high sensitivity and specificity for diagnosing PeVD.<sup>472</sup> Together with abdominal DUS, TVUS is the first step in the diagnosis of PeVD, useful for determining which patients with PeVD may potentially benefit from additional venography and possible treatment.<sup>472–474</sup>



**7.2.2.2. Abdominal duplex ultrasound.** On abdominal DUS, presence of a large ovarian vein > 5 mm diameter and reversed flow appear to be the most indicative of PeVD.<sup>472</sup> Abdominal DUS also allows direct visualisation and assessment of the renal and iliac veins. The presence of spontaneous reflux with continuous flow in the left gonadal vein or reversed flow in the left IIV suggests that the aetiology of PVI is secondary to intravenous (post-thrombotic) or extravenous (compression) factors.<sup>467,474</sup> Intermittent reflux in the gonadal vein elicited by distal manual compression in the ipsilateral iliac fossa or by a Valsalva manoeuvre done in a controlled fashion signifies isolated gonadal vein incompetence.<sup>25</sup>

**7.2.2.3. Selective venography and cross sectional imaging.** Selective gonadal and internal iliac venography in the reversed Trendelenburg position, or, alternatively, with a Valsalva manoeuvre, is the gold standard for diagnosing PVI and is essential before embolisation treatment. It allows for direct visualisation of retrograde flow, pelvic venous congestion, filling of vulvar and thigh VVs, and, at the same time, provides access for immediate endovenous intervention.<sup>474</sup>

Both CT and MR imaging can be used for the evaluation of the abdominal and pelvic veins (see subsection 2.4). Moreover, functional MR imaging may provide information on the direction and magnitude of flow. Finally, IVUS may support the diagnosis and treatment of large vein obstruction (see subsection 2.5.2).<sup>467</sup>

Recommendation 83			New
For female patients with pelvic pain and a clinical suspicion of pelvic venous disorders, exclusion of other causes of pain is recommended.			
Class	Level	References	ToE
I	C	Park et al. (2004) <sup>473</sup>	

Recommendation 84			New
For patients presenting with symptomatic varicose veins where there may be a pelvic origin, specific duplex ultrasound assessment of pelvic escape points is recommended.			
Class	Level	References	ToE
I	C	Labropoulos et al. (2001) <sup>470</sup>	

Recommendation 85			New
For female patients with suspected pelvic venous disorders, abdominal and/or transvaginal ultrasound should be considered to confirm the presence of venous pathology.			
Class	Level	References	ToE
Iia	B	Park et al. (2004), <sup>473</sup> Steenbeek et al. (2018) <sup>472</sup>	

**7.3. Treatment**

The therapeutic approach to VVs of the lower extremity and perineum of pelvic origin may vary depending on the occurrence of pelvic symptoms of PVI. The effectiveness of embolisation has been proven in women with CPP related to PVI.<sup>475,476</sup> However, most patients with PVI are asymptomatic, or have minor pelvic symptoms, and do not require any pelvic vein treatment at all.<sup>467,474</sup>

**7.3.1. Varicose veins of pelvic origin without pelvic symptoms.**

Sclerotherapy, in particular UGFS, has been used extensively in VV treatment to eliminate tributary VVs and incompetent PVs.<sup>143</sup> As pelvic escape points play the same role as PVs, UGFS is an adequate method for treating upper thigh and vulvar VVs of pelvic origin, in patients without pelvic symptoms. Moreover, by accessing pelvic escape points, sclerosant foam may also reach the peri-uterine venous plexus. The effectiveness of limited direct treatment of lower extremity and vulvar VVs using UGFS has been reported in several studies.<sup>467,471</sup> Pelvic escape points may also be eliminated by surgical ligation, which can be an alternative to sclerotherapy. In one study on 273 pelvic escape points, recurrent reflux was detected in only 2.2% after ligation.<sup>477</sup> Phlebectomy of VVs resulting from PVI may also be performed with good clinical results.<sup>471</sup>

The need for pelvic vein treatment in patients with VVs resulting from PeVD without pelvic symptoms has not been established reliably. None of the available studies has compared the outcome of treatment limited to VVs of the lower extremity and pelvic escape points with pelvic vein treatment alone in these patients. Published studies have failed to demonstrate substantial improvement in lower extremity VVs after pelvic embolisation or stenting.<sup>478–480</sup> A prospective study in 102 patients with PVI and VVs reported mild or moderate improvement of VVs in only 51% of patients after ovarian or IIV embolisation.<sup>479</sup> Another prospective study showed improvement of lower extremity VVs in only 14% of 43 patients after ovarian vein embolisation. In that study, good results were obtained only for vulvar VVs, which disappeared in 88% of patients.<sup>480</sup>

In a small series of 24 patients with recurrent VVs secondary to PVI, coil and glue embolisation was performed prior to repeat surgery. At four year follow up the VV recurrence rate was 4.2%.<sup>481</sup> The currently available literature does not support embolisation to prevent VV recurrence.

In conclusion, patients with a good clinical response to minimally invasive procedures such as foam sclerotherapy, phlebectomy, or pelvic escape points ligation, do not require pelvic vein embolisation. If VVs recur early, or, if lower extremity symptoms do not resolve, additional pelvic vein treatment may be considered subsequently. Although in general the latter treatment is safe, it is not without potentially serious complications (e.g., coil migration into

the lungs) and therefore should be used for well established indications.<sup>482</sup>

Recommendation 86 <span style="float: right;">New</span>			
For patients with varicose veins of pelvic origin without pelvic symptoms requiring treatment, local procedures for varicose veins and related pelvic escape points should be considered, as initial therapeutic approach.			
Class	Level	References	ToE
IIa	C	Creton <i>et al.</i> (2007), <sup>478</sup> Castenmiller <i>et al.</i> (2013), <sup>480</sup> Hartung <i>et al.</i> (2015), <sup>479</sup> Gavrilov <i>et al.</i> (2017), <sup>471</sup> Delfrate <i>et al.</i> (2019) <sup>477</sup>	

Recommendation 87 <span style="float: right;">New</span>			
For patients with varicose veins of pelvic origin without pelvic symptoms, pelvic vein embolisation as initial treatment should not be performed.			
Class	Level	References	ToE
III	C	Creton <i>et al.</i> (2007), <sup>478</sup> Castenmiller <i>et al.</i> (2013), <sup>480</sup> Hartung <i>et al.</i> (2015) <sup>479</sup>	

### 7.3.2. Varicose veins of pelvic origin with pelvic symptoms.

Percutaneous, endovenous gonadal vein (and IIV) embolisation is the current standard procedure for CPP therapy in these patients because of its effectiveness and minimal complication profile. Technical effectiveness is estimated at 96% – 100% with a recurrence rate up to 32%, while embolisation related complications are rare and non-fatal.<sup>467,475,476,482</sup>

Through a femoral, jugular, or basilic vein access, the gonadal veins are catheterised followed by venography, preferably in a reversed Trendelenburg (head up) position. A variety of embolic materials, including coils, with or without additional foam sclerotherapy, and cyanoacrylate glue have been reported in the literature. Principally, they are introduced into the most distal segment of the incompetent vein first and extended as far proximally as necessary. To date, there is no hard evidence suggesting superiority of one technique over another.<sup>474</sup>

After gonadal venography and successful embolisation, the IIVs should be evaluated to document their contribution to pelvic VVs. If reflux is identified, VVs can be individually selected and coiled. Additional injection of sclerosant foam into pelvic VVs may be useful.

To date, a validated instrument to study the effects of treatment in patients with PeVD does not exist. Nevertheless, most studies focusing on CPP report significant reduction in pain scores following embolisation.<sup>475,476,478,479</sup> However, high quality RCTs on embolisation of pelvic veins to treat CPP and/or (recurrent) VVs of the lower limb are missing.

Finally, in cases where CIV obstruction is identified as the most likely underlying cause of PeVD, stenting of the relevant lesion should be considered (see [subsection 5.3](#)). For

LRV compression, the indications for treatment are more controversial and a multidisciplinary approach is needed. In general, pelvic vein embolisation should be avoided for LRV compression cases.<sup>474</sup> Other invasive treatment options may be considered in exceptional cases. While open and laparoscopic surgery are used, endovascular LRV stenting has been proposed increasingly.<sup>466</sup> In contrast to stent placement for iliac vein compression, stenting of the LRV has been associated with a higher risk of more serious complications, of which migration of the stent to the heart or pulmonary arteries is the most feared.

In conclusion, the possibility of venous outflow obstruction needs to be critically considered in patients with CPP, before pelvic vein embolisation is performed. An inappropriate treatment strategy may have serious consequences.

Recommendation 88 <span style="float: right;">New</span>			
For patients with varicose veins of pelvic origin with pelvic symptoms requiring treatment, pelvic vein embolisation should be considered to reduce symptoms.			
Class	Level	References	ToE
IIa	B	Hartung <i>et al.</i> (2015), <sup>479</sup> Champaneria <i>et al.</i> (2016), <sup>476</sup> Brown <i>et al.</i> (2018) <sup>475</sup>	

### 7.3.3. Other treatment options.

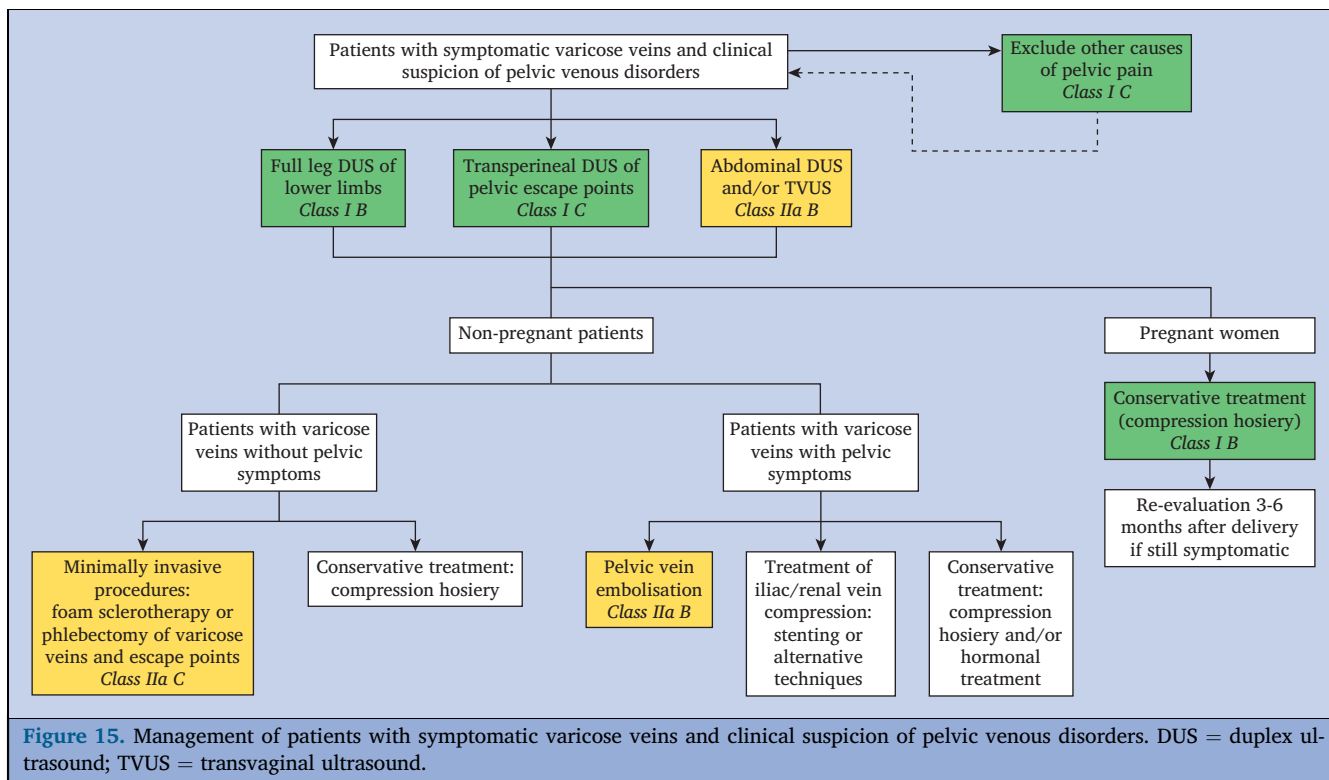
Conservative treatment options for VVs of pelvic origin include compression and hormonal therapy. Especially during pregnancy, when invasive therapy should not be performed, compression hosiery adapted for pregnant women is advised.

In several RCTs, improvement in CPP with methoxyprogesterone, goserelin, or progestin implant of etonogestrel has been reported.<sup>467</sup> However, it is unclear if these effects are directly related to treatment of the underlying PeVD or other pathways. Also, undesirable side effects of this hormonal therapy may occur.

### 7.4. Management strategy for pelvic venous disorders causing varicose veins

In patients with symptomatic VVs and a clinical suspicion of PeVD ([Fig. 15](#)), it is important to collaborate closely with a gynaecologist and/or other specialists in pelvic problems, to exclude other causes of pelvic pain. In addition to a routine full leg DUS, transperineal DUS of pelvic escape points is indicated. In addition, transvaginal and transabdominal DUS may be useful for the diagnosis of PeVD. Whenever interventional treatment of underlying supra-inguinal obstruction is considered, this can be further complemented by cross sectional imaging, venography and/or IVUS ([Fig. 5](#)).<sup>474</sup>

In non-pregnant patients with VVs of pelvic origin, the optimum treatment strategy depends on the presence or absence of significant pelvic symptoms. If significant pelvic symptoms (i.e., with a negative impact on QoL) are present, pelvic vein embolisation should be considered. In more complex cases, with iliac or renal vein compression, additional invasive treatment may be an option. Conservative



**Figure 15.** Management of patients with symptomatic varicose veins and clinical suspicion of pelvic venous disorders. DUS = duplex ultrasound; TVUS = transvaginal ultrasound.

treatment (hormonal therapy and compression hosiery) may be an alternative option in such patients.<sup>467</sup> In patients with VVs resulting from PVI without accompanying pelvic symptoms, a local approach (foam sclerotherapy, phlebectomy, or surgical ligation of pelvic escape points) is a useful first option, avoiding unnecessary and more expensive coil embolisation. Only if local procedures fail, if VVs recur quickly, or if the patient develops pelvic and lower extremity symptoms, may coil embolisation be offered.

In pregnant women, the most common treatment for VVs of pelvic origin and/or vulvar VVs is maternity compression hosiery (see Recommendation 93, subsection 8.2.2), including tights and shorts for compression of vulvar VVs.

**8. SPECIAL CONSIDERATIONS**

**8.1. Management of acute complications**

**8.1.1. Superficial vein thrombosis.** Most cases of SVT are spontaneous or after a minor local trauma, usually in patients with VVs. SVT is not always a benign condition, as thrombus may ascend and extend into the deep venous system. Patients usually present with a painful red lump or cord, with localised oedema and warmth over the affected area. DUS is mandatory to evaluate thrombus extent and to exclude concomitant DVT. If the SVT is involving only a short segment of a varicose tributary (< 5 cm), evacuation of the thrombus by puncture or through a small incision, may alleviate local pain quickly. Detailed guidelines for

treatment of SVT are provided in the ESVS Clinical Practice Guidelines on Venous Thrombosis.<sup>2</sup>

**8.1.2. Haemorrhage.** Venous hypertension, resulting from untreated VVs, iliac outflow obstruction, or right cardiac failure, may apply excess pressure to reticular veins or telangiectasias. The overlying skin then may become thinner and blebs may form. Provided the overlying skin remains intact, it may cause only bruising, but, in case of injury, even after minor trauma, it may cause excessive bleeding which can exceptionally be fatal.<sup>34</sup> Such an event often occurs during a warm shower because of venous dilation, or it may occur while sleeping, often in elderly patients living alone. Patients with pulsatile VVs may be particularly at risk of acute haemorrhage (see subsection 8.2.4). Bleeding may also occur in a VLU.

Bleeding usually subsides with immediate elevation and external pressure. Treatment of small diameter VVs and blebs can be performed effectively with foam sclerotherapy, to avoid further bleeding.<sup>483</sup> Investigation for and treatment of underlying venous incompetence, if possible, will further reduce the risk of recurrent haemorrhage.

<b>Recommendation 89</b>		<b>New</b>
<b>For patients who have had acute spontaneous bleeding from superficial veins, referral for urgent assessment and treatment is recommended.</b>		
Class	Level	References
I	C	Consensus

Recommendation 90 <span style="float: right;">New</span>			
For patients with chronic venous disease who have suffered from an episode of acute bleeding of superficial veins or telangiectasias, local foam sclerotherapy should be considered to prevent recurrent bleeding.			
Class	Level	References	ToE
Ila	C	Hamahata <i>et al.</i> (2011), <sup>483</sup> Serra <i>et al.</i> (2018) <sup>34</sup>	

### 8.2. Special patient characteristics

**8.2.1. Obesity.** The relationship between CVD and obesity is well recognised in numerous studies. The modern epidemic of obesity is reflected in the increasing proportion of those who are obese in community and population studies on CVD.<sup>484</sup> Obese patients are often over-represented in venous clinics. Morbidly obese patients often have lower limb skin changes and ulcers consistent with CVD.<sup>485,486</sup>

The impact of obesity on venous haemodynamics, with increased reflux and greater venous pressures contributing to the greater CVD severity are all well described.<sup>487</sup> The primary mechanism for this is the raised intra-abdominal pressure.<sup>488</sup> Muscle pump deficiency has also been implicated in the obese. Despite the muscle pump of an obese patient having increased venous ejection volumes, it is used less frequently with fewer daily steps.<sup>487</sup>

Therefore, obesity is increasingly important, as it contributes to the severity of CVD and influences treatment strategies and outcomes. In a retrospective analysis including 65 329 patients undergoing EVTA, phlebectomies, and UGFS or combined treatment, inferior outcomes (r-VCSS, CIVIQ-20) were observed in patients with a BMI of  $\geq 35 \text{ kg/m}^2$  compared with those having a lower BMI. However, improvements in r-VCSS and CIVIQ-20 were found in all BMI categories six months after treatment.<sup>489</sup> If venous intervention is indicated, EVTA or non-thermal ablation of incompetent saphenous trunks is preferred over open surgery,<sup>127</sup> as complications such as wound infection after endovenous ablation are rare. However, cannulation and ablation may be technically demanding as veins are deeper under the skin compared with non-obese patients.

Weight loss is an effective adjunct to treatment. For those with morbid obesity, bariatric surgery improves skin problems from 75% to 80% down to 36.4% after weight loss.<sup>486</sup> Another study compared the effect of bariatric surgery in 72 patients with morbid obesity and severe manifestations of CVI with 51 similar patients who did not have surgery. In addition to a significant drop in BMI in the surgery group, these patients showed an increased rate of VLU healing, a decrease in venous claudication, and an improvement in venous QoL.<sup>490</sup> Weight loss, by lifestyle changes in those with less severe obesity, is

recommended to achieve similar benefits (see subsection 3.1).

Recommendation 91 <span style="float: right;">New</span>			
For patients with chronic venous disease, who are obese, weight loss should be considered for improving venous outcomes.			
Class	Level	References	ToE
Ila	C	Parkyn <i>et al.</i> (2014), <sup>486</sup> Shaalan <i>et al.</i> (2021) <sup>490</sup>	

Recommendation 92 <span style="float: right;">New</span>			
For obese patients with saphenous trunk incompetence requiring treatment, endovenous ablation should be considered.			
Class	Level	References	ToE
Ila	C	Deol <i>et al.</i> (2020) <sup>489</sup>	

**8.2.2. Pregnancy.** Pregnancy is a contributory factor to CVD, increasing the frequency of telangiectasias, reticular veins, VVs, and recurrent SFJ reflux after VV surgery.<sup>491</sup> Leg oedema can affect up to 80% of pregnant women, mainly during the third trimester. Some women develop vulvar VVs, which tend to be exacerbated with each subsequent pregnancy (see subsection 7.2).

In pregnant women treatment of leg oedema, VVs, and vulvar VVs is mostly conservative with compression hosiery. ECS not only have a beneficial effect on GSV and SSV diameter and reflux, but also improve symptoms and signs of CVD.<sup>492–494</sup> According to the NICE guidelines on management of VVs, interventional treatment should not be offered during pregnancy.<sup>495</sup>

In the majority of women, telangiectasias, reticular veins, and VVs subside at least partially within the first post-partum months. Any further treatment should therefore be postponed until three to six months after delivery.

Recommendation 93 <span style="float: right;">New</span>			
For pregnant women presenting with symptoms and/or signs of chronic venous disease, the use of elastic compression hosiery is recommended.			
Class	Level	References	ToE
I	B	Thaler <i>et al.</i> (2001), <sup>492</sup> Adamczyk <i>et al.</i> (2013), <sup>494</sup> Saliba <i>et al.</i> (2020)	

**8.2.3. Patients on anticoagulants.** Patients receiving long term anticoagulants may be at increased risk of thromboembolic events if their medication is temporarily interrupted. Bridging may be considered, but this increases costs and adds complexity to the planning of venous interventions. On the other hand, continuing anticoagulants



might increase the risk of bleeding or decrease the efficacy of the ablation.

Concerning treatment of superficial venous incompetence, the largest study on this topic included 100 EVTA procedures in 65 chronically anticoagulated patients and 127 procedures in 89 controls.<sup>496</sup> After 18 months, successful saphenous ablation was found in 92% of anticoagulated patients and in 95% of controls ( $p = .96$ ). The frequency of DVT in the ipsilateral leg was low (1% in anticoagulated patients *versus* 1.6% in controls). Other smaller studies found similar results and a Delphi consensus also advised against bridging of vitamin K antagonists for endovenous ablation.<sup>127</sup> Anticoagulation treatment is not a contraindication to sclerotherapy.<sup>143</sup> However, patients should be advised that treatment success may be reduced and/or additional treatment sessions may be required.

Concerning treatment of deep vein pathology, anti-thrombotic regimens used in different studies are heterogeneous.<sup>355</sup> Neither type of anticoagulation nor duration have been studied. In general, the advice is that patients on anticoagulants should not pause but switch to LMWH pre-operatively and continue this treatment shortly after the intervention (see subsection 5.3.4).

Recommendation 94			New
For patients with chronic venous disease, who are on anticoagulants and scheduled to undergo endovenous thermal ablation, interruption of anticoagulation is not recommended.			
Class	Level	References	ToE
III	C	Westin <i>et al.</i> (2020) <sup>496</sup>	

**8.2.4. Elderly patients and patients with comorbidities.**

Epidemiological data from a large study on 38 750 US patients suggest that up to 30% of CVD presentations are in patients aged > 65 years.<sup>497</sup> Commonly reported comorbidities in this cohort include diabetes (25%), hypertension (64%), chronic obstructive pulmonary disease (5%), history of cancer (12%), and stroke (3%). Coronary artery disease (0.12%) and peripheral artery disease (0.03%) are infrequent. Importantly those aged > 65 years are more likely to require venous intervention than their younger counterparts, given their higher rates of reported venous symptoms, as well as skin changes (12% vs. 6%,  $p < .001$ ) and VLU (5% vs. 2%,  $p < .001$ ).<sup>497</sup>

A multicentre prospective study confirmed comparable rates of efficacy and safety for EVTA in local tumescent anaesthesia in cohorts of patients aged > 75 years, with more comorbidities compared with younger patients.<sup>498</sup> However, age was found to be a statistically significant risk factor for recanalisation in another study in elderly patients with an OR of 1.03 (95% CI 1.01 – 1.04,  $p < .001$ ), which remained statistically significant in multivariable analysis.<sup>165</sup>

Patients with right heart failure or tricuspid valve regurgitation may sometimes present with pulsatile VVs from high pressure reflux. In these patients, standard

endovenous treatment modalities might fail as a result of insufficient inflammation and collapse of the treated vein. Pulsatile VVs are an indication for pre-operative cardiac evaluation, but information on this is scarce.

**8.2.5. Children with chronic venous disease.** In children CVD is rare and may be a result of congenital venous malformation (including atresia of deep veins), primary superficial and/or deep vein valve incompetence, or extensive DVT with secondary DVI and/or obstruction. Incidence of DVT and VTE has been increasing during the last decades because of more frequent use of central venous catheters in critically ill paediatric patients.<sup>2</sup> This has resulted in a rising incidence of paediatric PTS as, according to a meta-analysis, PTS occurs in 26% (0 – 77%) of paediatric DVTs.<sup>499</sup>

Management of children with CVD is mainly conservative, although venous interventions may be considered in highly symptomatic cases. EVLA has been reported feasible and safe in a small group of 35 children, with a median age of 14 years, undergoing EVLA mainly for venous malformations, Klippel-Trenaunay syndrome, and superficial venous reflux with VVs. The treatment was deemed successful in 83% of cases.<sup>500</sup>

**9. GAPS IN EVIDENCE AND FUTURE PERSPECTIVES**

The GWC has identified the following issues, where the available evidence is currently insufficient, and more research is needed to guide clinical practice.

**9.1. Understanding the natural history of chronic venous disease**

The natural history of CVD for the whole population and for specific subgroups remains poorly understood. There is no strong evidence to guide which patients/limbs with C2 disease will progress to C4 disease, or which limbs with C4 disease are at the highest risk of progressing to ulceration.

The term “venous oedema” (C3 of CEAP), as well as the relationship between varicose veins and oedema need to be better defined.

**9.2. Diagnostic work up in patients with chronic venous disease**

When performing DUS, the role of evaluating additional haemodynamic parameters (such as reflux volume, recirculation index, postural diameter change, venous-arterial flow index), instead of “reflux” only, remains unclear and needs more research.

Which patients require additional abdominal DUS during the initial work up for suspected or obvious CVD should be further investigated.

The clinical potential of air plethysmography, in particular the use of the venous drainage index, in patients with chronic outflow obstruction needs to be explored.

Validated criteria for quantification of post-thrombotic obstruction on DUS, MRV, and CTV are lacking.

The role of dynamic MRV in deep venous obstruction and incompetence needs further investigation.

Assessment of inflow remains a major challenge for patients with venous outflow obstruction being considered for stenting.

### 9.3. Conservative treatment of chronic venous disease

The effect of lifestyle changes and weight loss has not been studied properly in patients with CVD.

The role of exercise therapy and specific exercise programmes is poorly understood. Future research into the effect of physical exercise should consider types of exercise protocols (intensity, frequency, and time), sample size, blinding, and homogeneity according to the severity of CVD.

So far, the focus has been on the role of compression to prevent PTS after acute DVT, not on treatment of patients with established PTS. More evidence is needed to validate the role of ECS and also the potential additional benefit of IPC, in particular for patients with moderate or severe PTS.

### 9.4. Treatment of superficial venous incompetence

Further guidance is needed to understand the optimal strategic approaches to different clinical presentations and anatomical reflux patterns. There is little evidence to support which modalities are best for different truncal veins, varying clinical class (according to CEAP) or differing anatomical factors, such as saphenous trunk diameter or depth.

The true rate of tributary regression following isolated truncal vein ablation remains unclear.

RCTs looking at the long term outcome of endovenous ablation of an incompetent SSV and AASV are still missing.

When and how to treat incompetent PVs in which patients needs to be further unravelled.

The requirement for and duration of compression following each modality of endovenous truncal ablation should be clarified, as the available evidence is very contradictory.

There is minimal reliable evidence on patient selection for peri-procedural thromboprophylaxis and the use of different products (LMWH, DOACs), dose and duration of prophylaxis.

### 9.5. Treatment of deep venous obstruction

In general, clear and evidence based criteria are needed to select patients for deep venous interventions. Venous claudication is not included in the available scoring systems.

Better disease specific QoL scores are needed, to evaluate patients before and after deep venous intervention.

Diagnosis of deep venous obstruction is mostly based on morphological findings and limited data on haemodynamic evaluation of obstruction are available. In particular this may lead to overtreatment of NIVLs.

Post-procedural anticoagulation and antiplatelet treatment after iliac vein stenting remains a matter of debate.

### 9.6. Management of venous leg ulcer

The role of iliac venous imaging in VLU is unknown.

There is a lack of evidence about how radical elimination of superficial venous reflux should be for a VLU and whether sub-ulcer venous plexus ablation is necessary.

The role of superficial venous ablation procedures in ulcer healing for patients with chronic ulcers of greater than six months duration is unknown.

In the chronic VLU management strategy, the timing and role of diagnosing and treating venous outflow obstruction as an adjunct to superficial venous ablation and compression is unclear.

In patients with VLU, more RCTs are needed to evaluate the different strategies on ulcer healing, recurrence rate, and the effect on the number of re-operations needed at long term follow up.

### 9.7. Treatment of varicose veins related to pelvic vein incompetence

There is a lack of generally accepted well defined clinical criteria for the diagnosis of PeVD and hence it is unclear what the magnitude of the expected treatment effect may be. A scoring tool for PeVD is currently being developed through different societies but is not available yet.

So far there is no clinical scoring system or well established imaging criteria to select patients who would benefit the most from intervention.

In patients with PVI, well performed RCTs including homogeneous study populations, proving the efficacy of intervention and comparing different treatment modalities are still awaited.

### 9.8. Improving future clinical practice guidelines on the management of chronic venous disease

The methodological quality used for creating clinical practice guidelines should always be as high as possible. Several guideline appraisal tools, such as the Appraisal of Guidelines for Research and Evaluation II (AGREE II) tool,<sup>501</sup> have been developed for use when generating guidelines and to evaluate retrospectively their methodological quality. According to a systematic review assessing the methodological quality of clinical practice guidelines in CVD, published in the past 20 years, the authors concluded there was definitely room for improvement, in particular in outlining stakeholder involvement and evaluating the applicability of the guidelines in clinical practice.<sup>502</sup>

## 10. INFORMATION FOR PATIENTS

This information has been developed by the European Society for Vascular Surgery (ESVS). The ESVS produces guidelines to help medical professionals involved in the care of patients with a wide range of conditions related to circulation and blood flow. In this document, a specially

convened international group of specialists in chronic venous disease and the ESVS guidelines committee have produced a full set of guidelines and recommendations for healthcare professionals.

The following section contains a summary of the information in the full guidelines document, presented in a format suitable for non-experts. Details of the process used to create the guidelines and areas where further research is needed are described at the end of this section. Where there is strong evidence supporting a particular treatment, or strong evidence showing that a treatment is not effective, details are summarised in this section. Full details of the guideline are not included in the present section, but readers are encouraged to read the relevant section of the full guidelines document or consult their healthcare professional for further information.

### **10.1. What is chronic venous disease of the legs?**

Chronic venous disease of the legs is a common condition caused by malfunctioning of the veins, responsible for returning blood from the legs to the heart. It may affect up to 60% of the adult general population. Varicose veins, which are lumpy, superficial, and wiggly veins on the legs, are the most typical form of this disease. However, other features may indicate that the veins of the legs are not working well. People may experience symptoms, such as painful and tired legs. The appearance of the affected leg(s) may also change over time. Superficial veins become increasingly visible and bulging, and the leg(s) may be swollen. With more advanced disease, the skin may become darker in areas and a wound may appear on the lower leg, known as a leg ulcer. All the above may indicate the need for further testing and/or care.

### **10.2. Why does chronic venous disease occur?**

The veins of the lower limbs carry blood, from the feet to the heart. When an individual is standing or walking, this must occur against gravity. Therefore, normal veins have solid vein walls and special, one way valves, which ensure the flow goes from the feet towards the heart. If a vein wall becomes weaker, the vein swells, which means the venous valves cannot function correctly anymore ("leaky valves"). This causes pooling of blood in the lower parts of the legs. The exact cause of these changes in the vein wall and venous valves is not known, but there may be a genetic role.

A less common cause of chronic venous disease is blockage of the deep veins as a result of previous clot formation inside the deep veins, called "deep vein thrombosis". Acute disease caused by thrombosis has been discussed in another ESVS guideline, where information for patients on this topic can be found. If the normal passage is not completely restored, this results in pooling of blood in

the legs in a similar fashion. Again, this may be followed by failure of the venous valves.

### **10.3. Which veins can be affected by chronic venous disease?**

In the legs, there are "superficial veins", lying between the skin and the muscles and "deep veins", lying between or inside the muscles. The superficial veins are most frequently affected in patients with chronic venous disease. The visible varicose veins are usually branches or "tributaries" of the main superficial veins (called the saphenous veins). Less commonly, the deep veins are affected, usually after a previous blood clot. The veins connecting the superficial with the deep veins are called "perforating veins". Commonly, two or three vein types may be affected at the same time.

In addition to the larger veins already mentioned, there are also small veins immediately under the skin, which may become increasingly visible and mainly cause cosmetic concerns. These are called "reticular veins" (or thread veins) and the very small ones "telangiectasias" (or spider veins).

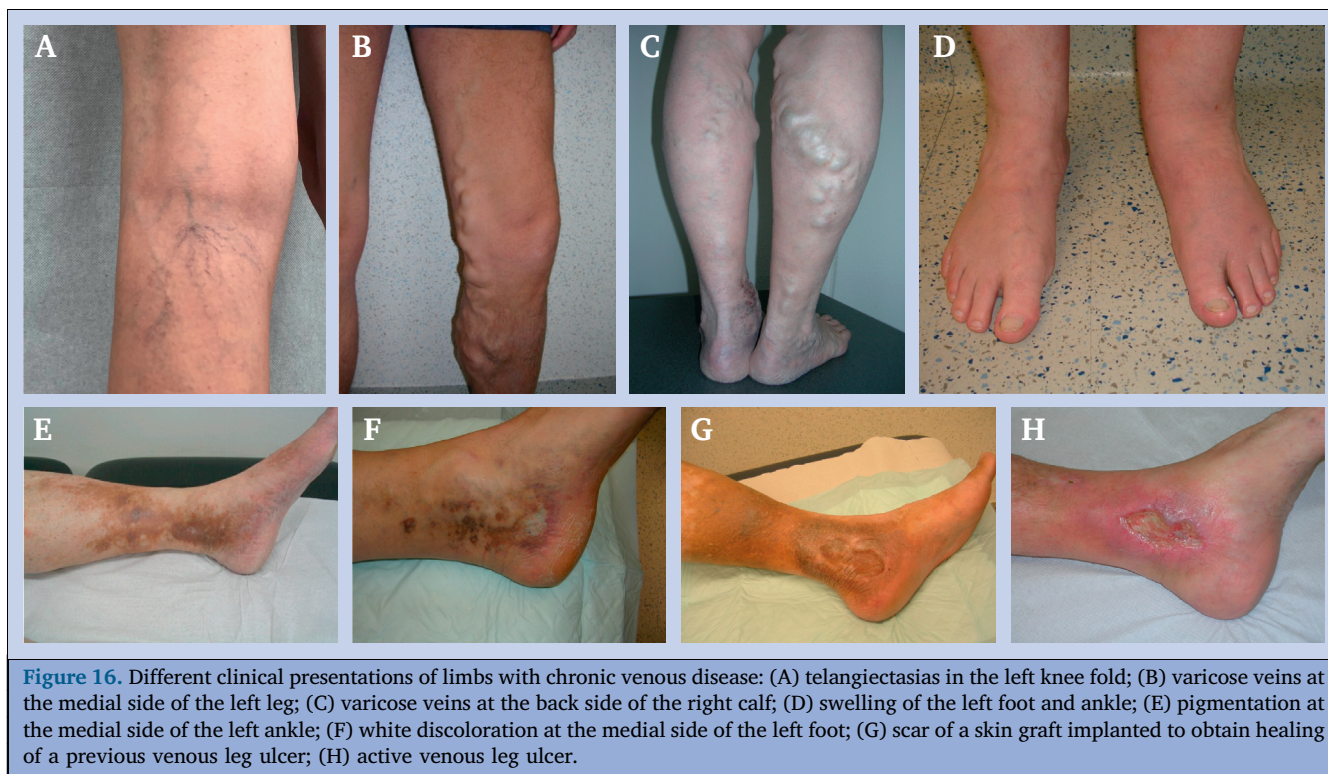### **10.4. What are the symptoms and signs of chronic venous disease?**

What the patient feels subjectively, we call symptoms, whereas what the patient and doctor can see objectively are called signs of a disease. Patients with chronic venous disease may complain of a variety of symptoms and portray many clinical signs. Patients often report pain, which may be throbbing, burning, or feel like a muscle cramp. Such cramps occur typically during the night. Other frequent complaints include heavy and tired legs, which feel swollen, particularly in the evening, and itching of the skin. All these symptoms get worse with prolonged standing. Clinical signs on examining the legs include dilated veins ranging from small veins (Fig. 16A) to varicose veins, which may sometimes be rather impressive (Fig. 16B and C). Also swelling of the lower part of the leg, mainly the foot and ankle is a typical feature (Fig. 16D). In more advanced stages of disease, there may be skin changes ranging from brown pigmentation (Fig. 16E), white discoloration (Fig. 16F) and scars from a previous skin breakdown (Fig. 16G), to existing breakdown of the skin (termed "active venous leg ulcer") (Fig. 16H). In view of the symptoms and signs described above, chronic venous disease has a negative impact on the patient's quality of life.

### **10.5. What are the acute complications of chronic venous disease?**

Acute complications may include formation of blood clots inside the dilated leg superficial veins, called "superficial vein thrombosis". Clots may also form in the deep veins, inducing a "deep vein thrombosis", which may rarely break off and travel to the lungs. Occasionally, a dilated superficial





vein may lead to external bleeding, in particular if the overlying skin is very thin.

#### 10.6. How is chronic venous disease diagnosed?

Initially, chronic venous disease is diagnosed by a medical professional examining the legs and looking for the signs listed above. However, if treatment is considered, there is a need for more detailed information about the abnormal veins that may be leaking, blocked, or both. This is primarily done with an ultrasound scan, with occasional use of other, more specialised methods.

#### 10.7. What are the principles of treatment for chronic venous disease?

Firstly, it is important to know that not every patient requires a procedure to treat chronic venous disease. Reassurance, education, and some simple conservative measures are also used very often. Further, it should be clear that treatment for superficial and deep vein disease is very different. Diseased superficial veins can be eliminated without causing any harm, whereas deep veins cannot be removed or destroyed, as their function is essential for blood flow from the leg to the heart.

#### 10.8. Which conservative measures are available if I suffer from chronic venous disease?

Conservative measures include exercise, weight loss, physiotherapy, leg elevation at rest, medication aiming to improve the function of the veins, and compression treatment of the leg. The latter comes in many types, with elastic

stockings and bandages being most commonly used. Compression garments compress the dilated veins and reduce the pooling of blood in the legs. Additionally, they can prevent leg swelling. The result is improvement of patient symptoms and quality of life. It is important to wear the stockings most of the time during the day, to obtain the best results. Compression stockings may be difficult to put on and take off, but specific aids are available to help.

#### 10.9. How can I be treated for varicose veins and related superficial venous disease?

For many years, surgical “stripping” of the damaged superficial veins was the classical method to treat varicose veins and related problems. However, in the last 20 years, newer alternative methods have been developed to close the vein by using local heat or another method that can interact with the vein wall. These advances have been helped by the widespread availability of ultrasound, which is not only used for diagnosis but also to guide superficial venous treatment.

The most common heat treatments make use of “laser” or “radiofrequency ablation”, where a special fibre is carefully inserted into the vein and, after injection of anaesthetic, the fibre is used to heat and close the inside of the vein. These procedures do not require a big operating room and can easily be done in the outpatient setting. Most patients recover without any problem and can swiftly resume their normal activities.

In recent years, yet more alternative methods to close the saphenous vein have been developed. These techniques do not use heat and hence no anaesthetic needs to be



injected to numb the vein. Instead of heat, mechanical and chemical irritation of the vein wall leads to closure of the vein, or the vein is closed with surgical glue. Other techniques, known for many years, have also been optimised. For instance, injection of a diseased vein with a chemical solution called “sclerotherapy” has been converted into “foam sclerotherapy”, where white foam, made by mixing the sclerosant solution with air, is injected into the vein.

Whereas the availability of all these “minimally invasive” treatment methods for varicose veins may be a real benefit for patients, treatment choice has become very complicated. Therefore, it is important for the treating physician to discuss the pros and cons of different potential treatments with their patient. It should be a shared decision between the patient and the treating physician, to decide which treatment is likely to be the most appropriate for each individual. As varicose veins are never exactly the same between one patient and the other, a “patient tailored” treatment approach is needed.

#### **10.10. How can I be treated for visible small veins, which make my legs look ugly?**

Visible, small veins immediately under the skin can be managed by injection of a chemical agent. After a certain time, the small veins will become less visible or even completely disappear. Alternatively, the smallest veins can be treated by local application of laser energy through the skin, targeting the blood inside these little veins, to eliminate them.

#### **10.11. What is the best treatment if my deep veins do not allow the normal passage of blood from my legs to the heart?**

Blockage or narrowing of the deep veins, particularly those in the lower abdomen, can be treated with a minimally invasive procedure, through a small skin hole. This is only done if the patient suffers from severe complaints and is not able to have a normal life. The procedure is very similar to what is done to unblock heart and leg arteries, known as “balloon angioplasty” and placement of a “stent”. A stent is a metallic mesh tube, implanted in the previously blocked vein to reinstall or maintain a normal passage through the vein. Open surgical bypass procedures using a vein or a tube to detour the blood through an alternative route are rarely used in modern care.

#### **10.12. Are there any useful interventions if I have a venous leg ulcer?**

Yes, fortunately there are several solutions. Reducing leg swelling using compression with elastic bandages or elastic stockings has been used for centuries and this is still applicable now. Also, exercise, to keep the ankle as mobile as possible, may be important, as well as weight loss in cases of obesity. Some drugs may speed up ulcer healing. However, the most important point is to diagnose the

underlying venous problem and consider whether a prompt treatment may be appropriate. Therefore, extensive ultrasound evaluation is mandatory.

If the main problem lies in inadequate functioning of the superficial veins and their valves, then early treatment, by means of ablation as described above (see 10.9), or surgery, is indicated. If the main problem is obstruction of the passage of blood through the deep veins, for instance after a previous thrombosis, then stent placement may be the best option. All these interventions may be used together with compression. The key principle is to identify and treat the underlying venous problem, as this is likely to lead to quicker ulcer healing and a lower risk of developing a new venous leg ulcer.

#### **10.13. What are the main areas that need further research?**

During the development of this guideline document, the committee identified several areas where the current evidence remains weak and further research is needed. Some questions that remain unanswered include:

- Which patients with varicose veins are at risk of developing skin damage and possibly getting a venous leg ulcer later on?
- Which patients with varicose veins need investigations other than just an ultrasound of their legs?
- Are compression stockings really needed after treatment of superficial veins?
- Which patients should be selected for stent placement to restore passage through a blocked deep vein?
- In a patient with a venous leg ulcer, what is the expected benefit of an intervention for leaking superficial veins, if the ulcer has been open for more than six months? Is it still worthwhile?

#### **10.14. How was this information developed and what do I need to know before reading the full document?**

The information in this section is a summary of the guideline document produced by the ESVS Chronic Venous Disease Guidelines Writing Committee. The committee consists of experts from across Europe, who reviewed the available medical evidence. This allowed them to make recommendations that healthcare professionals may follow. The document was reviewed by another independent group of international specialists. They double checked that the recommendations were accurate and up to date with the most recent evidence. Some of these recommendations could change in the future, as research and knowledge increase further.

#### **ACKNOWLEDGEMENTS**

The authors would like to thank the eight patients suffering from chronic venous disease in the United Kingdom

National Health Service and the three lay members of the public without chronic venous disease, who evaluated the lay summaries of this guideline.

The authors would also like to thank Fleur van Midwoud for graphical assistance (Figs. 3 and 4).

#### APPENDIX A. SUPPLEMENTARY DATA

Supplementary data including Tables of Evidence to this article can be found online at <https://doi.org/10.1016/j.ejvs.2021.12.024>.

#### APPENDIX B. AUTHORS' AFFILIATIONS

##### Writing Committee

Marianne G. De Maeseneer (Chair), Department of Dermatology, Erasmus Medical Centre, Rotterdam, The Netherlands; Stavros K. Kakkos (Co-Chair), Department of Vascular Surgery, University of Patras, Patras, Greece; Thomas Aherne, Department of Vascular Surgery, Cork University Hospital and National University of Ireland Galway, Ireland; Niels Baekgaard, Department of Vascular Surgery, Gentofte Hospital and Rigshospitalet, University of Copenhagen, Copenhagen, Denmark; Stephen A. Black, Guy's and St Thomas Hospital and Kings College, London, United Kingdom; Lena Blomgren, Karlskoga Vein Centre, Department of Cardiovascular and Thoracic Surgery, School of Medical Sciences, Örebro University, Örebro, Sweden; Athanasios Giannoukas, Department of Vascular Surgery, University Hospital of Larissa, Faculty of Medicine, School of Health Sciences, University of Thessaly, Larissa, Greece; Manjit Gohel, Cambridge University Hospitals, Cambridge and Imperial College London, London, United Kingdom; Rick de Graaf, Department of diagnostic and interventional Radiology, Clinic of Friedrichshafen, Friedrichshafen, Germany; Claudine Hamel-Desnos, Department of Vascular Medicine, Saint Joseph Hospital Group, Paris, France and Saint Martin Private Hospital, Caen, France; Arkadiusz Jawien, Department of Vascular Surgery and Angiology, Ludwik Rydygier Collegium Medicum, Bydgoszcz and Nicolaus Copernicus University, Torun, Poland; Aleksandra Jaworucka-Kaczorowska, Center of Phlebology and Aesthetic Medicine, Surgery and Gynecology Center, Gorzów, Poland; Christopher R. Lattimer, London North West University Healthcare NHS Trust and Imperial College London, United Kingdom; Giovanni Mosti, Angiology Department, Maria Domenica Barbantini Clinic, Lucca, Italy; Thomas Noppeney, Department of Vascular and Endovascular Surgery, Martha-Maria Hospital, Nuremberg and Department of Vascular and Endovascular Surgery, University Hospital, Regensburg, Germany; Marie Josee van Rijn, Department of Vascular Surgery, Erasmus Medical Centre, Rotterdam, The Netherlands; Gerard Stansby, Freeman Hospital and Newcastle University, Newcastle upon Tyne, United Kingdom.

##### ESVS Guidelines Committee

Philippe Kolh (Chair, Review Coordinator), Department of Biomedical and Preclinical Sciences, University of Liège,

Liège, Belgium; Frederico Bastos Gonçalves, Hospital de Santa Marta, Centro Hospitalar Unversitário de Lisboa Central, and NOVA Medical School, Universidade NOVA de Lisboa, Lisboa, Portugal; Nabil Chakfé, Department of Vascular surgery and Kidney Transplantation, University of Strasbourg, Strasbourg, France; Raphael Coscas, Department of Vascular Surgery, CHU Ambroise Paré, Assistance Publique - Hôpitaux de Paris (AP-HP), and University Versailles-Saint Quentin, University Paris-Saclay, Boulogne-Billancourt, France; Gert J. de Borst, Department of Vascular Surgery, University Medical Center Utrecht, Utrecht, The Netherlands; Nuno V. Dias, Vascular Center, Skåne University Hospital, and Clinical Sciences Malmö, Lund University, Malmö, Sweden; Robert J. Hinchliffe, University of Bristol, Bristol, United Kingdom; Igor B. Koncar, Clinic for Vascular and Endovascular Surgery, Serbian Clinical Centre, Medical faculty, University of Belgrade, Belgrade, Serbia; Jes S. Lindholt, Department of Cardiothoracic and Vascular Surgery, Odense University Hospital, Odense, Denmark; Santi Trimarchi, Fondazione IRCCS Cà Granda Ospedale Maggiore Policlinico Milan, Department of Clinical and Community Sciences University of Milan, Milan, Italy; Riikka Tulamo, Helsinki University Hospital and University of Helsinki, Helsinki, Finland; Christopher P. Twine, North Bristol NHS Trust and University of Bristol, Bristol, United Kingdom; Frank Vermassen, Ghent University Hospital, Ghent, Belgium; Anders Wanhainen, Department of Surgical Sciences, Uppsala University, Uppsala, Sweden and Department of Surgical and Perioperative Sciences, Umeå University, Umeå, Sweden.

##### Document Reviewers

Martin Björck, Department of Surgical Sciences, Uppsala University, Uppsala, Sweden and Department of Surgery, Institute of Clinical Medicine, University of Tartu, Tartu, Estonia; Nicos Labropoulos, Stony Brook University Medical Center, Stony Brook, NY, United States of America; Fedor Lurie, Jobst Vascular Institute of Promedica and University of Michigan, Toledo, OH, United States of America; Armando Mansilha, Faculty of Medicine of University of Porto, Porto, Portugal; Isaac K. Nyamekye, Worcestershire Acute Hospitals NHS Trust, Worcestershire Royal Hospital, Worcester, United Kingdom; Marta Ramirez Ortega, Hospital La Luz-Quiron Salud, Madrid, Spain; Jorge Ulloa, Fundacion Santa Fe, Universidad de los Andes, Bogota, Colombia; Tomasz Urbanek, Department of General Surgery, Vascular Surgery, Angiology and Phlebology, Medical University of Silesia, Katowice, Poland; Andre van Rij, Department Surgical Sciences, University of Otago, Dunedin, New Zealand; Marc Vuylsteke, Vascular Surgery Sint-Andriesziekenhuis, Tielt, Belgium.

##### REFERENCES

- 1 Wittens C, Davies AH, Baekgaard N, Broholm R, Cavezzi A, Chastanet S, et al. Editor's Choice - Management of chronic venous disease: clinical practice guidelines of the European Society for Vascular Surgery (ESVS). *Eur J Vasc Endovasc Surg* 2015;49:678–737.
- 2 Kakkos SK, Gohel M, Baekgaard N, Bauersachs R, Bellmunt-Montoya S, Black SA, et al. Editor's Choice - European Society for

- Vascular Surgery (ESVS) 2021 clinical practice guidelines on the management of venous thrombosis. *Eur J Vasc Endovasc Surg* 2021;**61**:9–82.
- 3 Eklof B, Perrin M, Delis KT, Rutherford RB, Gloviczki P, American Venous Forum, et al. Updated terminology of chronic venous disorders: the VEIN-TERM transatlantic interdisciplinary consensus document. *J Vasc Surg* 2009;**49**:498–501.
  - 4 Beebe HG, Bergan JJ, Bergqvist D, Eklof B, Eriksson I, Goldman MP, et al. Classification and grading of chronic venous disease in the lower limbs. A consensus statement. *Eur J Vasc Endovasc Surg* 1996;**12**:487–92.
  - 5 Eklof B, Rutherford RB, Bergan JJ, Carpentier PH, Gloviczki P, Kistner RL, et al. Revision of the CEAP classification for chronic venous disorders: consensus statement. *J Vasc Surg* 2004;**40**:1248–52.
  - 6 Lurie F, Passman M, Meisner M, Dalsing M, Masuda E, Welch H, et al. The 2020 update of the CEAP classification system and reporting standards. *J Vasc Surg Venous Lymphat Disord* 2020;**8**:342–52.
  - 7 Salim S, Machin M, Patterson BO, Onida S, Davies AH. Global epidemiology of chronic venous disease: a systematic review with pooled prevalence analysis. *Ann Surg* 2021;**274**:971–6.
  - 8 Rabe E, Guex JJ, Puskas A, Scuderi A, Fernandez Quesada F, VCP Coordinators. Epidemiology of chronic venous disorders in geographically diverse populations: results from the Vein Consult Program. *Int Angiol* 2012;**31**:105–15.
  - 9 Evans CJ, Fowkes FG, Ruckley CV, Lee AJ. Prevalence of varicose veins and chronic venous insufficiency in men and women in the general population: Edinburgh Vein Study. *J Epidemiol Community Health* 1999;**53**:149–53.
  - 10 Robertson LA, Evans CJ, Lee AJ, Allan PL, Ruckley CV, Fowkes FG. Incidence and risk factors for venous reflux in the general population: Edinburgh Vein Study. *Eur J Vasc Endovasc Surg* 2014;**48**:208–14.
  - 11 Lee AJ, Robertson LA, Boghossian SM, Allan PL, Ruckley CV, Fowkes FG, et al. Progression of varicose veins and chronic venous insufficiency in the general population in the Edinburgh Vein Study. *J Vasc Surg Venous Lymphat Disord* 2015;**3**:18–26.
  - 12 Schultz-Ehrenburg U, Reich-Schupke S, Robak-Pawelczyk B, Rudolph T, Moll C, Weindorf N, et al. Prospective epidemiological study on the beginning of varicose veins. Bochum Study I–IV. *Phlebologie* 2009;**38**:17–25.
  - 13 Caggiati A, Bergan JJ, Gloviczki P, Jantet G, Wendell-Smith CP, Partsch H, et al. Nomenclature of the veins of the lower limbs: an international interdisciplinary consensus statement. *J Vasc Surg* 2002;**36**:416–22.
  - 14 Caggiati A, Bergan JJ, Gloviczki P, Eklof B, Allegra C, Partsch H, et al. Nomenclature of the veins of the lower limb: extensions, refinements, and clinical application. *J Vasc Surg* 2005;**41**:719–24.
  - 15 Cavezzi A, Labropoulos N, Partsch H, Ricci S, Caggiati A, Myers K, et al. Duplex ultrasound investigation of the veins in chronic venous disease of the lower limbs–UIP consensus document. Part II. Anatomy. *Eur J Vasc Endovasc Surg* 2006;**31**:288–99.
  - 16 De Maeseneer M, Pichot O, Cavezzi A, Earnshaw J, van Rij A, Lurie F, et al. Duplex ultrasound investigation of the veins of the lower limbs after treatment for varicose veins - UIP consensus document. *Eur J Vasc Endovasc Surg* 2011;**42**:89–102.
  - 17 Ortega-Santana F, Hernández-Morera P, Ruano-Ferrer F, Ortega-Centol A. Infrared illumination and subcutaneous venous network: can it be of help for the study of CEAP C<sub>1</sub> limbs? *Eur J Vasc Endovasc Surg* 2020;**59**:625–34.
  - 18 Phillips MN, Jones GT, van Rij AM, Zhang M. Micro-venous valves in the superficial veins of the human lower limb. *Clin Anat* 2004;**17**:55–60.
  - 19 Vincent JR, Jones GT, Hill GB, van Rij AM. Failure of micro-venous valves in small superficial veins is a key to the skin changes of venous insufficiency. *J Vasc Surg* 2011;**54**(Suppl. 6):62S–9S.
  - 20 Raffetto JD. Pathophysiology of chronic venous disease and venous ulcers. *Surg Clin North Am* 2018;**98**:337–47.
  - 21 Mansilha A, Sousa J. Pathophysiological mechanisms of chronic venous disease and implications for venoactive drug therapy. *Int J Mol Sci* 2018;**19**:1669.
  - 22 Castro-Ferreira R, Cardoso R, Leite-Moreira A, Mansilha A. The role of endothelial dysfunction and inflammation in chronic venous disease. *Ann Vasc Surg* 2018;**46**:380–93.
  - 23 Labropoulos N, Giannoukas AD, Delis K, Mansour MA, Kang SS, Nicolaides AN, et al. Where does venous reflux start? *J Vasc Surg* 1997;**26**:736–42.
  - 24 Lee BB, Nicolaides AN, Myers K, Meissner M, Kalodiki E, Allegra C, et al. Venous hemodynamic changes in lower limb venous disease: the UIP consensus according to scientific evidence. *Int Angiol* 2016;**35**:236–352.
  - 25 Labropoulos N, Patel PJ, Tiongson JE, Pryor L, Leon Jr LR, Tassiopoulos AK. Patterns of venous reflux and obstruction in patients with skin damage due to chronic venous disease. *Vasc Endovascular Surg* 2007;**41**:33–40.
  - 26 Bollinger A, Leu AJ, Hoffmann U, Franzeck UK. Microvascular changes in venous disease: an update. *Angiology* 1997;**48**:27–32.
  - 27 Raju S, Knight A, Lamanilao L, Pace N, Jones T. Peripheral venous hypertension in chronic venous disease. *J Vasc Surg Venous Lymphat Disord* 2019;**7**:706–14.
  - 28 Perrin M, Eklof B, Van Rij A, Labropoulos N, Vasquez M, Nicolaides A, et al. Venous symptoms: the SYM Vein Consensus statement developed under the auspices of the European Venous Forum. *Int Angiol* 2016;**35**:374–98.
  - 29 Van der Velden SK, Shadid NH, Nelemans PJ, Sommer A. How specific are venous symptoms for diagnosis of chronic venous disease? *Phlebology* 2014;**29**:580–6.
  - 30 Wrona M, Jockel KH, Pannier F, Bock E, Hoffmann B, Rabe E. Association of venous disorders with leg symptoms: results from the Bonn Vein Study 1. *Eur J Vasc Endovasc Surg* 2015;**50**:360–7.
  - 31 Vuylsteke ME, Thomis S, Guillaume G, Modliszewski ML, Weides N, Staelens I. Epidemiological study on chronic venous disease in Belgium and Luxembourg: prevalence, risk factors, and symptomatology. *Eur J Vasc Endovasc Surg* 2015;**49**:432–9.
  - 32 Delis KT, Bountouroglou D, Mansfield AO. Venous claudication in iliofemoral thrombosis: long-term effects on venous hemodynamics, clinical status, and quality of life. *Ann Surg* 2004;**239**:118–26.
  - 33 Chang SL, Huang YL, Lee MC, Hu S, Hsiao YC, Chang SW, et al. Association of varicose veins with incident venous thromboembolism and peripheral artery disease. *JAMA* 2018;**319**:807–17.
  - 34 Serra R, Ielapi N, Bevacqua E, Rizzuto A, De Caridi G, Massara M, et al. Haemorrhage from varicose veins and varicose ulceration: a systematic review. *Int Wound J* 2018;**15**:829–33.
  - 35 Vasquez M, Rabe E, McLafferty R, Shortell C, Marston W, Gillespie D, et al. Revision of the venous clinical severity score: venous outcomes consensus statement: special communication of the American Venous Forum Ad Hoc Outcomes Working Group. *J Vasc Surg* 2010;**52**:1387–96.
  - 36 Passman MA, McLafferty RB, Lentz MF, Nagre SB, Iafrafi MD, Bohannon WT, et al. Validation of Venous Clinical Severity Score (VCSS) with other venous severity assessment tools from the American Venous Forum, National Venous Screening Program. *J Vasc Surg* 2011;**54**(6 Suppl):2S–9S.
  - 37 Villalta SBP, Picolli A, Lensing A, Prins M, Prandoni P. Assessment of validity and reproducibility of a clinical scale for the post thrombotic syndrome. *Haemostasis* 1994;**24**:157.
  - 38 Kahn SR. Measurement properties of the Villalta scale to define and classify the severity of the post-thrombotic syndrome. *J Thromb Haemost* 2009;**7**:884–8.



- 39 Garratt AM, Macdonald LM, Ruta DA, Russell IT, Buckingham JK, Krukowski ZH. Towards measurement of outcome for patients with varicose veins. *Qual Health Care* 1993;2:5–10.
- 40 Launois R, Reboul-Marty J, Henry B. Construction and validation of a quality of life questionnaire in chronic lower limb venous insufficiency (CIVIQ). *Qual Life Res* 1996;5:539–54.
- 41 Lamping DL, Schroter S, Kurz X, Kahn SR, Abenhaim L. Evaluation of outcomes in chronic venous disorders of the leg: development of a scientifically rigorous, patient-reported measure of symptoms and quality of life. *J Vasc Surg* 2003;37:410–9.
- 42 Rautio T, Perälä J, Biancari F, Wiik H, Ohtonen P, Haukipuro K, et al. Accuracy of hand-held Doppler in planning the operation for primary varicose veins. *Eur J Vasc Endovasc Surg* 2002;24:450–5.
- 43 Blomgren L, Johansson G, Emanuelsson L, Dahlberg-Akerman A, Thermanius P, Bergqvist D. Late follow-up of a randomized trial of routine duplex imaging before varicose vein surgery. *Br J Surg* 2011;98:1112–6.
- 44 Coleridge-Smith P, Labropoulos N, Partsch H, Myers K, Nicolaides A, Cavezzi A. Duplex ultrasound investigation of the veins in chronic venous disease of the lower limbs—UIP consensus document. Part I. Basic principles. *Eur J Vasc Endovasc Surg* 2006;31:83–92.
- 45 Labropoulos N, Tiongson J, Pryor L, Tassiopoulos AK, Kang SS, Mansour M, et al. Definition of venous reflux in lower-extremity veins. *J Vasc Surg* 2003;38:793–8.
- 46 Mendoza E, Blattler W, Amsler F. Great saphenous vein diameter at the saphenofemoral junction and proximal thigh as parameters of venous disease class. *Eur J Vasc Endovasc Surg* 2013;45:76–83.
- 47 Hamel-Desnos CM, De Maeseneer M, Josnin M, Gillet JL, Allaert FA, DIAGRAVES Study Group. Great saphenous vein diameters in phlebological practice in France: a report of the DIAGRAVES Study by the French Society of Phlebology. *Eur J Vasc Endovasc Surg* 2019;58:96–103.
- 48 Stuart WP, Adam DJ, Allan PL, Ruckley CV, Bradbury AW. The relationship between the number, competence, and diameter of medial calf perforating veins and the clinical status in healthy subjects and patients with lower-limb venous disease. *J Vasc Surg* 2000;32:138–43.
- 49 Sandri JL, Barros FS, Pontes S, Jacques C, Salles-Cunha SX. Diameter-reflux relationship in perforating veins of patients with varicose veins. *J Vasc Surg* 1999;30:867–74.
- 50 Labropoulos N, Jasinski PT, Adrahtas D, Gasparis AP, Meissner MH. A standardized ultrasound approach to pelvic congestion syndrome. *Phlebology* 2017;32:608–19.
- 51 Metzger PB, Rossi FH, Kambara AM, Izukawa NM, Saleh MH, Pinto IM, et al. Criteria for detecting significant chronic iliac venous obstructions with duplex ultrasound. *J Vasc Surg Venous Lymphat Disord* 2016;4:18–27.
- 52 Sloves J, Almeida JI. Venous duplex ultrasound protocol for ilioacaval disease. *J Vasc Surg Venous Lymphat Disord* 2018;6:748–57.
- 53 Arnoldussen CW, de Graaf R, Wittens CH, de Haan MW. Value of magnetic resonance venography and computed tomographic venography in lower extremity chronic venous disease. *Phlebology* 2013;28(Suppl 1):169–75.
- 54 Uhl JF. Three-dimensional modelling of the venous system by direct multislice helical computed tomography venography: technique, indications and results. *Phlebology* 2012;27:270–88.
- 55 Helyar VG, Gupta Y, Blakeway L, Charles-Edwards G, Katsanos K, Karunanithy N. Depiction of lower limb venous anatomy in patients undergoing interventional deep venous reconstruction—the role of balanced steady state free precession MRI. *Br J Radiol* 2018;91:20170005.
- 56 Coelho A, O'Sullivan G. Usefulness of direct computed tomography venography in predicting inflow for venous reconstruction in chronic post-thrombotic syndrome. *Cardiovasc Intervent Radiol* 2019;42:677–84.
- 57 Lau I, Png CYM, Eswarappa M, Miller M, Kumar S, Tadros R, et al. Defining the utility of anteroposterior venography in the diagnosis of venous iliofemoral obstruction. *J Vasc Surg Venous Lymphat Disord* 2019;7:514–21.
- 58 Gagne PJ, Tahara RW, Fastabend CP, Dzieciuchowicz L, Marston W, Vedantham S, et al. Venography versus intravascular ultrasound for diagnosing and treating iliofemoral vein obstruction. *J Vasc Surg Venous Lymphat Disord* 2017;5:678–87.
- 59 Lattimer CR, Mendoza E. Reappraisal of the utility of the tilt-table in the investigation of venous disease. *Eur J Vasc Endovasc Surg* 2016;52:854–61.
- 60 Raju S, Knepper J, May C, Knight A, Pace N, Jayaraj A. Ambulatory venous pressure, air plethysmography, and the role of calf venous pump in chronic venous disease. *J Vasc Surg Venous Lymphat Disord* 2019;7:428–40.
- 61 Lattimer CR, Doucet S, Geroulakos G, Kalodiki E. Validation of the novel venous drainage index with stepwise increases in thigh compression pressure in the quantification of venous obstruction. *J Vasc Surg Venous Lymphat Disord* 2017;5:88–95.
- 62 Rosfors S, Persson LM, Blomgren L. Computerized venous strain-gauge plethysmography is a reliable method for measuring venous function. *Eur J Vasc Endovasc Surg* 2014;47:81–6.
- 63 Lattimer CR, Mendoza E. Which venous patients need to be investigated with air-plethysmography and why? *Phlebology* 2019;26:16–25.
- 64 Kalodiki E, Azzam M, Schnatterbeck P, Geroulakos G, Lattimer CR. The Discord Outcome Analysis (DOA) as a reporting standard at three months and five years in randomised varicose vein treatment trials. *Eur J Vasc Endovasc Surg* 2019;57:267–74.
- 65 Nelzen POE, Skoog J, Oster M, Zachrisson H. Impact on venous haemodynamics after treatment of great saphenous vein incompetence using plethysmography and duplex ultrasound. *Phlebology* 2020;35:495–504.
- 66 Araujo DN, Ribeiro CT, Maciel AC, Bruno SS, Fregonezi GA, Dias FA. Physical exercise for the treatment of non-ulcerated chronic venous insufficiency. *Cochrane Database Syst Rev* 2016;12:CD010637.
- 67 Caggiati A, De Maeseneer M, Cavezzi A, Mosti G, Morrison N. Rehabilitation of patients with venous diseases of the lower limbs: state of the art. *Phlebology* 2018;33:663–71.
- 68 Gurdal Karakelle S, Ipek Y, Tulin O, Alpogut IU. The efficiency of exercise training in patients with venous insufficiency: a double blinded, randomized controlled trial. *Phlebology* 2021;36:440–9.
- 69 Silva KLS, Figueiredo EAB, Lopes CP, Vianna MVA, Lima VP, Figueiredo PHS, et al. The impact of exercise training on calf pump function, muscle strength, ankle range of motion, and health-related quality of life in patients with chronic venous insufficiency at different stages of severity: a systematic review. *J Vasc Bras* 2021;20:e20200125.
- 70 Kahn SR, Shrier I, Shapiro S, Houweling AH, Hirsch AM, Reid RD, et al. Six-month exercise training program to treat post-thrombotic syndrome: a randomized controlled two-centre trial. *CMAJ* 2011;183:37–44.
- 71 Kelechi TJ, Dooley MJ, Mueller M, Madisetti M, Prentice MA. Symptoms associated with chronic venous disease in response to a cooling treatment compared to placebo: a randomized clinical trial. *J Wound Ostomy Cont Nurs* 2018;45:301–9.
- 72 de Moraes Silva MA, Nakano LC, Cisneros LL, Miranda F Jr. Balneotherapy for chronic venous insufficiency. *Cochrane Database Syst Rev* 2019;8:CD013085.
- 73 Sritharan K, Lane TR, Davies AH. The burden of depression in patients with symptomatic varicose veins. *Eur J Vasc Endovasc Surg* 2012;43:480–4.
- 74 Rabe E, Partsch H, Morrison N, Meissner MH, Mosti G, Lattimer CR, et al. Risks and contraindications of medical



- compression treatment - a critical reappraisal. An international consensus statement. *Phlebology* 2020;**35**:447–60.
- 75 Benigni JP, Sadoun S, Allaert FA, Vin F. Efficacy of Class 1 elastic compression stockings in the early stages of chronic venous disease. A comparative study. *Int Angiol* 2003;**22**:383–92.
  - 76 Kakkos SK, Timpilis M, Patrinos P, Nikolakopoulos KM, Papageorgopoulou CP, Kouri AK, et al. Acute effects of graduated elastic compression stockings in patients with symptomatic varicose veins: a randomised double blind placebo controlled trial. *Eur J Vasc Endovasc Surg* 2018;**55**:118–25.
  - 77 Mosti G, Picerni P, Partsch H. Compression stockings with moderate pressure are able to reduce chronic leg oedema. *Phlebology* 2012;**27**:289–96.
  - 78 Mosti G, Partsch H. Bandages or double stockings for the initial therapy of venous oedema? A randomized, controlled pilot study. *Eur J Vasc Endovasc Surg* 2013;**46**:142–8.
  - 79 Mosti G, Cavezzi A, Partsch H, Urso S, Campana F. Adjustable velcro compression devices are more effective than inelastic bandages in reducing venous edema in the initial treatment phase: a randomized controlled trial. *Eur J Vasc Endovasc Surg* 2015;**50**:368–74.
  - 80 Couzan S, Leizorovicz A, Laporte S, Mismetti P, Pouget JF, Chapelle C, et al. A randomized double-blind trial of upward progressive versus degressive compressive stockings in patients with moderate to severe chronic venous insufficiency. *J Vasc Surg* 2012;**56**:1344–50.
  - 81 Mosti G, Partsch H. Improvement of venous pumping function by double progressive compression stockings: higher pressure over the calf is more important than a graduated pressure profile. *Eur J Vasc Endovasc Surg* 2014;**47**:545–9.
  - 82 Mosti G, Partsch H. Occupational leg oedema is more reduced by antigraduated than by graduated stockings. *Eur J Vasc Endovasc Surg* 2013;**45**:523–7.
  - 83 Riebe H, Korschake W, Haase H, Junger M. Advantages and disadvantages of graduated and inverse graduated compression hosiery in patients with chronic venous insufficiency and healthy volunteers: a prospective, mono-centric, blinded, open randomised, controlled and cross-over trial. *Phlebology* 2018;**33**:14–26.
  - 84 Vandongen YK, Stacey MC. Graduated compression elastic stockings reduce lipodermatosclerosis and ulcer recurrence. *Phlebology* 2000;**15**:33–7.
  - 85 Ginsberg JS, Hirsh J, Julian J, Vander LaandeVries M, Magier D, MacKinnon B, et al. Prevention and treatment of postphlebotic syndrome: results of a 3-part study. *Arch Intern Med* 2001;**161**:2105–9.
  - 86 Frulla M, Marchiori A, Sartor D, Mosena L, Tormene D, Concolato A, et al. Elastic stockings, hydroxyethylrutosides or both for the treatment of post-thrombotic syndrome. *Thromb Haemost* 2005;**93**:183–5.
  - 87 Lattimer CR, Azzam M, Kalodiki E, Makris GC, Geroulakos G. Compression stockings significantly improve hemodynamic performance in post-thrombotic syndrome irrespective of class or length. *J Vasc Surg* 2013;**58**:158–65.
  - 88 Palfreyman SJ, Michaels JA. A systematic review of compression hosiery for uncomplicated varicose veins. *Phlebology* 2009;**24**(Suppl 1):13–33.
  - 89 Kostas TI, Ioannou CV, Drygiannakis I, Georgarakos E, Kounos C, Tsetis D, et al. Chronic venous disease progression and modification of predisposing factors. *J Vasc Surg* 2010;**51**:900–7.
  - 90 Kankam HKN, Lim CS, Fiorentino F, Davies AH, Gohel MS. A summation analysis of compliance and complications of compression hosiery for patients with chronic venous disease or post-thrombotic syndrome. *Eur J Vasc Endovasc Surg* 2018;**55**:406–16.
  - 91 Ayala A, Guerra JD, Ulloa JH, Kabnick L. Compliance with compression therapy in primary chronic venous disease: results from a tropical country. *Phlebology* 2019;**34**:272–7.
  - 92 Uhl JF, Benigni JP, Chahim M, Frederic D. Prospective randomized controlled study of patient compliance in using a compression stocking: importance of recommendations of the practitioner as a factor for better compliance. *Phlebology* 2018;**33**:36–43.
  - 93 Lurie F, Schwartz M. Patient-centered outcomes of a dual action pneumatic compression device in comparison to compression stockings for patients with chronic venous disease. *J Vasc Surg Venous Lymphat Disord* 2017;**5**:699–706.
  - 94 Sippel K, Seifert B, Hafner J. Donning devices (foot slips and frames) enable elderly people with severe chronic venous insufficiency to put on compression stockings. *Eur J Vasc Endovasc Surg* 2015;**49**:221–9.
  - 95 Buset CS, Fleischer J, Kluge R, Graf NT, Mosti G, Partsch H, et al. Compression stocking with 100% donning and doffing success: an open label randomised controlled trial. *Eur J Vasc Endovasc Surg* 2021;**61**:137–44.
  - 96 Azirar S, Appelen D, Prins MH, Neumann MH, de Feiter AN, Kolbach DN. Compression therapy for treating post-thrombotic syndrome. *Cochrane Database Syst Rev* 2019;**9**:CD004177.
  - 97 Williams KJ, Ravikumar R, Gaweesh AS, Moore HM, Lifshitz AD, Lane TR, et al. A review of the evidence to support neuromuscular electrical stimulation in the prevention and management of venous disease. *Adv Exp Med Biol* 2017;**906**:377–86.
  - 98 Benigni JP, Uhl JF, Balet F, Filori P, Chahim M. Evaluation of three different devices to reduce stasis edema in poorly mobile nursing home patients. *Int Angiol* 2018;**37**:322–6.
  - 99 Holan V, Jiraskova M, Pankova R. Hydrostatic compression - a new treatment of leg ulcers. *Vasa* 1976;**5**:355–9.
  - 100 Caggiati A, Lattimer C, Kalodiki E, Oberto S, Bergamo G, Kontothanassis D, et al. Underwater sonography of leg veins. *EJVES Short Rep* 2018;**41**:13–5.
  - 101 Mosti G, Bergamo G, Oberto S, Bissacco D, Chiodi L, Kontothanassis D, et al. The feasibility of underwater computerised strain gauge plethysmography and the effects of hydrostatic pressure on the leg venous haemodynamics. *EJVES Vasc Forum* 2020;**47**:60–2.
  - 102 Mosti G, Caggiati A. The effects of water immersion and walking on leg volume, ankle circumference and epifascial thickness in healthy subjects with occupational edema. *Phlebology* 2021;**36**:473–80.
  - 103 Menegatti E, Masiero S, Zamboni P, Avruscio G, Tessari M, Pagani A, et al. Randomized controlled trial on Dryland And Thermal Aquatic standardized exercise protocol for chronic venous disease (DATA study). *J Vasc Surg Venous Lymphat Disord* 2021;**9**:1226–34.
  - 104 Martinez-Zapata MJ, Vernooij RW, Uriona Tuma SM, Stein AT, Moreno RM, Vargas E, et al. Phlebotonics for venous insufficiency. *Cochrane Database Syst Rev* 2016;**4**:CD003229.
  - 105 Martinez-Zapata MJ, Vernooij RW, Simancas-Racines D, Uriona Tuma SM, Stein AT, Moreno Carriles RMM, et al. Phlebotonics for venous insufficiency. *Cochrane Database Syst Rev* 2020;**11**:CD003229.
  - 106 Allaert FA. Meta-analysis of the impact of the principal venoactive drugs agents on malleolar venous edema. *Int Angiol* 2012;**31**:310–5.
  - 107 Kakkos SK, Allaert FA. Efficacy of Ruscus extract, HMC and vitamin C, constituents of Cyclo 3 fort(R), on improving individual venous symptoms and edema: a systematic review and meta-analysis of randomized double-blind placebo-controlled trials. *Int Angiol* 2017;**36**:93–106.
  - 108 Kakkos SK, Nicolaidis AN. Efficacy of micronized purified flavonoid fraction (Daflon(R)) on improving individual symptoms, signs

- and quality of life in patients with chronic venous disease: a systematic review and meta-analysis of randomized double-blind placebo-controlled trials. *Int Angiol* 2018;**37**:143–54.
- 109 Ciapponi A, Laffaire E, Roque M. Calcium dobesilate for chronic venous insufficiency: a systematic review. *Angiology* 2004;**55**:147–54.
  - 110 Flota-Cervera F, Flota-Ruiz C, Trevino C, Berber A. Randomized, double blind, placebo-controlled clinical trial to evaluate the lymphagogue effect and clinical efficacy of calcium dobesilate in chronic venous disease. *Angiology* 2008;**59**:352–6.
  - 111 Martinez-Zapata MJ, Moreno RM, Gich I, Urrutia G, Bonfill X, Chronic Venous Insufficiency Study Group. A randomized, double-blind multicentre clinical trial comparing the efficacy of calcium dobesilate with placebo in the treatment of chronic venous disease. *Eur J Vasc Endovasc Surg* 2008;**35**:358–65.
  - 112 Rabe E, Ballarini S, Lehr L, Doxium EDXSG. A randomized, double-blind, placebo-controlled, clinical study on the efficacy and safety of calcium dobesilate in the treatment of chronic venous insufficiency. *Phlebology* 2016;**31**:264–74.
  - 113 Rabe E, Jaeger KA, Bulitta M, Pannier F. Calcium dobesilate in patients suffering from chronic venous insufficiency: a double-blind, placebo-controlled, clinical trial. *Phlebology* 2011;**26**:162–8.
  - 114 Pittler MH, Ernst E. Horse chestnut seed extract for chronic venous insufficiency. *Cochrane Database Syst Rev* 2012;**11**:CD003230.
  - 115 Aziz Z, Tang WL, Chong NJ, Tho LY. A systematic review of the efficacy and tolerability of hydroxyethylrutosides for improvement of the signs and symptoms of chronic venous insufficiency. *J Clin Pharm Ther* 2015;**40**:177–85.
  - 116 Kiesewetter H, Koscielny J, Kalus U, Vix JM, Peil H, Petrini O, et al. Efficacy of orally administered extract of red vine leaf AS 195 (folia vitis viniferae) in chronic venous insufficiency (stages I-II). A randomized, double-blind, placebo-controlled trial. *Arzneimittelforschung* 2000;**50**:109–17.
  - 117 Kalus U, Koscielny J, Grigorov A, Schaefer E, Peil H, Kiesewetter H. Improvement of cutaneous microcirculation and oxygen supply in patients with chronic venous insufficiency by orally administered extract of red vine leaves AS 195: a randomised, double-blind, placebo-controlled, crossover study. *Drugs R D* 2004;**5**:63–71.
  - 118 Rabe E, Stucker M, Esperester A, Schafer E, Ottillinger B. Efficacy and tolerability of a red-vine-leaf extract in patients suffering from chronic venous insufficiency—results of a double-blind placebo-controlled study. *Eur J Vasc Endovasc Surg* 2011;**41**:540–7.
  - 119 Bignamini AA, Matuska J. Sulodexide for the symptoms and signs of chronic venous disease: a systematic review and meta-analysis. *Adv Ther* 2020;**37**:1013–33.
  - 120 Kakkos SK, Papageorgopoulou CP, Nikolakopoulos KM, Kalogeropoulou C, Tsolakis IA. Validation of the 3D SYM VEIN symptom assessment tool. *Eur J Vasc Endovasc Surg* 2020;**60**:587–93.
  - 121 Carradice D, Wallace T, Gohil R, Chetter I. A comparison of the effectiveness of treating those with and without the complications of superficial venous insufficiency. *Ann Surg* 2014;**260**:396–401.
  - 122 Michaels JA, Brazier JE, Campbell WB, MacIntyre JB, Palfreyman SJ, Ratcliffe J. Randomized clinical trial comparing surgery with conservative treatment for uncomplicated varicose veins. *Br J Surg* 2006;**93**:175–81.
  - 123 Ratcliffe J, Brazier JE, Campbell WB, Palfreyman S, MacIntyre JB, Michaels JA. Cost-effectiveness analysis of surgery versus conservative treatment for uncomplicated varicose veins in a randomized clinical trial. *Br J Surg* 2006;**93**:182–6.
  - 124 Marsden G, Perry M, Bradbury A, Hickey N, Kelley K, Trender H, et al. A cost-effectiveness analysis of surgery, endothermal ablation, ultrasound-guided foam sclerotherapy and compression stockings for symptomatic varicose veins. *Eur J Vasc Endovasc Surg* 2015;**50**:794–801.
  - 125 Carroll C, Hummel S, Leaviss J, Ren S, Stevens JW, Cantrell A, et al. Systematic review, network meta-analysis and exploratory cost-effectiveness model of randomized trials of minimally invasive techniques versus surgery for varicose veins. *Br J Surg* 2014;**101**:1040–52.
  - 126 Masuda E, Ozsvath K, Vossler J, Woo K, Kistner R, Lurie F, et al. The 2020 appropriate use criteria for chronic lower extremity venous disease of the American Venous Forum, the Society for Vascular Surgery, the American Vein and Lymphatic Society, and the Society of Interventional Radiology. *J Vasc Surg Venous Lymphat Disord* 2020;**8**:505–25.
  - 127 van der Velden SK, van den Bos RR, Pichot O, Nijsten T, De Maeseneer M. Towards an individualized management strategy for patients with chronic venous disease: results of a Delphi consensus. *Phlebology* 2018;**33**:492–9.
  - 128 Dermody M, O'Donnell TF, Balk EM. Complications of endovenous ablation in randomized controlled trials. *J Vasc Surg Venous Lymphat Disord* 2013;**1**:427–36.
  - 129 Brittenden J, Cooper D, Dimitrova M, Scotland G, Cotton SC, Elders A, et al. Five-year outcomes of a randomized trial of treatments for varicose veins. *N Engl J Med* 2019;**381**:912–22.
  - 130 Somasundaram SK, Weerasekera A, Worku D, Balasubramanian RK, Lister D, Valenti D, et al. Office based endovenous radiofrequency ablation of truncal veins: a case for moving varicose vein treatment out of operating theatres. *Eur J Vasc Endovasc Surg* 2019;**58**:410–4.
  - 131 Varetto G, Gibello L, Frola E, Trevisan A, Trucco A, Contessa L, et al. Day surgery versus Outpatient setting for endovenous laser ablation treatment. A prospective cohort study. *Int J Surg* 2018;**51**:180–3.
  - 132 Gauw SA, Lawson JA, van Vlijmen-van Keulen CJ, Pronk P, Gaastra MT, Mooij MC. Five-year follow-up of a randomized, controlled trial comparing saphenofemoral ligation and stripping of the great saphenous vein with endovenous laser ablation (980 nm) using local tumescent anesthesia. *J Vasc Surg* 2016;**63**:420–8.
  - 133 Rasmussen LH, Lawaetz M, Bjoern L, Vennits B, Blemings A, Eklof B. Randomized clinical trial comparing endovenous laser ablation, radiofrequency ablation, foam sclerotherapy and surgical stripping for great saphenous varicose veins. *Br J Surg* 2011;**98**:1079–87.
  - 134 Rass K, Frings N, Glowacki P, Graber S, Tilgen W, Vogt T. Same site recurrence is more frequent after endovenous laser ablation compared with high ligation and stripping of the great saphenous vein: 5 year results of a randomized clinical trial (RELACS Study). *Eur J Vasc Endovasc Surg* 2015;**50**:648–56.
  - 135 Kabnick LS. Varicose veins: endovenous treatment. In: Cronenwett JL, Johnston KW, editors. *Rutherford's Vascular Surgery*. 7th ed. Philadelphia: Saunders; 2010. p. 871–88.
  - 136 De Hert S, De Baerdemaeker L, De Maeseneer M. What the phlebologist should know about local anesthetics. *Phlebology* 2014;**29**:428–41.
  - 137 Wright TF, Brunetti GF, Kennedy P. Lidocaine safety after saphenous vein tumescent anesthesia. *Phlebology* 2019;**34**:683–9.
  - 138 Nandhra S, Wallace T, El-Sheikha J, Leung C, Carradice D, Chetter I. A randomised clinical trial of buffered tumescent local anaesthesia during endothermal ablation for superficial venous incompetence. *Eur J Vasc Endovasc Surg* 2018;**56**:699–708.
  - 139 Alam M, Worley B. Buffered lidocaine: the standard of care for cutaneous procedures. *J Am Acad Dermatol* 2020;**83**:166–7.
  - 140 Aherne TM, Zafar AS, Gourlay D, O'Neill DC, Bashar K, Yap CJ, et al. Does longitudinal or transverse orientation of the ultrasound probe improve cannulation success in minimally invasive venous surgery: a multicentre randomised controlled trial. *Phlebology* 2020;**35**:686–92.

- 141 Gornati VC, Utsunomia K, Labropoulos N. Challenges in advancing the laser fiber through the great saphenous vein during endovenous ablation and strategies to overcome them. *Phlebology* 2019;**34**:530–5.
- 142 Doganci S, Yildirim V, Demirkilic U. Does puncture site affect the rate of nerve injuries following endovenous laser ablation of the small saphenous veins? *Eur J Vasc Endovasc Surg* 2011;**41**:400–5.
- 143 Rabe E, Breu FX, Cavezzi A, Coleridge Smith P, Frullini A, Gillet JL, et al. European guidelines for sclerotherapy in chronic venous disorders. *Phlebology* 2014;**29**:338–54.
- 144 El-Sheikha J, Nandhra S, Carradice D, Acey C, Smith GE, Campbell B, et al. Compression regimes after endovenous ablation for superficial venous insufficiency—A survey of members of the Vascular Society of Great Britain and Ireland. *Phlebology* 2016;**31**:16–22.
- 145 Biswas S, Clark A, Shields DA. Randomised clinical trial of the duration of compression therapy after varicose vein surgery. *Eur J Vasc Endovasc Surg* 2007;**33**:631–7.
- 146 Huang TW, Chen SL, Bai CH, Wu CH, Tam KW. The optimal duration of compression therapy following varicose vein surgery: a meta-analysis of randomized controlled trials. *Eur J Vasc Endovasc Surg* 2013;**45**:397–402.
- 147 Partsch B, Partsch H. Which pressure do we need to compress the great saphenous vein on the thigh? *Dermatol Surg* 2008;**34**:1726–8.
- 148 Cavezzi A, Mosti G, Colucci R, Quinzi V, Bastiani L, Urso SU. Compression with 23 mmHg or 35 mmHg stockings after saphenous catheter foam sclerotherapy and phlebectomy of varicose veins: a randomized controlled study. *Phlebology* 2019;**34**:98–106.
- 149 Hamel-Desnos CM, Guias BJ, Desnos PR, Mesgard A. Foam sclerotherapy of the saphenous veins: randomised controlled trial with or without compression. *Eur J Vasc Endovasc Surg* 2010;**39**:500–7.
- 150 Ye K, Wang R, Qin J, Yang X, Yin M, Liu X, et al. Post-operative benefit of compression therapy after endovenous laser ablation for uncomplicated varicose veins: a randomised clinical trial. *Eur J Vasc Endovasc Surg* 2016;**52**:847–53.
- 151 Bootun R, Belramman A, Bolton-Saghaoui L, Lane TRA, Riga C, Davies AH. Randomized controlled trial of compression after endovenous thermal ablation of varicose veins (COMETA trial). *Ann Surg* 2021;**273**:232–9.
- 152 Onwudike M, Abbas K, Thompson P, McElvenny DM. Editor's Choice - Role of compression after radiofrequency ablation of varicose veins: a randomised controlled trial. *Eur J Vasc Endovasc Surg* 2020;**60**:108–17.
- 153 Pihlaja T, Romsa P, Ohtonen P, Jounila J, Pokela M. Post-procedural compression vs. no compression after radiofrequency ablation and concomitant foam sclerotherapy of varicose veins: a randomised controlled non-inferiority trial. *Eur J Vasc Endovasc Surg* 2020;**59**:73–80.
- 154 Lurie F, Lal BK, Antignani PL, Blebea J, Bush R, Caprini J, et al. Compression therapy after invasive treatment of superficial veins of the lower extremities: clinical practice guidelines of the American Venous Forum, Society for Vascular Surgery, American College of Phlebology, Society for Vascular Medicine, and International Union of Phlebology. *J Vasc Surg Venous Lymphat Disord* 2019;**7**:17–28.
- 155 Chou JH, Chen SY, Chen YT, Hsieh CH, Huang TW, Tam KW. Optimal duration of compression stocking therapy following endovenous thermal ablation for great saphenous vein insufficiency: a meta-analysis. *Int J Surg* 2019;**65**:113–9.
- 156 Wang H, Sun Z, Jiang W, Zhang Y, Li X, Wu Y. Postoperative prophylaxis of venous thromboembolism (VTE) in patients undergoing high ligation and stripping of the great saphenous vein (GSV). *Vasc Med* 2015;**20**:117–21.
- 157 San Norberto Garcia EM, Merino B, Taylor JH, Vizcaino I, Vaquero C. Low-molecular-weight heparin for prevention of venous thromboembolism after varicose vein surgery in moderate-risk patients: a randomized, controlled trial. *Ann Vasc Surg* 2013;**27**:940–6.
- 158 van Rij AM, Chai J, Hill GB, Christie RA. Incidence of deep vein thrombosis after varicose vein surgery. *Br J Surg* 2004;**91**:1582–5.
- 159 Puggioni A, Marks N, Hingorani A, Shiferson A, Alhalbouni S, Ascher E. The safety of radiofrequency ablation of the great saphenous vein in patients with previous venous thrombosis. *J Vasc Surg* 2009;**49**:1248–55.
- 160 Lurie F, Kistner RL. Pretreatment elevated D-dimer levels without systemic inflammatory response are associated with thrombotic complications of thermal ablation of the great saphenous vein. *J Vasc Surg Venous Lymphat Disord* 2013;**1**:154–8.
- 161 Dattani N, Shalhoub J, Nandhra S, Lane T, Abu-Own A, Elbasty A, et al. Reducing the risk of venous thromboembolism following superficial endovenous treatment: a UK and Republic of Ireland consensus study. *Phlebology* 2020;**35**:706–14.
- 162 Keo HH, Knoechel J, Spinedi L, Engelberger RP, Staub D, Regli C, et al. Thromboprophylaxis practice after outpatient endovenous thermal ablation. *J Vasc Surg Venous Lymphat Disord* 2021;**9**:916–24.
- 163 Uthoff H, Holtz D, Broz P, Staub D, Spinedi L. Rivaroxaban for thrombosis prophylaxis in endovenous laser ablation with and without phlebectomy. *J Vasc Surg Venous Lymphat Disord* 2017;**5**:515–23.
- 164 Myers KA, Jolley D, Clough A, Kirwan J. Outcome of ultrasound-guided sclerotherapy for varicose veins: medium-term results assessed by ultrasound surveillance. *Eur J Vasc Endovasc Surg* 2007;**33**:116–21.
- 165 Kibrik P, Chait J, Arustamyan M, Alsheekh A, Rajae S, Marks N, et al. Safety and efficacy of endovenous ablations in octogenarians, nonagenarians, and centenarians. *J Vasc Surg Venous Lymphat Disord* 2020;**8**:95–9.
- 166 Isobe JH, Sentell KC, Nichols LA, Simms CS. Twelve-month experience using reprocessed closurefast radiofrequency catheters. *J Vasc Surg Venous Lymphat Disord* 2014;**2**:115–6.
- 167 Shutze WP, Kane K, Fisher T, Doud Y, Lassiter G, Leuking R, et al. The effect of wavelength on endothermal heat-induced thrombosis incidence after endovenous laser ablation. *J Vasc Surg Venous Lymphat Disord* 2016;**4**:36–43.
- 168 Doganci S, Demirkilic U. Comparison of 980 nm laser and bare-tip fibre with 1470 nm laser and radial fibre in the treatment of great saphenous vein varicosities: a prospective randomised clinical trial. *Eur J Vasc Endovasc Surg* 2010;**40**:254–9.
- 169 Vuylsteke M, De Bo TH, Dompe G, Di Crisci D, Abbad C, Mordon S. Endovenous laser treatment: is there a clinical difference between using a 1500 nm and a 980 nm diode laser? A multicenter randomised clinical trial. *Int Angiol* 2011;**30**:327–34.
- 170 Hirokawa M, Ogawa T, Sugawara H, Shokoku S, Sato S. Comparison of 1470 nm laser and radial 2ring fiber with 980 nm laser and bare-tip fiber in endovenous laser ablation of saphenous varicose veins: a multicenter, prospective, randomized, non-blind study. *Ann Vasc Dis* 2015;**8**:282–9.
- 171 Malskat WS, Giang J, De Maeseneer MG, Nijsten TE, van den Bos RR. Randomized clinical trial of 940- versus 1470-nm endovenous laser ablation for great saphenous vein incompetence. *Br J Surg* 2016;**103**:192–8.
- 172 Arslan U, Calik E, Tort M, Yildiz Z, Tekin AI, Limandal HK, et al. More successful results with less energy in endovenous laser ablation treatment: long-term comparison of bare-tip fiber 980 nm laser and radial-tip fiber 1470 nm laser application. *Ann Vasc Surg* 2017;**45**:166–72.
- 173 Malskat WSJ, Engels LK, Hollestein LM, Nijsten T, van den Bos RR. Commonly used endovenous laser ablation (EVLA) parameters do not influence efficacy: results of a systematic review and meta-analysis. *Eur J Vasc Endovasc Surg* 2019;**58**:230–42.
- 174 De Maeseneer MGR, Biemans AAM, Pichot O. New concepts on recurrence of varicose veins according to the different treatment techniques. *Phlébologie* 2013;**66**:54–60.



- 175 Rasmussen L, Lawaetz M, Serup J, Bjoern L, Vennits B, Blemings A, et al. Randomized clinical trial comparing endovenous laser ablation, radiofrequency ablation, foam sclerotherapy, and surgical stripping for great saphenous varicose veins with 3-year follow-up. *J Vasc Surg Venous Lymphat Disord* 2013;1:349–56.
- 176 Winokur RS, Khilnani NM, Min RJ. Recurrence patterns after endovenous laser treatment of saphenous vein reflux. *Phlebology* 2016;31:496–500.
- 177 O'Donnell TF, Balk EM, Dermody M, Tangney E, Iafrati MD. Recurrence of varicose veins after endovenous ablation of the great saphenous vein in randomized trials. *J Vasc Surg Venous Lymphat Disord* 2016;4:97–105.
- 178 Spinedi L, Stricker H, Keo HH, Staub D, Uthoff H. Feasibility and safety of flush endovenous laser ablation of the great saphenous vein up to the saphenofemoral junction. *J Vasc Surg Venous Lymphat Disord* 2020;8:1006–13.
- 179 Proebstle TM, Alm BJ, Gockeritz O, Wenzel C, Noppeney T, Lebard C, et al. Five-year results from the prospective European multicentre cohort study on radiofrequency segmental thermal ablation for incompetent great saphenous veins. *Br J Surg* 2015;102:212–8.
- 180 Lawson JA, Gauw SA, van Vlijmen CJ, Pronk P, Gaastra MTW, Tangelder MJ, et al. Prospective comparative cohort study evaluating incompetent great saphenous vein closure using radiofrequency-powered segmental ablation or 1470-nm endovenous laser ablation with radial-tip fibers (Varico 2 study). *J Vasc Surg Venous Lymphat Disord* 2018;6:31–40.
- 181 Healy DA, Kimura S, Power D, Elhaj A, Abdeldaim Y, Cross KS, et al. A systematic review and meta-analysis of thrombotic events following endovenous thermal ablation of the great saphenous vein. *Eur J Vasc Endovasc Surg* 2018;56:410–24.
- 182 Nyamekye IK, Dattani N, Hayes W, Harding D, Holloway S, Newman J. A randomised controlled trial comparing three different radiofrequency technologies: short-term results of the 3-RF trial. *Eur J Vasc Endovasc Surg* 2019;58:401–8.
- 183 van den Bos RR, Malskat WS, De Maeseneer MG, de Roos KP, Groeneweg DA, Kockaert MA, et al. Randomized clinical trial of endovenous laser ablation versus steam ablation (LAST trial) for great saphenous varicose veins. *Br J Surg* 2014;101:1077–83.
- 184 Milleret R, Huot L, Nicolini P, Creton D, Roux AS, Decullier E, et al. Great saphenous vein ablation with steam injection: results of a multicentre study. *Eur J Vasc Endovasc Surg* 2013;45:391–6.
- 185 Yang L, Wang XP, Su WJ, Zhang Y, Wang Y. Randomized clinical trial of endovenous microwave ablation combined with high ligation versus conventional surgery for varicose veins. *Eur J Vasc Endovasc Surg* 2013;46:473–9.
- 186 Mao J, Zhang C, Wang Z, Gan S, Li K. A retrospective study comparing endovenous laser ablation and microwave ablation for great saphenous varicose veins. *Eur Rev Med Pharmacol Sci* 2012;16:873–7.
- 187 Santin BJ, Lohr JM, Panke TW, Neville PM, Felinski MM, Kuhn BA, et al. Venous duplex and pathologic differences in thrombus characteristics between de novo deep vein thrombi and endovenous heat-induced thrombi. *J Vasc Surg Venous Lymphat Disord* 2015;3:184–9.
- 188 Kabnick LS, Sadek M, Bjarnason H, Coleman DM, Dillavou ED, Hingorani AP, et al. Classification and treatment of endothermal heat-induced thrombosis: Recommendations from the American Venous Forum and the Society for Vascular Surgery. *J Vasc Surg Venous Lymphat Disord* 2021;9:6–22.
- 189 Kane K, Fisher T, Bennett M, Shutze Jr W, Hicks T, Grimsley B, et al. The incidence and outcome of endothermal heat-induced thrombosis after endovenous laser ablation. *Ann Vasc Surg* 2014;28:1744–50.
- 190 Lawrence PF, Chandra A, Wu M, Rigberg D, DeRubertis B, Gelabert H, et al. Classification of proximal endovenous closure levels and treatment algorithm. *J Vasc Surg* 2010;52:388–93.
- 191 Sadek M, Kabnick LS, Rockman CB, Berland TL, Zhou D, Chasin C, et al. Increasing ablation distance peripheral to the saphenofemoral junction may result in a diminished rate of endothermal heat-induced thrombosis. *J Vasc Surg Venous Lymphat Disord* 2013;1:257–62.
- 192 Hicks CW, DiBrito SR, Magruder JT, Weaver ML, Barenski C, Heller JA. Radiofrequency ablation with concomitant stab phlebectomy increases risk of endovenous heat-induced thrombosis. *J Vasc Surg Venous Lymphat Disord* 2017;5:200–9.
- 193 Nemoto H, Mo M, Ito T, Inoue Y, Obitsu Y, Kichikawa K, et al. Venous thromboembolism complications after endovenous laser ablation for varicose veins and role of duplex ultrasound scan. *J Vasc Surg Venous Lymphat Disord* 2019;7:817–23.
- 194 Dexter D, Kabnick L, Berland T, Jacobowitz G, Lamparello P, Maldonado T, et al. Complications of endovenous lasers. *Phlebology* 2012;27(1\_suppl):40–5.
- 195 Cao G, Gu HC, Wang JT, Huang Q, Cao JC. Comparison of endovenous laser treatment and high ligation in treatment of limb varicosity: a meta-analysis. *Int Wound J* 2019;16:696–702.
- 196 Carradice D, Mekako AI, Mazari FA, Samuel N, Hatfield J, Chetter IC. Randomized clinical trial of endovenous laser ablation compared with conventional surgery for great saphenous varicose veins. *Br J Surg* 2011;98:501–10.
- 197 Subramonia S, Lees T. Randomized clinical trial of radiofrequency ablation or conventional high ligation and stripping for great saphenous varicose veins. *Br J Surg* 2010;97:328–36.
- 198 Siribumrungwong B, Noorit P, Wilasrusmee C, Attia J, Thakkinstian A. A systematic review and meta-analysis of randomised controlled trials comparing endovenous ablation and surgical intervention in patients with varicose vein. *Eur J Vasc Endovasc Surg* 2012;44:214–23.
- 199 Darwood RJ, Theivacumar N, Dellagrammaticas D, Mavor AI, Gough MJ. Randomized clinical trial comparing endovenous laser ablation with surgery for the treatment of primary great saphenous varicose veins. *Br J Surg* 2008;95:294–301.
- 200 Whing J, Nandhra S, Nesbitt C, Stansby G. Interventions for great saphenous vein incompetence. *Cochrane Database Syst Rev* 2021;8:CD005624.
- 201 Hamann SAS, Giang J, De Maeseneer MGR, Nijsten TEC, van den Bos RR. Editor's Choice - Five year results of great saphenous vein treatment: a meta-analysis. *Eur J Vasc Endovasc Surg* 2017;54:760–70.
- 202 Kheirelseid EAH, Crowe G, Sehgal R, Liakopoulos D, Bela H, Mulkern E, et al. Systematic review and meta-analysis of randomized controlled trials evaluating long-term outcomes of endovenous management of lower extremity varicose veins. *J Vasc Surg Venous Lymphat Disord* 2018;6:256–70.
- 203 van der Velden SK, Biemans AA, De Maeseneer MG, Kockaert MA, Cuypers PW, Hollestein LM, et al. Five-year results of a randomized clinical trial of conventional surgery, endovenous laser ablation and ultrasound-guided foam sclerotherapy in patients with great saphenous varicose veins. *Br J Surg* 2015;102:1184–94.
- 204 He G, Zheng C, Yu MA, Zhang H. Comparison of ultrasound-guided endovenous laser ablation and radiofrequency for the varicose veins treatment: an updated meta-analysis. *Int J Surg* 2017;39:267–75.
- 205 Almeida JI, Javier JJ, Mackay EG, Bautista C, Cher DJ, Proebstle TM. Thirty-sixth-month follow-up of first-in-human use of cyanoacrylate adhesive for treatment of saphenous vein incompetence. *J Vasc Surg Venous Lymphat Disord* 2017;5:658–66.
- 206 Calik ES, Arslan U, Erkut B. Ablation therapy with cyanoacrylate glue and laser for refluxing great saphenous veins - a prospective randomised study. *Vasa* 2019;48:405–12.
- 207 Chan YC, Law Y, Cheung GC, Ting AC, Cheng SW. Cyanoacrylate glue used to treat great saphenous reflux: measures of outcome. *Phlebology* 2017;32:99–106.



- 208 Eroglu E, Yasim A. A randomised clinical trial comparing n-butyl cyanoacrylate, radiofrequency ablation and endovenous laser ablation for the treatment of superficial venous incompetence: two year follow up results. *Eur J Vasc Endovasc Surg* 2018;**56**: 553–60.
- 209 Garcia-Carpintero E, Carmona M, Chalco-Orrego JP, Gonzalez-Enriquez J, Imaz-Iglesia I. Systematic review and meta-analysis of endovenous cyanoacrylate adhesive ablation for incompetent saphenous veins. *J Vasc Surg Venous Lymphat Disord* 2020;**8**: 287–96.
- 210 Gibson K, Ferris B. Cyanoacrylate closure of incompetent great, small and accessory saphenous veins without the use of post-procedure compression: initial outcomes of a post-market evaluation of the VenaSeal System (the WAVES Study). *Vascular* 2017;**25**:149–56.
- 211 Morrison N, Kolluri R, Vasquez M, Madsen M, Jones A, Gibson K. Comparison of cyanoacrylate closure and radiofrequency ablation for the treatment of incompetent great saphenous veins: 36-month outcomes of the VeClose randomized controlled trial. *Phlebology* 2019;**34**:380–90.
- 212 Proebstle TM, Alm J, Dimitri S, Rasmussen L, Whiteley M, Lawson J, et al. The European multicenter cohort study on cyanoacrylate embolization of refluxing great saphenous veins. *J Vasc Surg Venous Lymphat Disord* 2015;**3**:2–7.
- 213 Vos CG, Unlu C, Bosma J, van Vlijmen CJ, de Nie AJ, Schreve MA. A systematic review and meta-analysis of two novel techniques of nonthermal endovenous ablation of the great saphenous vein. *J Vasc Surg Venous Lymphat Disord* 2017;**5**:880–96.
- 214 Park I, Kim D. Correlation between the immediate remnant stump length and vein diameter after cyanoacrylate closure using the VenaSeal system during treatment of an incompetent great saphenous vein. *Vasc Endovascular Surg* 2020;**54**:47–50.
- 215 Morrison N, Gibson K, Vasquez M, Weiss R, Jones A. Five-year extension study of patients from a randomized clinical trial (VeClose) comparing cyanoacrylate closure versus radiofrequency ablation for the treatment of incompetent great saphenous veins. *J Vasc Surg Venous Lymphat Disord* 2020;**8**: 978–89.
- 216 Gibson K, Minjarez R, Rinehardt E, Ferris B. Frequency and severity of hypersensitivity reactions in patients after VenaSeal cyanoacrylate treatment of superficial venous insufficiency. *Phlebology* 2020;**35**:337–44.
- 217 Parsi K, Roberts S, Kang M, Benson S, Baker L, Berman I, et al. Cyanoacrylate closure for peripheral veins: Consensus document of the Australasian College of Phlebology. *Phlebology* 2020;**35**: 153–75.
- 218 Cho S, Gibson K, Lee S, Kim S, Joh J. Incidence, classification, and risk factors of endovenous glue-induced thrombosis after cyanoacrylate closure of the incompetent saphenous vein. *J Vasc Surg Venous Lymphat Disord* 2020;**8**:991–8.
- 219 Hamel-Desnos C, Allaert FA. Liquid versus foam sclerotherapy. *Phlebology* 2009;**24**:240–6.
- 220 Hafner F, Froehlich H, Gary T, Brodmann M. Intra-arterial injection, a rare but serious complication of sclerotherapy. *Phlebology* 2013;**28**:64–73.
- 221 Shadid N, Nelemans P, Lawson J, Sommer A. Predictors of recurrence of great saphenous vein reflux following treatment with ultrasound-guided foamsclerotherapy. *Phlebology* 2015;**30**:194–9.
- 222 Venermo M, Saarinen J, Eskelinen E, Vähäaho S, Saarinen E, Railo M, et al. Randomized clinical trial comparing surgery, endovenous laser ablation and ultrasound-guided foam sclerotherapy for the treatment of great saphenous varicose veins. *Br J Surg* 2016;**103**:1438–44.
- 223 Darvall KA, Bate GR, Bradbury AW. Patient-reported outcomes 5–8 years after ultrasound-guided foam sclerotherapy for varicose veins. *Br J Surg* 2014;**101**:1098–104.
- 224 Lim SY, Tan JX, D’Cruz RT, Syn N, Chong TT, Tang TY. Catheter-directed foam sclerotherapy, an alternative to ultrasound-guided foam sclerotherapy for varicose vein treatment: a systematic review and meta-analysis. *Phlebology* 2020;**35**:369–83.
- 225 Dos Santos JB, Junior WC, Porta RM, Puggina J, da Silva DF, Puech-Leao P, et al. Catheter-directed foam sclerotherapy with tumescence of the great saphenous vein versus ultrasound-guided foam sclerotherapy: a randomized controlled trial. *Phlebology* 2020;**35**:84–91.
- 226 Wright D, Gobin JP, Bradbury AW, Coleridge-Smith P, Spoelstra H, Berridge D, et al. Varisolve polidocanol micro-foam compared with surgery or sclerotherapy in the management of varicose veins in the presence of trunk vein incompetence: European randomized controlled trial. *Phlebology* 2006;**21**:180–90.
- 227 Parsi K, Panozzo B, Bull A, Yang A, Kang M, Parsi Y, et al. Deep vein sclerosis following sclerotherapy: ultrasonic and d-dimer criteria. *Phlebology* 2020;**35**:325–36.
- 228 Lam YL, Toonder IM, Wittens CH. Clarivein(R) mechanochemical ablation an interim analysis of a randomized controlled trial dose-finding study. *Phlebology* 2016;**31**:170–6.
- 229 Holewijn S, van Eekeren R, Vahl A, de Vries J, Reijnen M, group Ms. Two-year results of a multicenter randomized controlled trial comparing Mechanochemical endovenous Ablation to RADIOfrequeNcy Ablation in the treatment of primary great saphenous vein incompetence (MARADONA trial). *J Vasc Surg Venous Lymphat Disord* 2019;**7**:364–74.
- 230 Mohamed AH, Leung C, Wallace T, Smith G, Carradice D, Chetter I. A Randomized controlled trial of endovenous laser ablation versus mechanochemical ablation with ClariVein in the management of superficial venous incompetence (LAMA Trial). *Ann Surg* 2021;**273**:e188–95.
- 231 Lane T, Bootun R, Dharmarajah B, Lim CS, Najem M, Renton S, et al. A multi-centre randomised controlled trial comparing radiofrequency and mechanical occlusion chemically assisted ablation of varicose veins - Final results of the Venefit versus Clarivein for varicose veins trial. *Phlebology* 2017;**32**:89–98.
- 232 Vähäaho S, Halmesmäki K, Mahmoud O, Albäck A, Noronen K, Venermo M. Three-year results of a randomized controlled trial comparing mechanochemical and thermal ablation in the treatment of insufficient great saphenous veins. *J Vasc Surg Venous Lymphat Disord* 2021;**9**:652–9.
- 233 Iłzecki M, Terlecki P, Przywara S, Iłzecka J, Zubilewicz T. The novel minimally invasive mechano-chemical technique of the saphenous vein ablation. Our center experience: results of 24 months follow-up. *Acta Angiol* 2019;**25**:127–32.
- 234 Gibson K, Minjarez R, Gunderson K, Ferris B. Need for adjunctive procedures following cyanoacrylate closure of incompetent great, small and accessory saphenous veins without the use of postprocedure compression: three-month data from a postmarket evaluation of the VenaSeal System (the WAVES Study). *Phlebology* 2019;**34**:231–7.
- 235 Rasmussen L, Lawaetz M, Bjoern L, Blemings A, Eklof B. Randomized clinical trial comparing endovenous laser ablation and stripping of the great saphenous vein with clinical and duplex outcome after 5 years. *J Vasc Surg* 2013;**58**:421–6.
- 236 Pan Y, Zhao J, Mei J, Shao M, Zhang J. Comparison of endovenous laser ablation and high ligation and stripping for varicose vein treatment: a meta-analysis. *Phlebology* 2014;**29**:109–19.
- 237 Carradice D, Mekako AI, Hatfield J, Chetter IC. Randomized clinical trial of concomitant or sequential phlebectomy after endovenous laser therapy for varicose veins. *Br J Surg* 2009;**96**: 369–75.
- 238 Olivencia JA. Complications of ambulatory phlebectomy: a review of 4000 consecutive cases. *Am J Cosmet Surg* 2000;**17**:161–5.
- 239 Tisi PV. Varicose veins. *BMJ Clin Evid* 2011;**2011**:0212.
- 240 Breu FX, Guggenbichler S, Wollmann JC. 2nd European Consensus Meeting on Foam Sclerotherapy 2006, Tegernsee, Germany. *Vasa* 2008;**37**(Suppl 71):1–29.

- 241 Reich-Schupke S, Weyer K, Altmeyer P, Stucker M. Treatment of varicose tributaries with sclerotherapy with polidocanol 0.5 % foam. *Vasa* 2010;**39**:169–74.
- 242 Zhang J, Jing Z, Schliephake DE, Otto J, Malouf GM, Gu YQ. Efficacy and safety of aethoxysklerol(R) (polidocanol) 0.5%, 1% and 3% in comparison with placebo solution for the treatment of varicose veins of the lower extremities in Chinese patients (ESA-China Study). *Phlebology* 2012;**27**:184–90.
- 243 Michaels JA, Campbell WB, Brazier JE, Macintyre JB, Palfreyman SJ, Ratcliffe J, et al. Randomised clinical trial, observational study and assessment of cost-effectiveness of the treatment of varicose veins (REACTIV trial). *Health Technol Assess* 2006;**10**:1–196, iii-iv.
- 244 Schul MW, Eaton T, Erdman B. Compression versus sclerotherapy for patients with isolated refluxing reticular veins and telangiectasia: a randomized trial comparing quality-of-life outcomes. *Phlebology* 2011;**26**:148–56.
- 245 de Roos KP, Nieman FH, Neumann HA. Ambulatory phlebectomy versus compression sclerotherapy: results of a randomized controlled trial. *Dermatol Surg* 2003;**29**:221–6.
- 246 van der Velden SK, Pichot O, van den Bos RR, Nijsten TE, De Maeseneer MG. Management strategies for patients with varicose veins (C2-C6): results of a worldwide survey. *Eur J Vasc Endovasc Surg* 2015;**49**:213–20.
- 247 Vasquez M, Gasparis AP. A multicenter, randomized, placebo-controlled trial of endovenous thermal ablation with or without polidocanol endovenous microfoam treatment in patients with great saphenous vein incompetence and visible varicosities. *Phlebology* 2017;**32**:272–81.
- 248 Luecke T, Brunkwall J. Meta-analysis of transilluminated powered phlebectomy for superficial varicosities. *J Cardiovasc Surg (Torino)* 2008;**49**:757–64.
- 249 Chetter IC, Mylankal KJ, Hughes H, Fitridge R. Randomized clinical trial comparing multiple stab incision phlebectomy and transilluminated powered phlebectomy for varicose veins. *Br J Surg* 2006;**93**:169–74.
- 250 Lin PH, Matos JM, Chen A, Kim W, Poi MJ, Jiang JS, et al. Treatment outcomes and lessons learned from transilluminated powered phlebectomy for varicose veins in 1034 patients. *Vasc Endovascular Surg* 2016;**50**:277–82.
- 251 Myers KA, Clough A, Tilli H. Endovenous laser ablation for major varicose tributaries. *Phlebology* 2013;**28**:180–3.
- 252 Wang JC, Li Y, Li GY, Xiao Y, Li WM, Ma Q, et al. A comparison of concomitant tributary laser ablation and foam sclerotherapy in patients undergoing truncal endovenous laser ablation for lower limb varicose veins. *J Vasc Interv Radiol* 2018;**29**:781–9.
- 253 Abdul-Haqq R, Almaroof B, Chen BL, Panneton JM, Parent FN. Endovenous laser ablation of great saphenous vein and perforator veins improves venous stasis ulcer healing. *Ann Vasc Surg* 2013;**27**:932–9.
- 254 van Gent W, Wittens C. Influence of perforating vein surgery in patients with venous ulceration. *Phlebology* 2015;**30**:127–32.
- 255 van Rij AM, Hill G, Gray C, Christie R, Macfarlane J, Thomson I. A prospective study of the fate of venous leg perforators after varicose vein surgery. *J Vasc Surg* 2005;**42**:1156–62.
- 256 Costa Almeida CE. Treatment of perforating veins - review of techniques. *Rev Port Surg* 2014;**31**:27–33.
- 257 Ozsvath K, Hager E, Harlander-Locke M, Masuda E, Elias S, Dillavou ED. Current techniques to treat pathologic perforator veins. *J Vasc Surg Venous Lymphat Disord* 2017;**5**:293–6.
- 258 Hager ES, Washington C, Steinmetz A, Wu T, Singh M, Dillavou E. Factors that influence perforator vein closure rates using radiofrequency ablation, laser ablation, or foam sclerotherapy. *J Vasc Surg Venous Lymphat Disord* 2016;**4**:51–6.
- 259 Tadros RO, Faries PL, Reynolds K, Png CY, Kim SY, Ting W. A novel technique for closure of the perforator vein using the ClariVein® Occlusion Catheter. *Ital J Vasc Endovasc Surg* 2016;**23**:68–75.
- 260 Prasad Bp K, Joy B, Toms A, Sleeba T. Treatment of incompetent perforators in recurrent venous insufficiency with adhesive embolization and sclerotherapy. *Phlebology* 2018;**33**:242–50.
- 261 Gibson K, Elias S, Adelman M, Hager ES, Dexter DJ, Vayuvegula S, et al. A prospective safety and effectiveness study using endovenous laser ablation with a 400- $\mu$ m optical fiber for the treatment of pathologic perforator veins in patients with advanced venous disease (SeCure trial). *J Vasc Surg Venous Lymphat Disord* 2020;**8**:805–13.
- 262 Lawrence PF, Alktaifi A, Rigberg D, DeRubertis B, Gelabert H, Jimenez JC. Endovenous ablation of incompetent perforating veins is effective treatment for recalcitrant venous ulcers. *J Vasc Surg* 2011;**54**:737–42.
- 263 Kiguchi MM, Hager ES, Winger DG, Hirsch SA, Chaer RA, Dillavou ED. Factors that influence perforator thrombosis and predict healing with perforator sclerotherapy for venous ulceration without axial reflux. *J Vasc Surg* 2014;**59**:1368–76.
- 264 Lin ZC, Loveland PM, Johnston RV, Bruce M, Weller CD. Subfascial endoscopic perforator surgery (SEPS) for treating venous leg ulcers. *Cochrane Database Syst Rev* 2019;**3**:CD012164.
- 265 Ruckley CV, Allan PL, Evans CJ, Lee AJ, Fowkes FG. Telangiectasia and venous reflux in the Edinburgh Vein Study. *Phlebology* 2012;**27**:297–302.
- 266 Rabe E, Schliephake D, Otto J, Breu FX, Pannier F. Sclerotherapy of telangiectases and reticular veins: a double-blind, randomized, comparative clinical trial of polidocanol, sodium tetradecyl sulphate and isotonic saline (EASI study). *Phlebology* 2010;**25**:124–31.
- 267 Schwartz L, Maxwell H. Sclerotherapy for lower limb telangiectasias. *Cochrane Database Syst Rev* 2011;**12**:CD008826.
- 268 Ianoi G, Ianoi S, Calbureanu-Popescu MX, Tutunaru C, Calina D, Neagoe D. Comparative study in leg telangiectasias treatment with Nd:YAG laser and sclerotherapy. *Exp Ther Med* 2019;**17**:1106–12.
- 269 Bertanha M, Jaldin RG, Moura R, Pimenta REF, Mariuba JVO, Lucio Filho CEP, et al. Sclerotherapy for reticular veins in the lower limbs: a triple-blind randomized clinical trial. *JAMA Dermatol* 2017;**153**:1249–55.
- 270 Bertanha M, Yoshida WB, Bueno de Camargo PA, Moura R, Reis de Paula D, Padovani CR, et al. Polidocanol plus glucose versus glucose alone for the treatment of telangiectasias: triple blind, randomised controlled trial (PG3T). *Eur J Vasc Endovasc Surg* 2021;**61**:128–35.
- 271 Munia MA, Wolosker N, Munia CG, Chao WS, Puech-Leao P. Comparison of laser versus sclerotherapy in the treatment of lower extremity telangiectasias: a prospective study. *Dermatol Surg* 2012;**38**:635–9.
- 272 Parlar B, Blazek C, Cazzaniga S, Naldi L, Kloetgen HW, Borradori L, et al. Treatment of lower extremity telangiectasias in women by foam sclerotherapy vs. Nd:YAG laser: a prospective, comparative, randomized, open-label trial. *J Eur Acad Dermatol Venereol* 2015;**29**:549–54.
- 273 Meesters AA, Pitassi LH, Campos V, Wolkerstorfer A, Dierickx CC. Transcutaneous laser treatment of leg veins. *Lasers Med Sci* 2014;**29**:481–92.
- 274 Adamic M, Pavlovic MD, Troilius Rubin A, Palmetun-Ekback M, Boixeda P. Guidelines of care for vascular lasers and intense pulse light sources from the European Society for Laser Dermatology. *J Eur Acad Dermatol Venereol* 2015;**29**:1661–78.
- 275 Ozden MG, Bahcivan M, Aydin F, Senturk N, Bek Y, Canturk T, et al. Clinical comparison of potassium-titanyl-phosphate (KTP) versus neodymium:YAG (Nd:YAG) laser treatment for lower extremity telangiectasias. *J Dermatolog Treat* 2011;**22**:162–6.
- 276 Bernstein EF, Noyaner-Turley A, Renton B. Treatment of spider veins of the lower extremity with a novel 532 nm KTP laser. *Lasers Surg Med* 2014;**46**:81–8.
- 277 Chen JZ, Alexiades-Armenakas MR, Bernstein LJ, Jacobson LG, Friedman PM, Geronemus RG. Two randomized, double-blind,

- placebo-controlled studies evaluating the S-Caine Peel for induction of local anesthesia before long-pulsed Nd:YAG laser therapy for leg veins. *Dermatol Surg* 2003;**29**:1012–8.
- 278 Klein A, Buschmann M, Babilas P, Landthaler M, Baumler W. Indocyanine green-augmented diode laser therapy vs. long-pulsed Nd:YAG (1064 nm) laser treatment of telangiectatic leg veins: a randomized controlled trial. *Br J Dermatol* 2013;**169**:365–73.
- 279 Klein A, Baumler W, Koller M, Shafirstein G, Kohl EA, Landthaler M, et al. Indocyanine green-augmented diode laser therapy of telangiectatic leg veins: a randomized controlled proof-of-concept trial. *Lasers Surg Med* 2012;**44**:369–76.
- 280 Moreno-Moraga J, Smarandache A, Pascu ML, Royo J, Trelles MA. 1064 nm Nd:YAG long pulse laser after polidocanol microfoam injection dramatically improves the result of leg vein treatment: a randomized controlled trial on 517 legs with a three-year follow-up. *Phlebology* 2014;**29**:658–66.
- 281 Miyake RK, Ramacciotti E. Cryo-laser and cryosclerotherapy guided by augmented reality for telangiectasias, feeder, and small varicose vein treatment – The CLaCS technique white paper report. *J Phlebolymphol* 2019;**12**:1–7.
- 282 Stacey D, Legare F, Col NF, Bennett CL, Barry MJ, Eden KB, et al. Decision aids for people facing health treatment or screening decisions. *Cochrane Database Syst Rev* 2014;**1**:CD001431.
- 283 Santema TB, Stubenrouch FE, Koelemay MJ, Vahl AC, Vermeulen CF, Visser MJ, et al. Shared decision making in vascular surgery: an exploratory study. *Eur J Vasc Endovasc Surg* 2016;**51**:587–93.
- 284 Hassanin A, Aherne TM, Greene G, Boyle E, Egan B, Tierney S, et al. A systematic review and meta-analysis of comparative studies comparing nonthermal versus thermal endovenous ablation in superficial venous incompetence. *J Vasc Surg Venous Lymphat Disord* 2019;**7**:902–13.
- 285 Epstein D, Onida S, Bootun R, Ortega-Ortega M, Davies AH. Cost-effectiveness of current and emerging treatments of varicose veins. *Value Health* 2018;**21**:911–20.
- 286 Cabrero Fernandez M, Martinez Lopez I, Hernandez Mateo MM, Marques de Marino P, Cernuda Artero I, Serrano Hernando FJ. Prospective study of safety and effectiveness in the use of radiofrequency ablation for incompetent great saphenous vein  $\geq 12$  mm. *J Vasc Surg Venous Lymphat Disord* 2017;**5**:810–6.
- 287 Lin JC, Iafrazi MD, O'Donnell Jr TF, Estes JM, Mackey WC. Correlation of duplex ultrasound scanning-derived valve closure time and clinical classification in patients with small saphenous vein reflux: is lesser saphenous vein truly lesser? *J Vasc Surg* 2004;**39**:1053–8.
- 288 Boersma D, Kornmann VN, van Eekeren RR, Tromp E, Unlu C, Reijnen MM, et al. Treatment modalities for small saphenous vein insufficiency: systematic review and meta-analysis. *J Endovasc Ther* 2016;**23**:199–211.
- 289 Samuel N, Carradice D, Wallace T, Mekako A, Hatfield J, Chetter I. Randomized clinical trial of endovenous laser ablation versus conventional surgery for small saphenous varicose veins. *Ann Surg* 2013;**257**:419–26.
- 290 Brittenden J, Cotton SC, Elders A, Ramsay CR, Norrie J, Burr J, et al. A randomized trial comparing treatments for varicose veins. *N Engl J Med* 2014;**371**:1218–27.
- 291 Nandhra S, El-sheikha J, Carradice D, Wallace T, Souroullas P, Samuel N, et al. A randomized clinical trial of endovenous laser ablation versus conventional surgery for small saphenous varicose veins. *J Vasc Surg* 2015;**61**:741–6.
- 292 Rooram AD, Lind MY, Van Brussel JP, Terlouw-Punt LC, Birnie E, De Smet AA, et al. Endovenous laser ablation versus conventional surgery in the treatment of small saphenous vein incompetence. *J Vasc Surg Venous Lymphat Disord* 2013;**1**:357–63.
- 293 Paravastu SC, Horne M, Dodd PD. Endovenous ablation therapy (laser or radiofrequency) or foam sclerotherapy versus conventional surgical repair for short saphenous varicose veins. *Cochrane Database Syst Rev* 2016;**11**:CD010878.
- 294 Rodriguez-Acevedo O, Elstner KE, Martinic K, Zea A, Diaz J, Martins RT, et al. Hydrodisplacement of sural nerve for safety and efficacy of endovenous thermal ablation for small saphenous vein incompetence. *Phlebology* 2017;**32**:482–7.
- 295 Garcia-Gimeno M, Rodriguez-Camarero S, Tagarro-Villalba S, Ramalle-Gomara E, Gonzalez-Gonzalez E, Arranz MA, et al. Duplex mapping of 2036 primary varicose veins. *J Vasc Surg* 2009;**49**:681–9.
- 296 Schul MW, Schloerke B, Gomes GM. The refluxing anterior accessory saphenous vein demonstrates similar clinical severity when compared to the refluxing great saphenous vein. *Phlebology* 2016;**31**:654–9.
- 297 Proebstle TM, Mohler T. A longitudinal single-center cohort study on the prevalence and risk of accessory saphenous vein reflux after radiofrequency segmental thermal ablation of great saphenous veins. *J Vasc Surg Venous Lymphat Disord* 2015;**3**:265–9.
- 298 Anwar MA, Idrees M, Aswini M, Theivacumar NS. Fate of the tributaries of sapheno femoral junction following endovenous thermal ablation of incompetent axial vein - a review article. *Phlebology* 2019;**34**:151–5.
- 299 Gibson K, Khilnani N, Schul M, Meissner M, American College of Phlebology Guidelines Committee. American College of Phlebology Guidelines - Treatment of refluxing accessory saphenous veins. *Phlebology* 2017;**32**:448–52.
- 300 Prinz N, Selzle K, Kamionek I, Sagoo KS, Leberig A, Kaiser R, et al. Surgery of the lateral accessory saphenous vein. *Zentralbl Chir* 2001;**126**:526–7.
- 301 De Maeseneer M. What a phlebologist should know about the anterior accessory saphenous vein? *Phlebology* 2019;**26**:66–71.
- 302 Theivacumar NS, Darwood RJ, Gough MJ. Endovenous laser ablation (EVLA) of the anterior accessory great saphenous vein (AAGSV): abolition of sapheno-femoral reflux with preservation of the great saphenous vein. *Eur J Vasc Endovasc Surg* 2009;**37**:477–81.
- 303 King T, Coulomb G, Goldman A, Sheen V, McWilliams S, Gupta RC. Experience with concomitant ultrasound-guided foam sclerotherapy and endovenous laser treatment in chronic venous disorder and its influence on health related quality of life: interim analysis of more than 1000 consecutive procedures. *Int Angiol* 2009;**28**:289–97.
- 304 Bradbury AW, Bate G, Pang K, Darvall KA, Adam DJ. Ultrasound-guided foam sclerotherapy is a safe and clinically effective treatment for superficial venous reflux. *J Vasc Surg* 2010;**52**:939–45.
- 305 Maldonado-Fernandez N, Linares-Palomino JP, Lopez-Espada C, Martinez-Gamez FJ, Ros-Die E. Clinical results of a new strategy (modified CHIVA) for surgical treatment of anterior accessory great saphenous varicose veins. *Cir Esp* 2016;**94**:144–50.
- 306 Lane TR, Kelleher D, Shepherd AC, Franklin IJ, Davies AH. Ambulatory varicosity avulsion later or synchronized (AVULS): a randomized clinical trial. *Ann Surg* 2015;**261**:654–61.
- 307 Mohamed A, Leung C, Hitchman L, Wallace T, Smith G, Carradice D, et al. A prospective observational cohort study of concomitant versus sequential phlebectomy for tributary varicosities following axial mechanochemical ablation. *Phlebology* 2019;**34**:627–35.
- 308 Blomgren L. Residual incompetent tributaries after varicose vein surgery increased the need for reintervention after 8 years. *J Vasc Surg Venous Lymphat Disord* 2020;**8**:378–82.
- 309 Aherne TM, Ryan EJ, Boland MR, McKeivitt K, Hassanin A, Tubassam M, et al. Concomitant vs. staged treatment of varicose tributaries as an adjunct to endovenous ablation: a systematic review and meta-analysis. *Eur J Vasc Endovasc Surg* 2020;**60**:430–42.



- 310 El-Sheikha J, Nandhra S, Carradice D, Wallace T, Samuel N, Smith GE, et al. Clinical outcomes and quality of life 5 years after a randomized trial of concomitant or sequential phlebectomy following endovenous laser ablation for varicose veins. *Br J Surg* 2014;**101**:1093–7.
- 311 Watanabe S, Nishio S, Tsuji T, Fujita S, Kyo E. Effect of trans-luminal injection of foam sclerotherapy combined with endovenous thermal ablation of varicose veins. *EJVES Vasc Forum* 2020;**47**:83–6.
- 312 Guzelmansur I, Oguzkurt L, Koca N, Andic C, Gedikoglu M, Ozkan U. Endovenous laser ablation and sclerotherapy for incompetent vein of Giacomini. *Phlebology* 2014;**29**:511–6.
- 313 Yuce I, Oguzkurt L, Eren S, Levent A, Kantarci M, Yalcin A, et al. Assessment of posterior accessory great saphenous vein of the leg using ultrasonography: a preliminary study. *Surg Radiol Anat* 2016;**38**:123–6.
- 314 Biemans AA, van den Bos RR, Hollestein LM, Maessen-Visch MB, Vergouwe Y, Neumann HA, et al. The effect of single phlebectomies of a large varicose tributary on great saphenous vein reflux. *J Vasc Surg Venous Lymphat Disord* 2014;**2**:179–87.
- 315 Kim HK, Kim HJ, Shim JH, Baek MJ, Sohn YS, Choi YH. Endovenous laser versus ambulatory phlebectomy of varicose tributaries in conjunction with endovenous laser treatment of the great or small saphenous vein. *Ann Vasc Surg* 2009;**23**:207–11.
- 316 Recek C. Competent and incompetent calf perforators in primary varicose veins: a resistant myth. *Phlebology* 2016;**31**:532–40.
- 317 Stuart WP, Adam DJ, Allan PL, Ruckley CV, Bradbury AW. Saphenous surgery does not correct perforator incompetence in the presence of deep venous reflux. *J Vasc Surg* 1998;**28**:834–8.
- 318 Gloviczki P, Comerota AJ, Dalsing MC, Eklof BG, Gillespie DL, Gloviczki ML, et al. The care of patients with varicose veins and associated chronic venous diseases: clinical practice guidelines of the Society for Vascular Surgery and the American Venous Forum. *J Vasc Surg* 2011;**53**(5 Suppl):2S–48S.
- 319 van Gent WB, Hop WC, van Praag MC, Mackaay AJ, de Boer EM, Wittens CH. Conservative versus surgical treatment of venous leg ulcers: a prospective, randomized, multicenter trial. *J Vasc Surg* 2006;**44**:563–71.
- 320 Reitz KM, Salem K, Mohapatra A, Liang NL, Avgerinos ED, Singh MJ, et al. Complete venous ulceration healing after perforator ablation does not depend on treatment modality. *Ann Vasc Surg* 2021;**70**:109–15.
- 321 Franceschi C. *La cure Conservatrice et Hémodynamique de l'Insuffisance Veineuse en Ambulatoire CHIVA*. Precy-sous-Thil, France: Editions de L'Armançon; 1988.
- 322 Bellmunt-Montoya S, Escribano JM, Pantoja Bustillos PE, Tello-Díaz C, Martínez-Zapata MJ. CHIVA method for the treatment of chronic venous insufficiency. *Cochrane Database Syst Rev* 2021;**9**:CD009648.
- 323 Milone M, Salvatore G, Maietta P, Sosa Fernandez LM, Milone F. Recurrent varicose veins of the lower limbs after surgery. Role of surgical technique (stripping vs. CHIVA) and surgeon's experience. *G Chir* 2011;**32**:460–3.
- 324 Pittaluga P, Rea B, Barbe R. Méthode ASVA (ablation selective des varices sous anesthésie locale): Principes et résultats préliminaires. *Phlébologie* 2005;**58**:175–81.
- 325 Pittaluga P, Chastanet S, Rea B, Barbe R. Midterm results of the surgical treatment of varices by phlebectomy with conservation of a refluxing saphenous vein. *J Vasc Surg* 2009;**50**:107–18.
- 326 Richards T, Anwar M, Beshr M, Davies AH, Onida S. Systematic review of ambulatory selective variceal ablation under local anesthetic technique for the treatment of symptomatic varicose veins. *J Vasc Surg Venous Lymphat Disord* 2021;**9**:525–35.
- 327 Dabbs EB, Mainsiow LE, Holdstock JM, Price BA, Whiteley MS. A description of the 'smile sign' and multi-pass technique for endovenous laser ablation of large diameter great saphenous veins. *Phlebology* 2018;**33**:534–9.
- 328 Woo HY, Kim SM, Kim D, Chung JK, Jung IM. Outcome of ClosureFAST radiofrequency ablation for large-diameter incompetent great saphenous vein. *Ann Surg Treat Res* 2019;**96**:313–8.
- 329 Labropoulos N, Kokkosis AA, Spentzouris G, Gasparis AP, Tassiopoulos AK. The distribution and significance of varicosities in the saphenous trunks. *J Vasc Surg* 2010;**51**:96–103.
- 330 Hamann SAS, van der Velden SK, De Maeseneer MGR. Safety and effectiveness of endovenous thermal ablation for incompetent saphenous veins with an aneurysm close to the junction. *Eur J Vasc Endovasc Surg* 2019;**58**:244–8.
- 331 Albernaz LF, Albernaz DTS, Zignani FRM, Chi YW. Treatment of foot varicose veins: A study of 119 consecutive patients. *Phlebology* 2018;**33**:267–72.
- 332 De Roos KP, Neumann HA. Muller's ambulatory phlebectomy for varicose veins of the foot. *Dermatol Surg* 1998;**24**:465–70.
- 333 Jung SC, Lee W, Chung JW, Jae HJ, Park EA, Jin KN, et al. Unusual causes of varicose veins in the lower extremities: CT venographic and Doppler US findings. *Radiographics* 2009;**29**:525–36.
- 334 Ramelet AA, Crebassa V, Alotto CA, Buero G, Gillet JL, Grenot-Mercier A, et al. Anomalous intraosseous venous drainage: Bone perforators? *Phlebology* 2017;**32**:241–8.
- 335 Perrin MR, Labropoulos N, Leon Jr LR. Presentation of the patient with recurrent varices after surgery (REVAS). *J Vasc Surg* 2006;**43**:327–34.
- 336 Versteeg MP, Macfarlane J, Hill GB, van Rij AM. The natural history of ultrasound-detected recurrence in the groin following saphenofemoral treatment for varicose veins. *J Vasc Surg Venous Lymphat Disord* 2016;**4**:293–300.
- 337 De Maeseneer MG, Vandenbroeck CP, Hendriks JM, Lauwers PR, Van Schil PE. Accuracy of duplex evaluation one year after varicose vein surgery to predict recurrence at the saphenofemoral junction after five years. *Eur J Vasc Endovasc Surg* 2005;**29**:308–12.
- 338 van Rij AM, Jones GT, Hill GB, Jiang P. Neovascularization and recurrent varicose veins: more histologic and ultrasound evidence. *J Vasc Surg* 2004;**40**:296–302.
- 339 Dabbs EB, Dos Santos SJ, Shiangoli I, Holdstock JM, Beckett D, Whiteley MS. Pelvic venous reflux in males with varicose veins and recurrent varicose veins. *Phlebology* 2018;**33**:382–7.
- 340 Ganesini S, Occhionorelli S, Menegatti E, Malagoni AM, Tessari M, Zamboni P. Femoral vein valve incompetence as a risk factor for junctional recurrence. *Phlebology* 2018;**33**:206–12.
- 341 Baccellieri D, Ardita V, Carta N, Melissano G, Chiesa R. Anterior accessory saphenous vein confluence anatomy at the saphenofemoral junction as risk factor for varicose veins recurrence after great saphenous vein radiofrequency thermal ablation. *Int Angiol* 2020;**39**:105–11.
- 342 Frings N, Nelle A, Tran P, Fischer R, Krug W. Reduction of neoreflux after correctly performed ligation of the saphenofemoral junction. A randomized trial. *Eur J Vasc Endovasc Surg* 2004;**28**:246–52.
- 343 van Rij AM, Jones GT, Hill BG, Amer M, Thomson IA, Pettigrew RA, et al. Mechanical inhibition of angiogenesis at the saphenofemoral junction in the surgical treatment of varicose veins: early results of a blinded randomized controlled trial. *Circulation* 2008;**118**:66–74.
- 344 De Maeseneer MG, Philipsen TE, Vandenbroeck CP, Lauwers PR, Hendriks JM, De Hert SG, et al. Closure of the cribriform fascia: an efficient anatomical barrier against postoperative neovascularisation at the saphenofemoral junction? A prospective study. *Eur J Vasc Endovasc Surg* 2007;**34**:361–6.
- 345 Theivacumar NS, Dellagrammaticas D, Mavor AI, Gough MJ. Endovenous laser ablation: does standard above-knee great saphenous vein ablation provide optimum results in patients with both above- and below-knee reflux? A randomized controlled trial. *J Vasc Surg* 2008;**48**:173–8.



- 346 De Maeseneer M. Surgery for recurrent varicose veins: toward a less-invasive approach? *Perspect Vasc Surg Endovasc Ther* 2011;23:244–9.
- 347 Flamand MK, Baekgaard N. Room for improvement in reoperation for varicosities of the small saphenous vein. *Dan Med Bull* 2011;58:A4239.
- 348 van Groenendaal L, Flinkenflugel L, van der Vliet JA, Roovers EA, van Sterkenburg SM, Reijnen MM. Conventional surgery and endovenous laser ablation of recurrent varicose veins of the small saphenous vein: a retrospective clinical comparison and assessment of patient satisfaction. *Phlebology* 2010;25:151–7.
- 349 van Groenendaal L, van der Vliet JA, Flinkenflugel L, Roovers EA, van Sterkenburg SM, Reijnen MM. Treatment of recurrent varicose veins of the great saphenous vein by conventional surgery and endovenous laser ablation. *J Vasc Surg* 2009;50:1106–13.
- 350 Nwaèjike N, Srodon PD, Kyriakides C. Endovenous laser ablation for the treatment of recurrent varicose vein disease—a single centre experience. *Int J Surg* 2010;8:299–301.
- 351 Hinchliffe RJ, Ubhi J, Beech A, Ellison J, Braithwaite BD. A prospective randomised controlled trial of VNUS closure versus surgery for the treatment of recurrent long saphenous varicose veins. *Eur J Vasc Endovasc Surg* 2006;31:212–8.
- 352 Theivacumar NS, Gough MJ. Endovenous laser ablation (EVLA) to treat recurrent varicose veins. *Eur J Vasc Endovasc Surg* 2011;41:691–6.
- 353 Pavei P, Ferrini M, Spreafico G, Nosadini A, Piccioli A, Giraldi E, et al. Ultrasound guided foam sclerotherapy of recurrent varices of the great and small saphenous vein: 5-year follow up. *Veins Lymphat* 2014;3:4655.
- 354 Darvall KA, Bate GR, Adam DJ, Silverman SH, Bradbury AW. Duplex ultrasound outcomes following ultrasound-guided foam sclerotherapy of symptomatic recurrent great saphenous varicose veins. *Eur J Vasc Endovasc Surg* 2011;42:107–14.
- 355 Williams ZF, Dillavou ED. A systematic review of venous stents for iliac and venacaval occlusive disease. *J Vasc Surg Venous Lymphat Disord* 2020;8:145–53.
- 356 Rossi FH, Kambara AM, Izukawa NM, Rodrigues TO, Rossi CB, Sousa AG, et al. Randomized double-blinded study comparing medical treatment versus iliac vein stenting in chronic venous disease. *J Vasc Surg Venous Lymphat Disord* 2018;6:183–91.
- 357 Esposito A, Charisis N, Kantarovsky A, Uhl JF, Labropoulos N. A comprehensive review of the pathophysiology and clinical importance of iliac vein obstruction. *Eur J Vasc Endovasc Surg* 2020;60:118–25.
- 358 Kahn SR, Comerota AJ, Cushman M, Evans NS, Ginsberg JS, Goldenberg NA, et al. The postthrombotic syndrome: evidence-based prevention, diagnosis, and treatment strategies: a scientific statement from the American Heart Association. *Circulation* 2014;130:1636–61.
- 359 Yin M, Shi H, Ye K, Lu X, Li W, Huang X, et al. Clinical assessment of endovascular stenting compared with compression therapy alone in post-thrombotic patients with iliofemoral obstruction. *Eur J Vasc Endovasc Surg* 2015;50:101–7.
- 360 Blanch Alerany M, Izquierdo Lamoca LM, Ramirez Ortega M, Lago Rivas I, Zotta Desboeufs R, Stefanov Kiuri S. Endovascular treatment of iliofemoral chronic post-thrombotic venous flow obstruction. *J Vasc Surg Venous Lymphat Disord* 2014;2:2–7.
- 361 de Wolf FMA, Arnoldussen CW, Grommes J, Hsien SG, Nelemans PJ, de Haan MW, et al. Minimally invasive treatment of chronic iliofemoral venous occlusive disease. *J Vasc Surg Venous Lymphat Disord* 2013;1:146–53.
- 362 Rosfors S, Blomgren L. Venous occlusion plethysmography in patients with post-thrombotic venous claudication. *J Vasc Surg* 2013;58:722–6.
- 363 Kurstjens RL, Catarinella FS, Lam YL, de Wolf MA, Toonder IM, Wittens CH. The inability of venous occlusion air plethysmography to identify patients who will benefit from stenting of deep venous obstruction. *Phlebology* 2018;33:483–91.
- 364 Lattimer CR, Mendoza E, Kalodiki E. The current status of air-plethysmography in evaluating non-thrombotic iliac vein lesions. *Phlebology* 2018;33:3–4.
- 365 Neglen P, Hollis KC, Olivier J, Raju S. Stenting of the venous outflow in chronic venous disease: long-term stent-related outcome, clinical, and hemodynamic result. *J Vasc Surg* 2007;46:979–90.
- 366 van Vuuren T, Wittens C, de Graaf R. Stent extension below the common femoral vein in extensive chronic iliofemoral venous obstructions. *J Vasc Interv Radiol* 2018;29:1142–7.
- 367 Black SA, Alvi A, Baker SJ, Beckett D, Breen K, Burfitt NJ, et al. Management of acute and chronic iliofemoral venous outflow obstruction: a multidisciplinary team consensus. *Int Angiol* 2020;39:3–16.
- 368 Sebastian T, Barco S, Engelberger RP, Spirk D, Schindewolf M, Baumann F, et al. Duplex ultrasound investigation for the detection of obstructed ilioacaval venous stents. *Eur J Vasc Endovasc Surg* 2020;60:443–50.
- 369 Seager MJ, Busuttill A, Dharmarajah B, Davies AH. Editor's Choice—A systematic review of endovenous stenting in chronic venous disease secondary to iliac vein obstruction. *Eur J Vasc Endovasc Surg* 2016;51:100–20.
- 370 Qiu P, Zha B, Xu A, Wang W, Zhan Y, Zhu X, et al. Systematic review and meta-analysis of iliofemoral stenting for post-thrombotic syndrome. *Eur J Vasc Endovasc Surg* 2019;57:407–16.
- 371 Black S, Gwozdz A, Karunanithy N, Silickas J, Breen K, Hunt B, et al. Two year outcome after chronic iliac vein occlusion recanalisation using the Vici Venous stent(R). *Eur J Vasc Endovasc Surg* 2018;56:710–8.
- 372 Palma EC, Esperon R. Vein transplants and grafts in the surgical treatment of the postphlebotic syndrome. *J Cardiovasc Surg (Torino)* 1960;1:94–107.
- 373 Eklof BG, Kistner RL, Masuda EM. Venous bypass and valve reconstruction: long-term efficacy. *Vasc Med* 1998;3:157–64.
- 374 Jost CJ, Gloviczki P, Cherry Jr KJ, McKusick MA, Harmsen WS, Jenkins GD, et al. Surgical reconstruction of iliofemoral veins and the inferior vena cava for nonmalignant occlusive disease. *J Vasc Surg* 2001;33:320–8.
- 375 Plate G, Hollier LH, Gloviczki P, Dewanjee MK, Kaye MP. Overcoming failure of venous vascular prostheses. *Surgery* 1984;96:503–10.
- 376 Menawat SS, Gloviczki P, Mozes G, Whitley D, Anding WJ, Serry RD. Effect of a femoral arteriovenous fistula on lower extremity venous hemodynamics after femorocaval reconstruction. *J Vasc Surg* 1996;24:793–9.
- 377 Puggioni A, Kistner RL, Eklof B, Lurie F. Surgical disobliteration of postthrombotic deep veins—endophlebectomy—is feasible. *J Vasc Surg* 2004;39:1048–52.
- 378 Vogel D, Comerota AJ, Al-Jabouri M, Assi ZI. Common femoral endovenectomy with ilioacaval endoluminal recanalization improves symptoms and quality of life in patients with post-thrombotic iliofemoral obstruction. *J Vasc Surg* 2012;55:129–35.
- 379 Garg N, Gloviczki P, Karimi KM, Duncan AA, Bjarnason H, Kalra M, et al. Factors affecting outcome of open and hybrid reconstructions for nonmalignant obstruction of iliofemoral veins and inferior vena cava. *J Vasc Surg* 2011;53:383–93.
- 380 Comerota AJ, Grewal NK, Thakur S, Assi Z. Endovenectomy of the common femoral vein and intraoperative iliac vein recanalization for chronic iliofemoral venous occlusion. *J Vasc Surg* 2010;52:243–7.
- 381 Grommes J, Gombert A, Barbati ME, von Trotha KT, Schleimer K, Jalaie H. Deep veins: hybrid procedure for treatment of iliofemoral obstruction. *Zentralbl Chir* 2017;142:487–91.
- 382 Dumantepe M, Aydin S, Okten M, Karabulut H. Endophlebectomy of the common femoral vein and endovascular iliac vein recanalization for chronic iliofemoral venous occlusion. *J Vasc Surg Venous Lymphat Disord* 2020;8:572–82.
- 383 O'Donnell Jr TF, Passman MA, Marston WA, Ennis WJ, Dalsing M, Kistner RL, et al. Management of venous leg ulcers: clinical practice

- guidelines of the Society for Vascular Surgery and the American Venous Forum. *J Vasc Surg* 2014;**60**(2 Suppl):3S–59S.
- 384 Ye K, Shi H, Yin M, Qin J, Yang X, Liu X, et al. Treatment of femoral vein obstruction concomitant with iliofemoral stenting in patients with severe post-thrombotic syndrome. *Eur J Vasc Endovasc Surg* 2018;**55**:222–8.
- 385 Neglen P. Stenting is the "Method-of-Choice" to treat iliofemoral venous outflow obstruction. *J Endovasc Ther* 2009;**16**:492–3.
- 386 Garcia MJ, Sterling KM, Kahn SR, Comerota AJ, Jaff MR, Ouriel K, et al. Ultrasound-accelerated thrombolysis and venoplasty for the treatment of the postthrombotic syndrome: results of the ACCESS PTS study. *J Am Heart Assoc* 2020;**9**:e013398.
- 387 Shaydakov E, Poremskaya O, Geroulakos G. The May-Husni procedure: a reappraisal. *Eur J Vasc Endovasc Surg* 2015;**50**:513–7.
- 388 Coleman DM, Rectenwald JE, Vandy FC, Wakefield TW. Contemporary results after sapheno-popliteal bypass for chronic femoral vein occlusion. *J Vasc Surg Venous Lymphat Disord* 2013;**1**:45–51.
- 389 Zhang X, Huang J, Peng Z, Lu X, Yang X, Ye K. Comparing safety and efficacy of rivaroxaban with warfarin for patients after successful stent placement for chronic iliofemoral occlusion: a retrospective single institution study. *Eur J Vasc Endovasc Surg* 2021;**61**:484–9.
- 390 Milinis K, Thapar A, Shalhoub J, Davies AH. Antithrombotic therapy following venous stenting: International Delphi Consensus. *Eur J Vasc Endovasc Surg* 2018;**55**:537–44.
- 391 Duarte-Gamas L, Rocha-Neves JP, Pereira-Neves A, Dias-Neto M, Baekgaard N. Contralateral deep vein thrombosis after stenting across the ilioacaval confluence in chronic venous disease - a systematic review. *Phlebology* 2020;**35**:221–30.
- 392 Lim KH, Hill G, Tarr G, van Rij A. Deep venous reflux definitions and associated clinical and physiological significance. *J Vasc Surg Venous Lymphat Disord* 2013;**1**:325–32.
- 393 Maleti O, Perrin M. Reconstructive surgery for deep vein reflux in the lower limbs: techniques, results and indications. *Eur J Vasc Endovasc Surg* 2011;**41**:837–48.
- 394 Goel RR, Abidia A, Hardy SC. Surgery for deep venous incompetence. *Cochrane Database Syst Rev* 2015;**2**:CD001097.
- 395 Adam DJ, Bello M, Hartshorne T, London NJ. Role of superficial venous surgery in patients with combined superficial and segmental deep venous reflux. *Eur J Vasc Endovasc Surg* 2003;**25**:469–72.
- 396 Knipp BS, Blackburn SA, Bloom JR, Fellows E, Laforge W, Pfeifer JR, et al. Endovenous laser ablation: venous outcomes and thrombotic complications are independent of the presence of deep venous insufficiency. *J Vasc Surg* 2008;**48**:1538–45.
- 397 Marston WA, Brabham VW, Mendes R, Berndt D, Weiner M, Keagy B. The importance of deep venous reflux velocity as a determinant of outcome in patients with combined superficial and deep venous reflux treated with endovenous saphenous ablation. *J Vasc Surg* 2008;**48**:400–6.
- 398 De Maeseneer MGR. Tips and tricks for treatment of varicose veins in post-thrombotic syndrome. In: Allegra C, Antignani PL, Kalodiki E, editors. *Tips and Tricks in Angiology*. Turin: Edizioni Minerva Medica; 2016. p. 179–83.
- 399 Noppeney T, Kopp R, Pfister K, Schierling W, Noppeney J, Cucuruz B. Treatment of popliteal vein aneurysms. *J Vasc Surg Venous Lymphat Disord* 2019;**7**:535–42.
- 400 Bergqvist D, Bjorck M, Ljungman C. Popliteal venous aneurysm—a systematic review. *World J Surg* 2006;**30**:273–9.
- 401 Sessa C, Nicolini P, Perrin M, Farah I, Magne JL, Guidicelli H. Management of symptomatic and asymptomatic popliteal venous aneurysms: a retrospective analysis of 25 patients and review of the literature. *J Vasc Surg* 2000;**32**:902–12.
- 402 Sinha S, Houghton J, Holt PJ, Thompson MM, Loftus IM, Hinchliffe RJ. Popliteal entrapment syndrome. *J Vasc Surg* 2012;**55**:252–62.
- 403 Menon D, Onida S, Davies AH. Overview of venous pathology related to repetitive vascular trauma in athletes. *J Vasc Surg Venous Lymphat Disord* 2019;**7**:756–62.
- 404 Dijkstra ML, Khin NY, Thomas SD, Lane RJ. Popliteal vein compression syndrome pathophysiology and correlation with popliteal compartment pressures. *J Vasc Surg Venous Lymphat Disord* 2013;**1**:181–6.
- 405 Raju S, Kirk OK, Jones TL. Endovenous management of venous leg ulcers. *J Vasc Surg Venous Lymphat Disord* 2013;**1**:165–72.
- 406 Raju S, Fredericks RK, Neglen PN, Bass JD. Durability of venous valve reconstruction techniques for "primary" and post-thrombotic reflux. *J Vasc Surg* 1996;**23**:357–67.
- 407 Posnett J, Gottrup F, Lundgren H, Saal G. The resource impact of wounds on health-care providers in Europe. *J Wound Care* 2009;**18**:154–61.
- 408 Harrison MB, Graham ID, Friedberg E, Lorimer K, Vandeveld-Coke S. Regional planning study. Assessing the population with leg and foot ulcers. *Can Nurse* 2001;**97**:18–23.
- 409 McDaniel HB, Marston WA, Farber MA, Mendes RR, Owens LV, Young ML, et al. Recurrence of chronic venous ulcers on the basis of clinical, etiologic, anatomic, and pathophysiologic criteria and air plethysmography. *J Vasc Surg* 2002;**35**:723–8.
- 410 Finlayson K, Wu ML, Edwards HE. Identifying risk factors and protective factors for venous leg ulcer recurrence using a theoretical approach: a longitudinal study. *Int J Nurs Stud* 2015;**52**:1042–51.
- 411 Franks PJ, Barker J, Collier M, Gethin G, Haesler E, Jawien A, et al. Management of patients with venous leg ulcers: challenges and current best practice. *J Wound Care* 2016;**25**(Suppl 6):S1–67.
- 412 Kim PJ, Evans KK, Steinberg JS, Pollard ME, Attinger CE. Critical elements to building an effective wound care center. *J Vasc Surg* 2013;**57**:1703–9.
- 413 Schultz GS, Sibbald RG, Falanga V, Ayello EA, Dowsett C, Harding K, et al. Wound bed preparation: a systematic approach to wound management. *Wound Repair Regen* 2003;**11**(Suppl 1):S1–28.
- 414 Leaper DJ, Schultz G, Carville K, Fletcher J, Swanson T, Drake R. Extending the TIME concept: what have we learned in the past 10 years? *Int Wound J* 2012;**9**(Suppl 2):1–19.
- 415 World Union of Wound Healing Societies. *Principles of best practice: Minimising pain at wound dressing-related procedures. A consensus document*. London, UK: MEP Ltd; 2004. Available at: <https://www.woundsinternational.com/resources/details/minimising-pain-wound-dressing-related-procedures-wuwhs-consensus-document>.
- 416 Leren L, Johansen E, Eide H, Falk RS, Juvet LK, Ljosa TM. Pain in persons with chronic venous leg ulcers: a systematic review and meta-analysis. *Int Wound J* 2020;**17**:466–84.
- 417 Briggs M, Nelson EA, Martyn-St James M. Topical agents or dressings for pain in venous leg ulcers. *Cochrane Database Syst Rev* 2012;**11**:CD001177.
- 418 O'Meara S, Al-Kurdi D, Ologun Y, Ovington LG, Martyn-St James M, Richardson R. Antibiotics and antiseptics for venous leg ulcers. *Cochrane Database Syst Rev* 2014;**1**:CD003557.
- 419 Norman G, Westby MJ, Rithalia AD, Stubbs N, Soares MO, Dumville JC. Dressings and topical agents for treating venous leg ulcers. *Cochrane Database Syst Rev* 2018;**6**:CD012583.
- 420 Zhao M, Zhang D, Tan L, Huang H. Silver dressings for the healing of venous leg ulcer: a meta-analysis and systematic review. *Medicine (Baltimore)* 2020;**99**:e22164.
- 421 Jockenhofer F, Gollnick H, Herberger K, Isbary G, Renner R, Stucker M, et al. Aetiology, comorbidities and cofactors of chronic leg ulcers: retrospective evaluation of 1 000 patients from 10 specialised dermatological wound care centers in Germany. *Int Wound J* 2016;**13**:821–8.
- 422 Weller CD, Team V, Ivory JD, Crawford K, Gethin G. ABPI reporting and compression recommendations in global clinical practice guidelines on venous leg ulcer management: a scoping review. *Int Wound J* 2019;**16**:406–19.
- 423 Evans R, Kuhnke JL, Burrows C, Kayssi A, Labreque C, O'Sullivan-Drombolis D, et al. *Best practice recommendations for the prevention and management of venous leg ulcers*. 2019. Available at: [www.woundscanada.ca/docman/public/health-care-](http://www.woundscanada.ca/docman/public/health-care-)

- professional/bpr-workshop/1521-wc-bpr-prevention-andmanagement-of-venous-leg-ulcers-1874e-final/file.
- 424 O'Brien M. Exploring methods of wound debridement. In: White R, editor. *Trends in Wound Care*. London: Quay books, MA Healthcare; 2003. p. 95–107.
  - 425 Rodeheaver GT, Ratliff CR. Wound cleansing, wound irrigation and wound disinfection. In: Krasner DJ, Rodeheaver GT, Sibbald RG, editors. *Chronic Wound Care : A Clinical Source Book For Healthcare Professionals*. Malvern, Pa, USA: HMP Communications; 2007.
  - 426 Gethin G, Cowman S, Kolbach DN. Debridement for venous leg ulcers. *Cochrane Database Syst Rev* 2015;9:CD008599.
  - 427 Westby MJ, Norman G, Dumville JC, Stubbs N, Cullum N. Protease-modulating matrix treatments for healing venous leg ulcers. *Cochrane Database Syst Rev* 2016;12:CD011918.
  - 428 Kranke P, Bennett MH, Martyn-St James M, Schnabel A, Debus SE, Weibel S. Hyperbaric oxygen therapy for chronic wounds. *Cochrane Database Syst Rev* 2015;6:CD004123.
  - 429 Cullum N, Liu Z. Therapeutic ultrasound for venous leg ulcers. *Cochrane Database Syst Rev* 2017;5:CD001180.
  - 430 Aziz Z, Cullum N. Electromagnetic therapy for treating venous leg ulcers. *Cochrane Database Syst Rev* 2015;7:CD002933.
  - 431 Dumville JC, Land L, Evans D, Peinemann F. Negative pressure wound therapy for treating leg ulcers. *Cochrane Database Syst Rev* 2015;7:CD011354.
  - 432 O'Meara S, Cullum N, Nelson EA, Dumville JC. Compression for venous leg ulcers. *Cochrane Database Syst Rev* 2012;11:CD000265.
  - 433 Rabe E, Partsch H, Hafner J, Lattimer C, Mosti G, Neumann M, et al. Indications for medical compression stockings in venous and lymphatic disorders: an evidence-based consensus statement. *Phlebology* 2018;33:163–84.
  - 434 Partsch H. The static stiffness index: a simple method to assess the elastic property of compression material in vivo. *Dermatol Surg* 2005;31:625–30.
  - 435 Mosti G, Mattaliano V, Partsch H. Influence of different materials in multicomponent bandages on pressure and stiffness of the final bandage. *Dermatol Surg* 2008;34:631–9.
  - 436 Protz K, Heyer K, Dorler M, Stucker M, Hampel-Kalthoff C, Augustin M. Compression therapy: scientific background and practical applications. *J Dtsch Dermatol Ges* 2014;12:794–801.
  - 437 Mosti G, Mattaliano V, Partsch H. Inelastic compression increases venous ejection fraction more than elastic bandages in patients with superficial venous reflux. *Phlebology* 2008;23:287–94.
  - 438 Milic DJ, Zivic SS, Bogdanovic DC, Jovanovic MM, Jankovic RJ, Milosevic ZD, et al. The influence of different sub-bandage pressure values on venous leg ulcers healing when treated with compression therapy. *J Vasc Surg* 2010;51:655–61.
  - 439 Dolibog P, Franek A, Taradaj J, Dolibog P, Blaszczyk E, Polak A, et al. A comparative clinical study on five types of compression therapy in patients with venous leg ulcers. *Int J Med Sci* 2014;11:34–43.
  - 440 Ashby RL, Gabe R, Ali S, Adderley U, Bland JM, Cullum NA, et al. Clinical and cost-effectiveness of compression hosiery versus compression bandages in treatment of venous leg ulcers (Venous leg Ulcer Study IV, VenUS IV): a randomised controlled trial. *Lancet* 2014;383:871–9.
  - 441 Blecken SR, Villavicencio JL, Kao TC. Comparison of elastic versus nonelastic compression in bilateral venous ulcers: a randomized trial. *J Vasc Surg* 2005;42:1150–5.
  - 442 Mosti G, Mancini S, Bruni S, Serantoni S, Gazzabini L, Bucalossi M, et al. Adjustable compression wrap devices are cheaper and more effective than inelastic bandages for venous leg ulcer healing. A multicentric Italian randomized clinical experience. *Phlebology* 2020;35:124–33.
  - 443 Alvarez OM, Markowitz L, Parker R, Wendelken ME. Faster healing and a lower rate of recurrence of venous ulcers treated with intermittent pneumatic compression: results of a randomized controlled trial. *Eplasty* 2020;20:e6.
  - 444 Humphreys ML, Stewart AH, Gohel MS, Taylor M, Whyman MR, Poskitt KR. Management of mixed arterial and venous leg ulcers. *Br J Surg* 2007;94:1104–7.
  - 445 Korber A, Klode J, Al-Benna S, Wax C, Schadendorf D, Steintraesser L, et al. Etiology of chronic leg ulcers in 31,619 patients in Germany analyzed by an expert survey. *J Dtsch Dermatol Ges* 2011;9:116–21.
  - 446 Mosti G, Cavezzi A, Massimetti G, Partsch H. Recalcitrant venous leg ulcers may heal by outpatient treatment of venous disease even in the presence of concomitant arterial occlusive disease. *Eur J Vasc Endovasc Surg* 2016;52:385–91.
  - 447 Stansal A, Tella E, Yannoutsos A, Keita I, Attal R, Gautier V, et al. Supervised short-stretch compression therapy in mixed leg ulcers. *J Med Vasc* 2018;43:225–30.
  - 448 Milic DJ, Zivic SS, Bogdanovic DC, Golubovic MD, Lazarevic MV, Lazarevic KK. A randomized trial of class 2 and class 3 elastic compression in the prevention of recurrence of venous ulceration. *J Vasc Surg Venous Lymphat Disord* 2018;6:717–23.
  - 449 Clarke-Moloney M, Keane N, O'Connor V, Ryan MA, Meagher H, Grace PA, et al. Randomised controlled trial comparing European standard class 1 to class 2 compression stockings for ulcer recurrence and patient compliance. *Int Wound J* 2014;11:404–8.
  - 450 Jünger M, Wollina U, Kohnen R, Rabe E. Efficacy and tolerability of an ulcer compression stocking for therapy of chronic venous ulcer compared with a below-knee compression bandage: results from a prospective, randomized, multicentre trial. *Curr Med Res Opin* 2004;20:1613–23.
  - 451 Gohel MS, Heatley F, Liu X, Bradbury A, Bulbulia R, Cullum N, et al. A randomized trial of early endovenous ablation in venous ulceration. *N Engl J Med* 2018;378:2105–14.
  - 452 Gohel MS, Barwell JR, Taylor M, Chant T, Foy C, Earnshaw JJ, et al. Long term results of compression therapy alone versus compression plus surgery in chronic venous ulceration (ESCHAR): randomised controlled trial. *BMJ* 2007;335:83.
  - 453 Gohel MS, Mora MJ, Szigeti M, Epstein DM, Heatley F, Bradbury A, et al. Long-term clinical and cost-effectiveness of early endovenous ablation in venous ulceration: a randomized clinical trial. *JAMA Surg* 2020;155:1113–21.
  - 454 van Gent WB, Catarinella FS, Lam YL, Nieman FH, Toonder IM, van der Ham AC, et al. Conservative versus surgical treatment of venous leg ulcers: 10-year follow up of a randomized, multicenter trial. *Phlebology* 2015;30(1 Suppl):35–41.
  - 455 Davies AH, Hawdon AJ, Greenhalgh RM, Thompson S. on behalf of the USABLE trial participants. Failure of a trial evaluating the effect of venous surgery on healing and recurrence rates in venous ulcers? The USABLE trial: rationale, design and methodology, and reasons for failure. *Phlebology* 2004;19:137–42.
  - 456 Bush RG. New technique to heal venous ulcers: terminal interruption of the reflux source (TIRS). *Perspect Vasc Surg Endovasc Ther* 2010;22:194–9.
  - 457 Bush R, Bush P. Percutaneous foam sclerotherapy for venous leg ulcers. *J Wound Care* 2013;22(10 Suppl):S20–2.
  - 458 Kamhaway AH, Elbarbary AH, Elhenidy MA, Elwagih AMM. Periulcer foam sclerotherapy injection in chronic venous leg ulcers using near-infrared laser for vein visualization. *Int J Low Extrem Wounds* 2020;19:63–9.
  - 459 Lloret P, Redondo P, Cabrera J, Sierra A. Treatment of venous leg ulcers with ultrasound-guided foam sclerotherapy: Healing, long-term recurrence and quality of life evaluation. *Wound Repair Regen* 2015;23:369–78.
  - 460 Rabinovich A, Kahn SR. The postthrombotic syndrome: current evidence and future challenges. *J Thromb Haemost* 2017;15:230–41.
  - 461 Coleridge-Smith P, Lok C, Ramelet AA. Venous leg ulcer: a meta-analysis of adjunctive therapy with micronized purified flavonoid fraction. *Eur J Vasc Endovasc Surg* 2005;30:198–208.
  - 462 Scallon C, Bell-Syer SE, Aziz Z. Flavonoids for treating venous leg ulcers. *Cochrane Database Syst Rev* 2013;5:CD006477.
  - 463 Wu B, Lu J, Yang M, Xu T. Sulodexide for treating venous leg ulcers. *Cochrane Database Syst Rev* 2016;6:CD010694.
  - 464 Jull AB, Arroll B, Parag V, Waters J. Pentoxifylline for treating venous leg ulcers. *Cochrane Database Syst Rev* 2012;12:CD001733.



- 465 Meissner MH, Khilnani NM, Labropoulos N, Gasparis AP, Gibson K, Greiner M, et al. The Symptoms-Varices-Pathophysiology classification of pelvic venous disorders: a report of the American Vein & Lymphatic Society International Working Group on Pelvic Venous Disorders. *J Vasc Surg Venous Lymphat Disord* 2021;9:568–84.
- 466 Ananthan K, Onida S, Davies AH. Nutcracker syndrome: an update on current diagnostic criteria and management guidelines. *Eur J Vasc Endovasc Surg* 2017;53:886–94.
- 467 Khilnani NM, Meissner MH, Learman LA, Gibson KD, Daniels JP, Winokur RS, et al. Research priorities in pelvic venous disorders in women: recommendations from a multidisciplinary research consensus panel. *J Vasc Interv Radiol* 2019;30:781–9.
- 468 Latthe P, Latthe M, Say L, Gulmezoglu M, Khan KS. WHO systematic review of prevalence of chronic pelvic pain: a neglected reproductive health morbidity. *BMC Public Health* 2006;6:177.
- 469 As-Sanie S. *Chronic pelvic pain in nonpregnant adult females: Causes*. UpToDate; 2020. Available at: [https://www.uptodate.com/contents/chronic-pelvic-pain-in-nonpregnant-adult-females-causes?search=chronic-pelvic-pain-in-nonpregnant-adult-females-5198&source=search\\_result&selectedTitle=1~150&usage\\_type=default&display\\_rank=1](https://www.uptodate.com/contents/chronic-pelvic-pain-in-nonpregnant-adult-females-causes?search=chronic-pelvic-pain-in-nonpregnant-adult-females-5198&source=search_result&selectedTitle=1~150&usage_type=default&display_rank=1).
- 470 Labropoulos N, Tionsong J, Pryor L, Tassiopoulos AK, Kang SS, Mansour MA, et al. Nonsaphenous superficial vein reflux. *J Vasc Surg* 2001;34:872–7.
- 471 Gavrillov SG. Vulvar varicosities: diagnosis, treatment, and prevention. *Int J Womens Health* 2017;9:463–75.
- 472 Steenbeek MP, van der Vleuten CJM, Schultze Kool LJ, Nieboer TE. Noninvasive diagnostic tools for pelvic congestion syndrome: a systematic review. *Acta Obstet Gynecol Scand* 2018;97:776–86.
- 473 Park SJ, Lim JW, Ko YT, Lee DH, Yoon Y, Oh JH, et al. Diagnosis of pelvic congestion syndrome using transabdominal and transvaginal sonography. *AJR Am J Roentgenol* 2004;182:683–8.
- 474 Antignani PL, Lazarashvili Z, Monedero JL, Ezpeleta SZ, Whiteley MS, Khilnani NM, et al. Diagnosis and treatment of pelvic congestion syndrome: UIP consensus document. *Int Angiol* 2019;38:265–83.
- 475 Brown CL, Rizer M, Alexander R, Sharpe EE 3rd, Rochon PJ. Pelvic congestion syndrome: systematic review of treatment success. *Semin Intervent Radiol* 2018;35:35–40.
- 476 Champaneria R, Shah L, Moss J, Gupta JK, Birch J, Middleton LJ, et al. The relationship between pelvic vein incompetence and chronic pelvic pain in women: systematic reviews of diagnosis and treatment effectiveness. *Health Technol Assess* 2016;20:1–108.
- 477 Delfrate R, Bricchi M, Franceschi C. Minimally-invasive procedure for pelvic leak points in women. *Veins Lymphatics* 2019;8:7789.
- 478 Creton D, Hennequin L, Kohler F, Allaert FA. Embolisation of symptomatic pelvic veins in women presenting with non-saphenous varicose veins of pelvic origin - three-year follow-up. *Eur J Vasc Endovasc Surg* 2007;34:112–7.
- 479 Hartung O. Embolization is essential in the treatment of leg varicosities due to pelvic venous insufficiency. *Phlebology* 2015;30(1 Suppl):81–5.
- 480 Castenmiller PH, de Leur K, de Jong TE, van der Laan L. Clinical results after coil embolization of the ovarian vein in patients with primary and recurrent lower-limb varices with respect to vulval varices. *Phlebology* 2013;28:234–8.
- 481 Greiner M, Gilling-Smith GL. Leg varices originating from the pelvis: diagnosis and treatment. *Vascular* 2007;15:70–8.
- 482 Ratnam LA, Marsh P, Holdstock JM, Harrison CS, Hussain FF, Whiteley MS, et al. Pelvic vein embolisation in the management of varicose veins. *Cardiovasc Intervent Radiol* 2008;31:1159–64.
- 483 Hamahata A, Yamaki T, Osada A, Fujisawa D, Sakurai H. Foam sclerotherapy for spouting haemorrhage in patients with varicose veins. *Eur J Vasc Endovasc Surg* 2011;41:856–8.
- 484 Davies HO, Popplewell M, Singhal R, Smith N, Bradbury AW. Obesity and lower limb venous disease - the epidemic of phlebesity. *Phlebology* 2017;32:227–33.
- 485 Meulendijks AM, Franssen WMA, Schoonhoven L, Neumann HAM. A scoping review on chronic venous disease and the development of a venous leg ulcer: the role of obesity and mobility. *J Tissue Viability* 2020;29:190–6.
- 486 Parkyn WR, Chan CY, Van Rij AM. Skin problems in the lower legs of morbidly obese patients and possible role of bariatric surgery. *J Obes Weight Loss Ther* 2014;4:230.
- 487 van Rij AM, De Alwis CS, Jiang P, Christie RA, Hill GB, Dutton SJ, et al. Obesity and impaired venous function. *Eur J Vasc Endovasc Surg* 2008;35:739–44.
- 488 Willenberg T, Clemens R, Haegeli LM, Amann-Vesti B, Baumgartner I, Husmann M. The influence of abdominal pressure on lower extremity venous pressure and hemodynamics: a human in-vivo model simulating the effect of abdominal obesity. *Eur J Vasc Endovasc Surg* 2011;41:849–55.
- 489 Deol ZK, Lakhanpal S, Franzon G, Pappas PJ. Effect of obesity on chronic venous insufficiency treatment outcomes. *J Vasc Surg Venous Lymphat Disord* 2020;8:617–28.
- 490 Shaalan W, El Emam A, Lotfy H, Naga A. Clinical and hemodynamic outcome of morbidly obese patients with severe chronic venous insufficiency with and without bariatric surgery: A comparative study. *J Vasc Surg Venous Lymphat Disord* 2021;9:1248–56.
- 491 Ismail I, Normahani P, Standfield NJ, Jaffer U. A systematic review and meta-analysis of the risk for development of varicose veins in women with a history of pregnancy. *J Vasc Surg Venous Lymphat Disord* 2016;4:518–24.
- 492 Thaler E, Huch R, Huch A, Zimmermann R. Compression stockings prophylaxis of emergent varicose veins in pregnancy: a prospective randomised controlled study. *Swiss Med Wkly* 2001;131:659–62.
- 493 Saliba OA Jr, Rollo HA, Saliba O, Sobreira ML. Graduated compression stockings effects on chronic venous disease signs and symptoms during pregnancy. *Phlebology* 2020;35:46–55.
- 494 Adamczyk A, Krug M, Schnabl S, Hafner M. Compression therapy during pregnancy: boon or bane? *Phlebologie* 2013;42:301–7.
- 495 National Institute for Health and Clinical Excellence. *Clinical guideline [CG168]. Varicose veins: diagnosis and management*. National Institute for Health and Clinical Excellence; 2013 [Accessed 10 June 2021]; Available at: <https://www.nice.org.uk/guidance/cg168/chapter/1-Recommendations#management-during-pregnancy>.
- 496 Westin GG, Cayne NS, Lee V, Ekstroem J, Yau PO, Sadek M, et al. Radiofrequency and laser vein ablation for patients receiving warfarin anticoagulation is safe, effective, and durable. *J Vasc Surg Venous Lymphat Disord* 2020;8:610–6.
- 497 Pappas PJ, Lakhanpal S, Nguyen KQ, Vanjara R. The Center for Vein Restoration Study on presenting symptoms, treatment modalities, and outcomes in Medicare-eligible patients with chronic venous disorders. *J Vasc Surg Venous Lymphat Disord* 2018;6:13–24.
- 498 Hamel-Desnos C, Desnos P, Allaert FA, Kern P. "Thermal group" for the French Society of Phlebology and the Swiss Society of Phlebology. Thermal ablation of saphenous veins is feasible and safe in patients older than 75 years: A prospective study (EVTA study). *Phlebology* 2015;30:525–32.
- 499 Vosicka K, Qureshi MI, Shapiro SE, Lim CS, Davies AH. Post thrombotic syndrome following deep vein thrombosis in paediatric patients. *Phlebology* 2018;33:185–94.
- 500 Patel PA, Barnacle AM, Stuart S, Amaral JG, John PR. Endovenous laser ablation therapy in children: applications and outcomes. *Pediatr Radiol* 2017;47:1353–63.
- 501 Brouwers MC, Kho ME, Browman GP, Burgers JS, Cluzeau F, Feder G, et al. Development of the AGREE II, part 2: assessment of validity of items and tools to support application. *CMAJ* 2010;182:E472–8.
- 502 Salim S, Tan M, Geoghegan L, Belramman A, Onida S, Davies AH. A systematic review assessing the quality of clinical practice guidelines in chronic venous disease. *J Vasc Surg Venous Lymphat Disord* 2021;9:787–91.